

AP019

**GUPTA HOSPITALS**  
**SRI SRINIVASA SCAN CENTRE**  
S.V. Deluxe Road, Piler. Phone: 240537,244433

Patient name	Mrs. MOUNIKA	Age/Sex	26 Years / Female
Patient ID	VS8804767-21-03-21-7	Visit No	1
Referred by	Dr. MAMATHA LAKSHMI	Visit Date	21/03/2021
LMPDate	Unknown	C-EDD	30/07/2021

**OB - 2/3 Trimester Scan Report**

Real time B-mode ultrasonography of gravid uterus done.

Route: Transabdominal  
Single intrauterine gestation

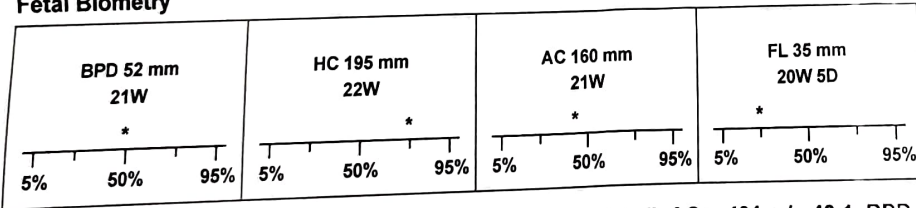
**Fetus**

**Survey**

Presentation - Breech  
Placenta - Anterior uppersegment  
Liquor - Adequate  
Single pocket = 5.5  
Umbilical cord - Two arteries and one vein  
Fetal activity present  
Cardiac activity present  
Fetal heart rate - 142 bpm

DOB → 27/05/1994  
WT → 68 kg.

**Fetal Biometry**



Estimated fetal weight according to BPD, AC :- 427 + / - 42.7 FL, AC :- 401 + / - 40.1 BPD, HC, AC, FL :- 404 + / - 40.4 gms.

**Fetal Anatomy**

**Head**

Midline falx seen.  
Both lateral ventricles appeared normal.  
Posterior fossa appeared normal.  
No identifiable intracranial lesion seen.

**Neck**

Fetal neck appeared normal.

**Spine**

Entire spine visualised in longitudinal and transverse axis.  
Vertebrae and spinal canal appeared normal.

**Face**

Fetal face seen in the coronal and profile views.  
Both orbits, nose and mouth appeared normal.

**Thorax**

Both lungs seen.  
No evidence of pleural or pericardial effusion.  
No evidence of SOL in the thorax.

21026548