

BORKAR MULTISPECIALITY HOSPITAL, HUDKESHWAR ROAD, NAGPUR

Obstetrics Ultrasound Report

Name: DIPALI PIYUSH ROKADE

Age: 29

Sex: Female

Date: 2022-06-11

ID: 241

LMP 2022-03-16

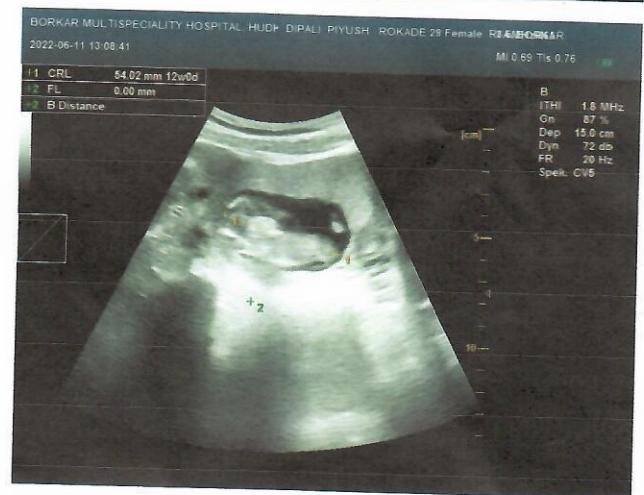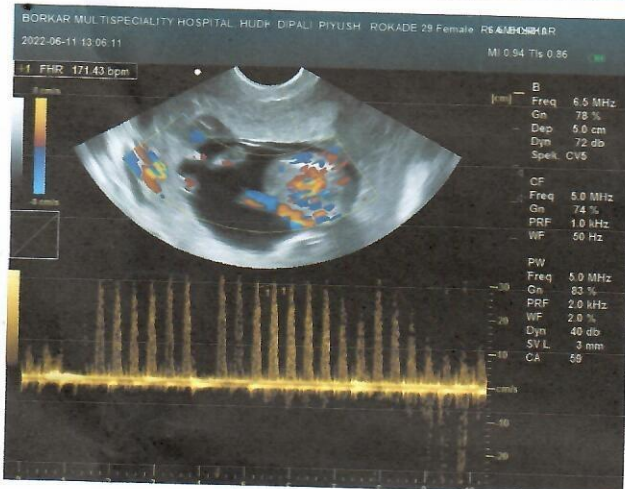
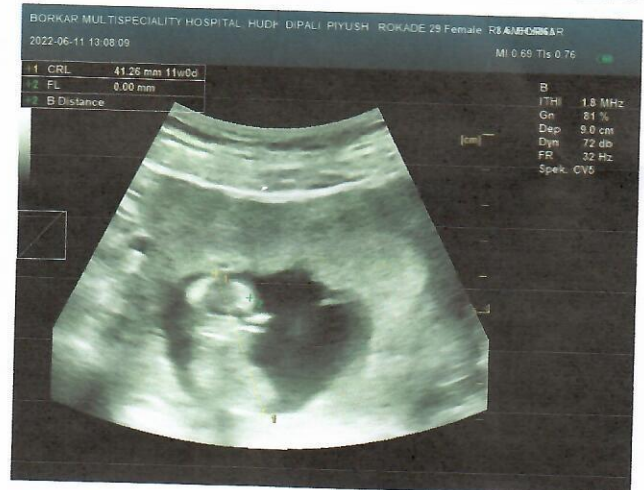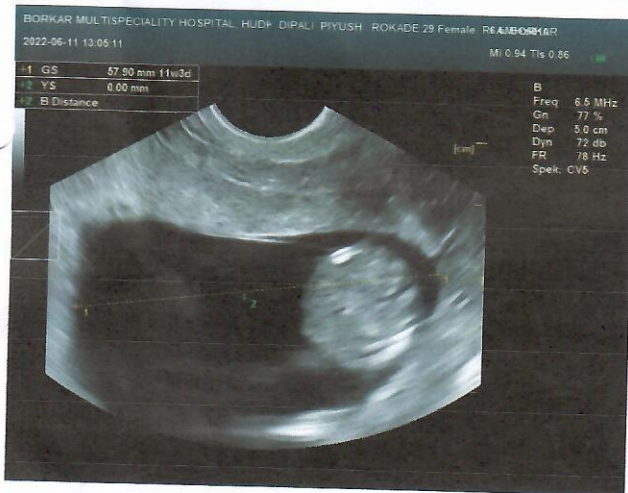GA (LMP) 12w3d

EDD (LMP) 2022-12-21

GA (AUA) 12w2d

EDD (AUA) 2022-12-22

Ultrasound Image



OB B Mode

OB Early

	Value	GA	EDD
GS	57.90 mm	11w3d	2022-12-28
BPD	20.82 mm	12w6d	2022-12-18
CRL	54.02 mm	12w0d	2022-12-23
FL	8.22 mm		
FHR	171.43 bpm		

LMP - 16/3/22

weight - 44.6 kg

Height - 150 cm

DOB - 09/07/1992

23372563

Sonography Report:-Done on Sonotech Max Series Colour doppler

- * Real Time Scan Shows:- Single live Intrauterine Gestational sac with changing lie & Presentation.
 - * Fetal pole well appreciated.
 - * Fetal cardiac activity well appreciated.
 - * Fetal Somatic movement seen..
- Internal OS closed.

Note:- I have neither detected the sex of the fetus nor disclosed the same to any body in any manner
Advice NT scan by Radiologist WITHIN 1 week

Conclusion

EP: SINGLE LIVE INTRAUTERINE GESTATIONAL SAC OF 12 WEEKS 2 DAYWS

Referral Doctor: _____

Reported by: DR. GAYATRI A. BORKAR