

Dr. Rakesh R. Wadhwa
Ex. Consultant Radiologist & Sonologist
I Sonkul Diagnostic Centre, Nagpur.
I Seven Star Hospital, Nagpur.
I Shree Bhavani Hospital, Pardi, Nagpur.

Plot No. -11 Om Shiv Sai Society Besa, Nagpur - 440037
Ph. : 8485883167

Shop No. F22, Jayanti Mansion - 3, Reliance Fresh Building
Manish Nagar, Nagpur Ph. No. : 8485883167, 0712-35676

Patient Name: ASMITA GEDAM	Date: 27/07/2022
Patient Id: 634	Age/Sex: 31 Years / F
Ref Phy: DR. JYOTI BORKAR MADAM	Address :

OBSTETRIC EARLY DETAILED SCAN

Height : 146 cm	BP		MAP
Weight : 61.3 Kg	Systolic	128	100.00
BMI : 28.76	Diastolic	86	mmHG

Date of Birth -
25/05/1990

Non - Diabetic

23378256

LMP:04-05-2022		▼GA(LMP):12w0d		▲AUA:12w2d		EDD by LMP:08-02-2023											
0		5		10		15		20		25		30		35		40	
Dating		LMP				GA				EDD							
						Weeks		Days									
By LMP		LMP: 04/05/2022				12		0		08/02/2023							
By USG		02/05/2022				12		2		06/02/2023							
AGREED DATING IS (BASED ON LMP)																	

AGREED DATING IS (BASED ON LMP)

There is a single gestation sac in uterus with a single fetus within it.

The fetal cardiac activities are well seen.




Chorion frondosum/Placenta is **anterior** in nature, grade 0.

AMNIOTIC FLUID : Normal

Internal os is closed and length of cervix is normal. **3.27 cm.**

Internal os diameter measures **1.5 mm.**

The embryonal growth parameters are as follow :

	mm	Weeks	Days
Crown Rump Length :	57.6	12	2
Heart Rate :	166 Beats Per Minute.		
The Embryo attains 40 weeks of age on :	06/02/2023		
Nuchal Translucency	1.5 mm 42% 		
Nasal Bone	2.4 mm 29.8% 		
Hands, Limbs, Nasal Triangle Integrity, Bladder, Stomach & Umbilical Arteries	Seen		
Ductus Venosus Waveform	Normal waveform Pattern 		



P. T. O. =>

Dr. Rakesh R. Wadhwa

M.B.B.S., M.D., B.C.F.R.G., D.M.R.E., A.C.F.R.G.
D.M.F.M.O.C.(UKSH) FMF (UK), IOTA (Europe)
Consultant Radiologist & Sonologist



WADHAI

DIAGNOSTIC CENTRE

Dr. Rakesh R. Wadhai

Ex. Consultant Radiologist & Sonologist

■ Sonkul Diagnostic Centre, Nagpur.

■ Seven Star Hospital, Nagpur.

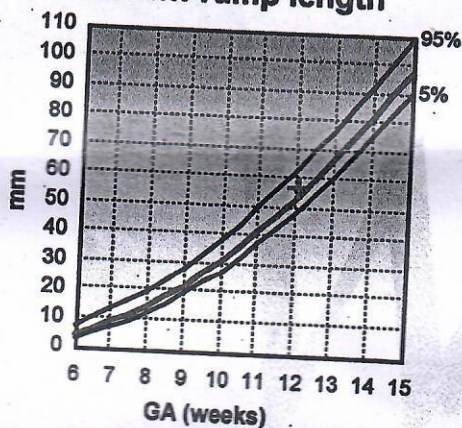
■ Shree Bhavani Hospital, Pardi, Nagpur.

Plot No. -11 Om Shiv Sai Society Besa, Nagpur - 440037
Ph. : 8485883167

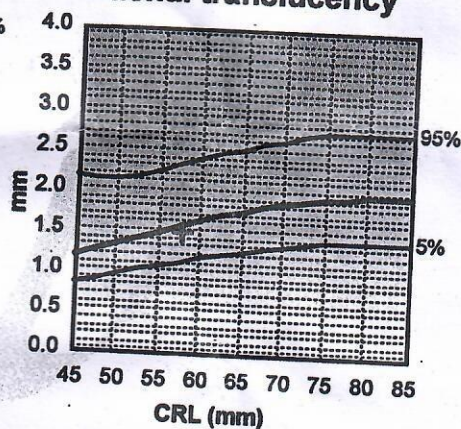
Shop No. F22, Jayanti Mansion - 3, Reliance Fresh Building
Manish Nagar, Nagpur Ph. No. : 8485883167, 0712-356762

Vessels	S/D	RI	PI	PI Percentile	Remarks
Right Uterine Artery	33.00	0.81	1.89	65.9%	PSV=29.08 Normal waveform Pattern
Left Uterine Artery	6.67	0.85	2.39	91.6%	
Ductus venosus	2.64	0.62	0.84		

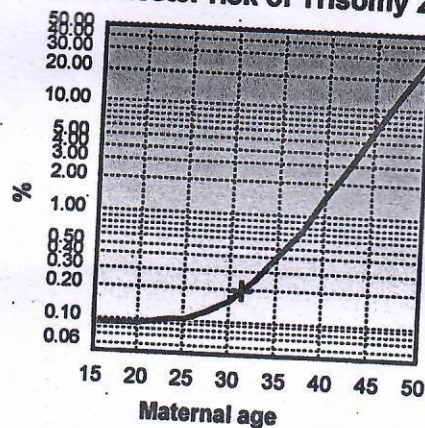
Crown-rump length



Nuchal translucency



1st trimester risk of Trisomy 21



P. T. O. ⇒



Dr. Rakesh R. Wadhai

M.B.B.S., M.D., B.C.F.R.G., D.M.R.E., A.C.F.R.G.,
D.M.F.M.O.C.(UKSH) FMF (UK), IOTA (Europe)

Consultant Radiologist & Sonologist

Reg. No. : 2012/10/2921



WADHAI

DIAGNOSTIC CENTRE

Dr. Rakesh R. Wadhai

Ex. Consultant Radiologist & Sonologist

■ Sonkul Diagnostic Centre, Nagpur.

■ Seven Star Hospital, Nagpur.

■ Shree Bhavani Hospital, Pardi, Nagpur.

Plot No. -11 Om Shiv Sai Society Besa, Nagpur - 440037

Ph. : 8485883167

Shop No. F22, Jayanti Mansion - 3, Reliance Fresh Building

Manish Nagar, Nagpur Ph. No. : 8485883167, 0712-356762

First trimester: Pre Ultrasound Maternal age risk for Trisomy21 is 1 in 543

Fetus	Risk estimate – NT
A	1 in 1939

CONCLUSION:

- **SINGLE LIVE INTRAUTERINE FETUS OF 12 WEEKS 2 DAYS IS PRESENT.**
- **PLEASE CORRELATE WITH DUAL/TRIPLE MARKER TEST.**

Please note that all anomalies can not be detected all the times due to various technical and circumstantial reasons like gestation period, fetal position, quantity of liquor etc. The present study can not completely confirm presence or absence of any or all the congenital anomalies in the fetus which may be detected on post natal period. Growth parameters mentioned herein are based on International Data and may vary from Indian standards. Date of delivery (at 40 weeks) is calculated as per the present sonographic growth of fetus and may not correspond with period of gestation by L.M.P. or by actual date of delivery. As with any other diagnostic modality, the present study should be correlated with clinical features for proper management. Except in cases of Fetal Demise or Missed Abortion, sonography at 20-22 weeks should always be advised for better fetal evaluation and also for base line study for future reference.

I, DR. RAKESH WADHAI declare that while conducting sonography on ASMITA GEDAM (name of pregnant woman), I have neither detected nor disclosed the sex of the fetus to anybody in any manner.

REQUEST FOR OBSTETRIC USG ON YOUR LETTER HEAD IS MANDATORY (PCPNDT ACT). PLEASE COMPLY.



Dr. Rakesh R. Wadhai

M.B.B.S., M.D., B.C.F.R.G., D.M.R.E., A.C.F.R.G.,

D.M.F.M.O.C.(UKSH) FMF (UK), IOTA (Europe)

Consultant Radiologist & Sonologist

Reg. No. : 2012/10/2921