



# త్రివేణి హాస్పిటల్ TRIVENI HOSPITAL



గ్రీన్లాండ్ హాస్పిటల్ గేటు ఎదురుగా, డాక్టర్స్ కాలనీ, నల్లగొండ.

**Dr. G. TRIVENI**

M.B.B.S., M.S.(Obgy.)

Obstetrician & Gynaecologist

Infertility Specialist

Regd. No. 52814

Barcod: 23286948

Cell: 7569550452, 6302900950

**డా॥ జి. త్రివేణి**

M.B.B.S., M.S.(Obgy.)

ప్రసూతి మరియు స్త్రీల వ్యాధి నిపుణులు

Regd. No. 52814

Pt's Name: Mr. S. Shireen, w/o. Venkatesh, Nagamam Age: 22 Sex: F

**GPLAD**

Wt: 41 kg's

Temp: 98

PR: 82 mb

BP: 110/70 mm/Hg

Heart: S1S2

Lungs: NDA

LMP: 23.05.22

DOB: 10.08.1999

Date: 07/08/22

Valid Upto: 10/09/22

LMP :

EDD :

S.EDD :

ML :

Consanguinity Yes/No.

Menstrual Periods :

Reg/Irregular

01 ECG: Normal

PO-POA

PM ut jointly

PM ut drs

Ado  
NT+DR  
TSHP/af

# First Trimester Screening Report

## Kalpana Fetal Medicine and Scan Center

Protecting the Precious...

MRS SHIRISHA

Date of birth : 10 August 1999, Examination date: 27 August 2022

Address: VALIGONDA

Hospital no.: KFC5816

Mobile phone: 9014381351

Referring doctor: TRIVENI

### Maternal / Pregnancy Characteristics:

Racial origin: South Asian (Indian, Pakistani, Bangladeshi).

Parity: 1; Deliveries at or after 37 weeks: 1.

Maternal weight: 47.0 kg; Height: 152.0 cm.

Smoking in this pregnancy: no; Diabetes Mellitus: no; Chronic hypertension: no; Systemic lupus erythematosus: no; Antiphospholipid syndrome: no; Preeclampsia in previous pregnancy: no;

Previous small baby: no; Patient's mother had preeclampsia: no.

Method of conception: Spontaneous;

Last period: 23 May 2022

EDD by dates: 27 February 2023

### First Trimester Ultrasound:

US machine: E 6. Visualisation: good.

Gestational age: 13 weeks + 5 days from dates

EDD by scan: 27 February 2023

Findings	Alive fetus
Fetal heart activity	visualised
Fetal heart rate	170 bpm
Crown-rump length (CRL)	75.0 mm
Nuchal translucency (NT)	1.3 mm
Biparietal diameter (BPD)	24.0 mm
Ductus Venosus PI	0.900
Placenta	posterior low
Amniotic fluid	normal

### Chromosomal markers:

Nasal bone: present; Tricuspid Doppler: normal.

### Fetal anatomy:

Skull/brain: appears normal; Spine: appears normal; Heart: Appears normal; Abdominal wall: appears normal; Stomach: visible; Bladder / Kidneys: visible; Hands: both visible; Feet: both visible.

Uterine artery PI:	1.20	equivalent to 0.770 MoM
Endocervical length:	35.0 mm	

### Risks / Counselling:

Patient counselled and consent given.

Operator: Lekkala Kalpana, FMF Id: 173593

Condition	Background risk	Adjusted risk
Trisomy 21	1: 1064	1: 7629
Trisomy 18	1: 2734	1: 10650
Trisomy 13	1: 8537	1: 5168
Preeclampsia before 34 weeks		1: 3380

Page 1 of 2 - printed on 27 August 2022 - MRS SHIRISHA examined on 27 August 2022.

# 8-2-39, బస్టాండ్ రోడ్, గ్రీన్లాండ్ హాస్పిటల్ టర్నింగ్, డాక్టర్స్ కాలనీ, నల్గొండ, తెలంగాణ, ఇండియా-508001

For Appointment : ☎ +91 8522 856 854 | +91 9704 234 016

Boxed: 23286948



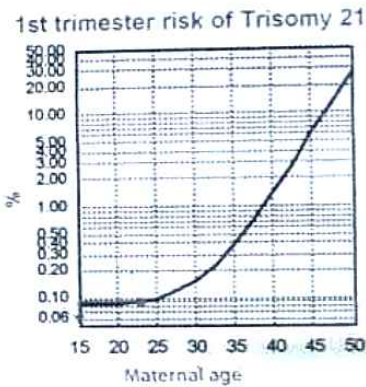
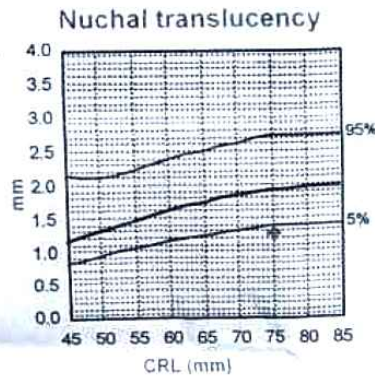
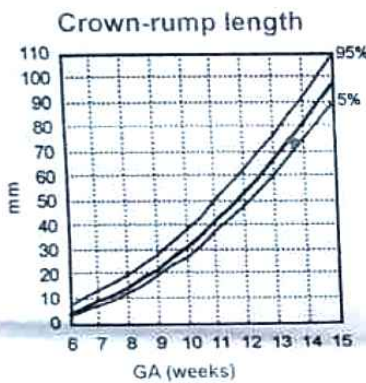
Fetal growth restriction before 37 weeks

1: 292

The background risk for aneuploidies is based on maternal age (23 years). The adjusted risk is the risk at the time of screening, calculated on the basis of the background risk and ultrasound factors (fetal nuchal translucency thickness, nasal bone, fetal heart rate).

Risks for preeclampsia and fetal growth restriction are based on maternal demographic characteristics, medical and obstetric history and uterine artery Doppler. All biophysical markers are corrected as necessary according to several maternal characteristics including racial origin, weight, height, smoking, method of conception and parity.

The estimated risk is calculated by the FMF-2012 software (version 2.81) and is based on findings from extensive research coordinated by the Fetal Medicine Foundation (UK Registered charity 1037116). The risk is only valid if the ultrasound scan was performed by a sonographer who has been accredited by the Fetal Medicine Foundation and has submitted results for regular audit (see [www.fetalmedicine.com](http://www.fetalmedicine.com)).



#### Comments

Single live intra uterine fetus corresponding to 13 weeks 5 days.

Down syndrome screen negative based on NT scan.

Suggested DOUBLE MARKER.

Suggested TIFFA SCAN at 19 to 20 weeks. ( Oct 7th 12th )

I, Dr. L. Kalpana Reddy, declared that while conducting ultrasonography / imaging scanning on Mrs. SHIRISHA, I have neither detected nor disclosed the sex of fetus to any body in any manner.

DR. L. KALPANA REDDY  
FETAL MEDICINE CONSULTANT

Barcode: 23288948