

Obstetrics Ultrasound Report

Name: APEKSHA CHOUBE

Age: 27

Sex: Female

Date: 2022-08-30

ID: 304

LMP 2022-05-25

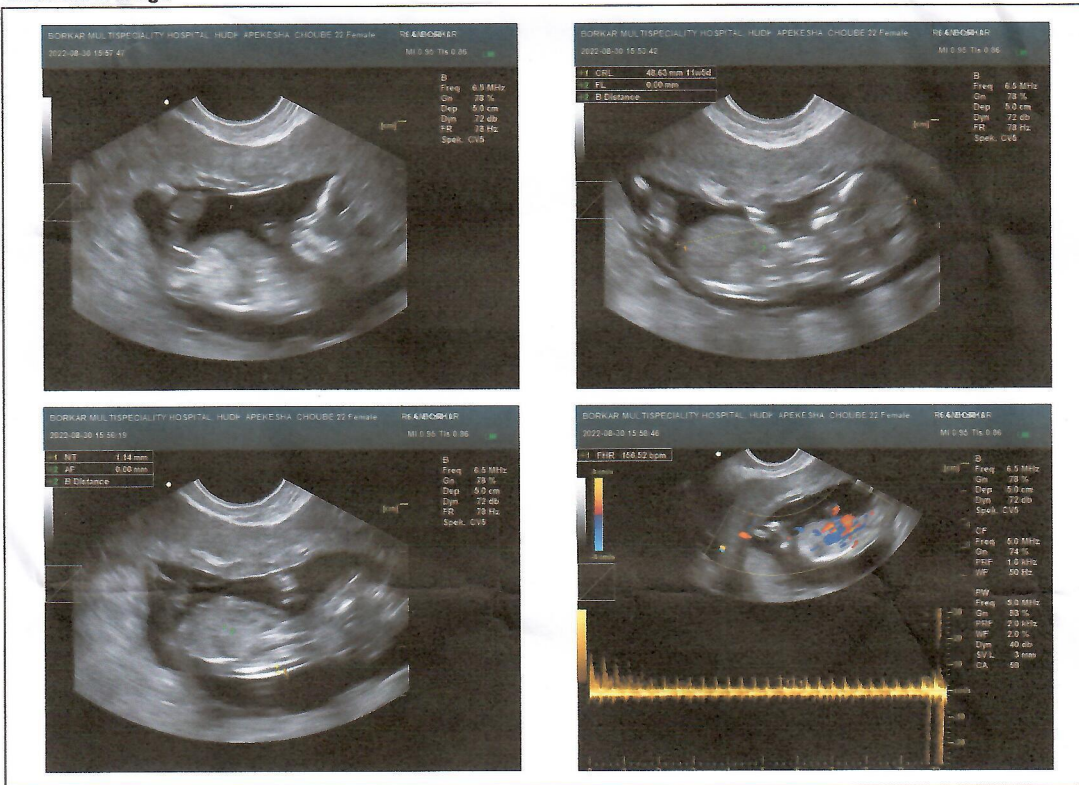
GA (LMP) 13w6d

EDD (LMP) 2023-03-01

GA (AUA) 11w5d

EDD (AUA) 2023-03-16

Ultrasound Image



OB B Mode

OB Early

	Value	GA	EDD
CRL	48.63 mm	11w5d	2023-03-16
NT	1.14 mm		
FHR	156.52 bpm		

DOB: 26/09/1995
Weight: 57.55 kg

Description

Sonography Report:-Done on Sonotech Max Series Colour doppler

- * Real Time Scan Shows:- Single live Intrauterine Gestational sac with changing lie & Presentation.
- * Fetal pole well appreciated.
- * Fetal cardiac activity well appreciated.
- * Fetal Somatic movement seen.
- * Nuchal Translucency . Normal.
- * Internal OS closed.

Note:- I have neither detected the sex of the fetus nor disclosed the same to any body in any manner
Advice Anomaly scan by Radiologist between 18-20 weeks.

Conclusion

EP: SINGLE LIVE INTRAUTERINE GESTATIONAL SAC OF 12 WEEKS WITH NORMAL NT.