



త్రివేణి హాస్పిటల్ TRIVENI HOSPITAL



గ్రీన్లాండ్ హాస్పిటల్ గేటు ఎదురుగా, డాక్టర్స్ కాలనీ, నల్లగొండ.

Dr. G. TRIVENI

M.B.B.S., M.S.(Obgy.)

Obstetrician & Gynaecologist

Infertility Specialist

Regd. No. 52814

సంప్రదించు వేళలు :
ప్రసవశాల ఈ గం. 10-00 నుండి రాత్రి గం. 7-00 వరకు
అధివారం ఈ గం. 10-00 నుండి మొ గం. 2-00 వరకు

Cell: 7569550452, 6302900950

Barcod: 23287520

డా॥ జి. త్రివేణి

M.B.B.S., M.S.(Obgy.)

ప్రసూతి మరియు స్త్రీల వ్యాధి నిపుణులు

Regd. No. 52814

Pt's Name ms. suvartha ulu sriniv. Vill. nalgonda Age 25 Sex F

GPLAD

T 3MA C Hgpoth

Date: 28/09/22

Valid Upto: 12/10/22

Wt : 44 kgs

Temp : 94.5 F

PR : 82 mb

BP : 110/40 mm/hg

Heart : S1 S2 ⊕

Lungs : NAD

C/O G weak

O/E G Fair

Abn

PR. 80b

PIA ut just perls
released

LMP : 03/07/2022

EDD :

S.EDD :

ML :

Consanguinity Yes/No.

Menstrual Periods :

Reg/Irregular

DOB: 03/05/1997

Adw

DM

12/10/2022

Hypoplasia
Klaxel Bone

R
1. T. Pam-D
1-30d

2. T. Folisafed
1-30d

3. T. Zemsu P
1-20d

4. T. Vamvav
1-30d

5. T. Pust-SR
20d
1-30d

MRS SUVARTHA

Date of birth : 03 May 1997, Examination date: 28 September 2022

Address: NALGONDA

Hospital no.: KFC6297

Mobile phone: 9963547514

Referring doctor: TRIVENI

Maternal / Pregnancy Characteristics:

Racial origin: South Asian (Indian, Pakistani, Bangladeshi).

Parity: 0.

Maternal weight: 47.0 kg; Height: 152.0 cm.

Smoking in this pregnancy: no; Diabetes Mellitus: no; Chronic hypertension: no; Systemic lupus erythematosus: no; Antiphospholipid syndrome: no; Patient's mother had preeclampsia: no.

Method of conception: Spontaneous;

Last period: 03 July 2022

EDD by dates: 09 April 2023

First Trimester Ultrasound:

US machine: E 6. Visualisation: good.

Gestational age: 12 weeks + 3 days from dates

EDD by scan: 09 April 2023

Findings	Alive fetus
Fetal heart activity	visualised
Fetal heart rate	158 bpm
Crown-rump length (CRL)	56.0 mm
Nuchal translucency (NT)	1.3 mm
Biparietal diameter (BPD)	22.0 mm
Ductus Venosus PI	1.100
Placenta	ANTERIOR
Amniotic fluid	normal

Chromosomal markers:

Nasal bone: can not examine; Tricuspid Doppler: normal.

Fetal anatomy:

Skull/brain: appears normal; Spine: appears normal; Heart: Appears normal; Abdominal wall: appears normal; Stomach: visible; Bladder / Kidneys: visible; Hands: both visible; Feet: both visible.

Uterine artery PI: 1.65 equivalent to 0.950 MoM
Endocervical length: 31.0 mm

Risks / Counselling:

Patient counselled and consent given.

Operator: Lekkala Kalpana, FMF Id: 173593

Condition	Background risk	Adjusted risk
Trisomy 21	1: 932	1: 4661
Trisomy 18	1: 2190	1: 6635
Trisomy 13	1: 6892	<1: 20000
Preeclampsia before 34 weeks		1: 510
Fetal growth restriction before 37 weeks		1: 114



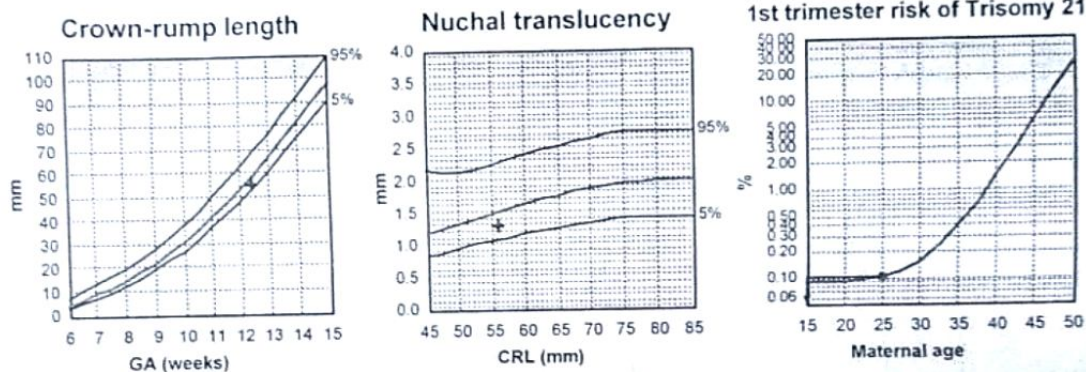
Kalpana Fetal Medicine and Scan Center

Protecting the Precious...

The background risk for aneuploidies is based on maternal age (25 years). The adjusted risk is the risk at the time of screening, calculated on the basis of the background risk and ultrasound factors (fetal nuchal translucency thickness, fetal heart rate).

Risks for preeclampsia and fetal growth restriction are based on maternal demographic characteristics, medical and obstetric history and uterine artery Doppler. All biophysical markers are corrected as necessary according to several maternal characteristics including racial origin, weight, height, smoking, method of conception and parity.

The estimated risk is calculated by the FMF-2012 software (version 2.81) and is based on findings from extensive research coordinated by the Fetal Medicine Foundation (UK Registered charity 1037116). The risk is only valid if the ultrasound scan was performed by a sonographer who has been accredited by the Fetal Medicine Foundation and has submitted results for regular audit (see www.fetalmedicine.com).



Comments

Single live intra uterine fetus corresponding to 12 weeks 3 days.

Down syndrome screen negative based on NT scan.

NASAL BONE CAN NOT EXAMINE.

Suggested **DOUBLE MARKER**.

Suggested **TIFFA SCAN** at 19 to 20 weeks. (NOV 14TH TO 16TH)

I, Dr. L. Kalpana reddy, declared that while conducting ultrasonography / imaging scanning on Mrs. SUVARTHA, I have neither detected nor disclosed the sex of fetus to any body in any manner.

DR. L. KALPANA REDDY
FETAL MEDICINE CONSULTANT

23287520