

RATHOD NURSING HOME
736-H, Nelson Square, Opp. Site Ram Mandir,
Chhaoni, Napur - 13, Ph: 0712- 2592121

Patient name	Mrs. RUMANA AHMED	Age/Sex	30 Years / Female
Patient ID	RNH2101	Visit no	2
Referred by	Dr. NAMRATA RATHOD	Visit date	06/10/2022
LMP date	08/07/2022, LMP EDD: 14/04/2023 [12W 6D]		

OB - First Trimester Scan Report

Real time B-mode ultrasonography of gravid uterus done.

Route: Transabdominal

Single intrauterine gestation

Previous visit (mm/grams)

Date	Visit	GA	CRL	BPD	HC	AC	FL Rt	FL Lt	EFW
05/09/2022	8W 3D	19.8							
Right Uterine	1.53		—●— (45%)						
Left Uterine	2.52		—●— (>99%)						

Fetus

Survey

Placenta : Anterior
Liquor : Normal
Umbilical cord : Two arteries and one vein
Fetal activity : Fetal activity present
Cardiac activity : Cardiac activity present

Biometry (mm)

CRL	75.6, 13W 4D	—●— (83%)
BPD	23.2, 13W 6D	—●— (75%)
HC	82, 13W 4D	—●— (55%)
AC	68.2, 13W 3D	—●— (73%)
FL	9.2, 12W 5D	—●— (39%)

Fetal doppler

Ductus Venosus PI	1.05	—●—
-------------------	------	-----

Cephalic index - 80 Range 75-85%

IT - 2.1 mm

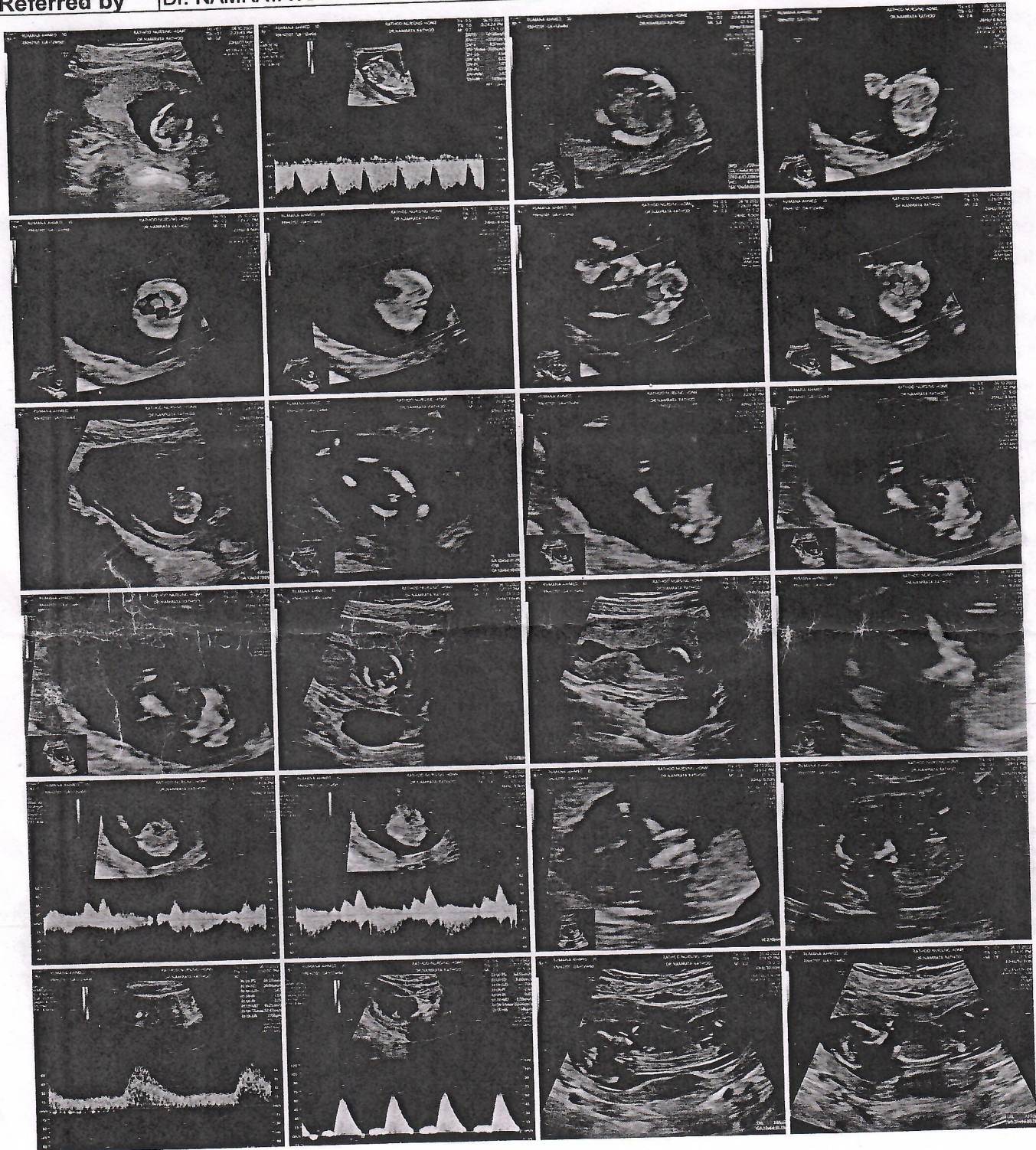
Aneuploidy Markers (mm)

Nasal Bone	Present
NT	0.8 —●— (<1%) Normal
Ductus Venosus	No "a" wave reversal

Vid ID : 23761610

RATHOD NURSING HOME

Patient name	Mrs. RUMANA AHMED	Age/Sex	30 Years / Female
Patient ID	RNH2101	Visit no	2
Referred by	Dr. NAMRATA RATHOD	Visit date	06/10/2022



Mrs. RUMANA AHMED / RNH2101 / 06/10/2022 / Visit No 2

Aneuploidy Markers (mm)

Tricuspid Regurgitation	No TR
----------------------------	-------

Fetal Anatomy

MIDLINE FALX SEEN. CHOROID PLEXUS VENTRICLE SEEN

Fetal neck appeared normal.

Spine appeared normal. No evidence of significant open neural tube defect

Fetal face seen in the coronal and profile views.

Both orbits, nose and mouth appeared normal

Both lungs seen.

No evidence of pleural or pericardial effusion.

No evidence of SOL in the thorax.

Heart appears in the mid position.

Normal cardiac situs. Four chamber view normal.

Outflow tracts appeared normal.

Abdominal situs appeared normal.

Stomach and bowel appeared normal.

Normal bowel pattern appropriate for the gestation seen.

No evidence of ascites.

Abdominal wall intact.

BILATERAL RENAL ARTERIES SEEN

Right and Left kidneys appeared normal.

Bladder appeared normal

ALL 4 EXTREMITIES SEEN

All long bones appeared normal for the period of gestation

H - 5.3

W - 69 Kg

B.D - 20 Oct. 1991

LMP: - 8 July - 2022

Impression

Intrauterine gestation corresponding to a gestational age of 12 Weeks 6 Days

Gestational age assigned as per LMP

Placenta - Anterior

Liquor - Normal

ADV DUAL MARKER TEST

ADV AOMALY SCAN AT 19 WEEKS

Disclaimer

*I declare that while conducting ultrasonography/image scanning on the patient ,
I have neither detected nor disclosed the sex of her fetus to anybody in any manner.*