

Date .. 17/4/2011 ..

NAME \_\_\_\_\_

AGE.....37

**& ADDRESS.**

Previous Labour

### Present Pregnancy

1. ....

2. M.L. 277

3. ....

4. \_\_\_\_\_

5. \_\_\_\_\_

6. \_\_\_\_\_

Date of M. Period

## General Conditions

## Heart

**Lungs.**

## Teeth

## Breasts

## Discharge

## Measurement

I.S. (1) 11912

I.C.

D. E.

Previous Illness .....

### Due Date

22 feb

DATE & DOCTOR'S SIGNATURE	URINE	B.P.	W.T.	PRESENTATION & POSITION	F.H.	NOTE
4.2 A to 89.0  12/2 (N)		123/51	61	18-20  Tender Scars (2) <del>Scars</del> Caudal - Marked		ca 18-20 C (30) Chamber C (30) Lys (30) S. O. X C
	NH2					P.T.O.

## IMPRESSI

ADVISED: F

14 - 5, 4, 11

Bet- 52

જન્મ તારીખ ૨૫ / ૮ / ૧૯૮૭

mob - 7389831677

Bp - 123 / 61

weight = 51 kg.

Height - 5.4.

DOB - 24/08/1989



Name: MRS.SHALINI CHANDEL

33/F

Date: 10/10/2022


Adv. by: DR.MRS.PADMA PANDEY.MBBS.

**TARGET SCAN OF FOETUS**  
(FOR FETAL CONGENITAL ABNORMALITIES)

- **HEAD** : Trans cerebellar diameter measures approx 20.6 mms & cisterna magna measures 4.8 mms  
Midline falx seen. Lateral ventricle measures approx 4.9 mms.  
Posterior fossa appeared normal. No identifiable intracranial lesion seen.  
Nuchal fold thickness appeared normal.
- **FACE** : Fetal face seen in the coronal and profile views. Both orbits & mouth appeared normal.  
Nasal bone measuring approx 5.3 mms in length.
- **NECK** : No cystic lesion seen around fetal neck.
- **SPINE** : Entire spine visualized in longitudinal and transverse axis.  
Vertebrae and spinal canal appeared normal.
- **THORAX** : Both lungs seen. No evidence of pleural or pericardial effusion is seen.  
No evidence of SOL in the thorax.
- **HEART** : Heart appears in the mid position. Four chambered heart seen.  
Fetal echocardiography is suggested if cardiac anomalies are suspected.  
The same is not under the preview of this scan.
- **ABDOMEN** : Shows normal fluid filled stomach. No abnormal bowel loops are seen.  
Abdominal wall is intact.
- **KUB** : Kidneys are identified. Urinary bladder is normally visualized.
- **LIMBS** : All four limbs are visualized.  
The fingers could not be commented upon due to clenched fists.
- **UMBILICAL CORD** : Has 3 vessels.

**IMPRESSION: NO GROSS CONGENITAL ABNORMALITY IS VISUALIZED.**

NOTE: Detailed fetal anatomy may not always be visible due to technical difficulties related to fetal positions, amniotic fluid volume, fetal movements and abdominal wall thickness. Therefore, all fetal anomalies may not necessarily be detected at every examination. Pathological correlation is essential to rule out chromosomal abnormalities. Fetal anomalies that may not be apparent by 20-24 weeks gestation are some forms of hydrocephalus, microcephalus, some cardiac defects, gastrointestinal obstruction, polycystic renal displasias, heterozygous achondroplasia.

  
DR.R.K.SAXENA.  
MD.

I HAVE NEITHER DETECTED NOR DISCLOSED THE SEX OF FETUS TO ANYBODY IN ANY MANNER

सक्सेना सोनोग्राफी, कलर डॉपलर, मेमोग्राफी एवं डिजिटल एक्स-रे सेंटर, रूपम सेंटर, पानी की टंकी के सामने, राइट लाइन, जबलपुर



Name: MRS. SHALINI CHANDEL

33/F

Date: 10/10/2022

Adv. by: DR. MRS. PADMA PANDEY. MBBS.

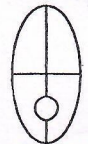
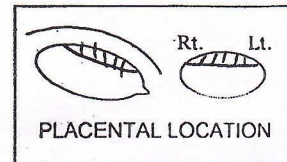
### OBSTETRICAL SONOGRAPHY

INDICATION: ROUTINE OBST. USG.

CLINICALLY: LMP- 15/05/2022

GEST. AGE BY LMP- 21.1 Wks.

E.D.D. BY LMP- 19/02/2023




- GESTATION : Single.
- PRESENTATION : Breech.
- FETAL HEART RATE : 152/mins, Regular.
- PLACENTA (SITE) : Anterior in body of uterus.
- (MATURITY) : Grade 'O'.
- B P D : 49 mms (Gest age is 20.5 Wks)
- H C : 185 mms (Gest age is 20.6 Wks).
- FEMORAL LENGTH : 35 mms (Gest age is 21 Wks).
- F A C : 147 mms (Gest age is 20 Wks).
- MEAN GESTATIONAL AGE : 21 Wks.
- FETAL ABDOMEN : Stomach, Kidneys & Urinary bladder are visualized.
- FETAL SPINE : No evidence of significant open neural tube defect.
- AMNIOTIC FLUID : Adequate.
- CERVICAL LENGTH / INT. OS : The cervical length is 3.7 cms. The internal os appear closed.

\*This study is not anomaly (Target) scan. Not all fetal congenital anomalies can be detected by Sonography as some malformations may be masked due to maturity, size of fetus, positioning & amniotic fluid volume. All measurements including estimated fetal weight are subject to statistical variations.

#### **IMPRESSION:**

- (1) SINGLE LIVE FETUS IS SEEN IN BREECH PRESENTATION.
- (2) APPROX. SONOLOGICAL GESTATIONAL AGE OF FETUS IS 21 WKS  $\pm$  1 WEEK.
- (3) PLACENTAL MATURATION IS GRADE 'O'.
- (4) APPROXIMATE FETAL WEIGHT IS 353 GMS.

ADVISED: FOLLOW-UP FOR FETAL WELL BEING.

  
DR. R.K. SAXENA.  
MD.

I HAVE NEITHER DETECTED NOR DISCLOSED THE SEX OF FETUS TO ANYBODY IN ANY MANNER

सक्सेना सोनोग्राफी, कलर डॉप्लर, मेमोग्राफी एवं डिजिटल एक्स-रे सेन्टर, रूपम टॉवर्स, पानी की टंकी के सामने, राइट हाउस, जबलपुर