

# విశ్వనాంయ హాస్పిటల్

(తల్లి మరియు పిల్లల హాస్పిటల్)

డా॥ సంచీప్ కుమార్ కజ్జం

M.B.B.S., M.D.(PAED), NALS

పులిచి మరియు చిన్నపిల్లల వైద్య నిపుణులు

రిజిస్టర్ నెం. 05627



డా॥ ప్రణతి కజ్జం

M.B.B.S., M.S.(OBG), F.MAS, D.MAS

ప్రసూతి మరియు స్త్రీల వైద్య నిపుణులు

ఐన్ ఫర్ లిచి మరియు ల్యాండ్ సర్జిక్ సర్జన్

(Gold Medalist), రిజిస్టర్ నెం. 00272

R

## OUT PATIENT DETAILS

Patient Name	: Mrs. RAJIYA SULTHANA	Mobile	: 7693395347
Reg No	: OP4200011688	App Date	: 18-10-2022 10:26 AM
Age / Gender	: 28Y/Female	MR No	: MR4200003863
Address	: NALGONDA	Doctor Name	: Dr. Pranathi K   MBBS, MS (OBG)



OP Valid Upto : 01-11-2022

- G3P1A1D1 at 12<sup>th</sup> wkg  
of constipation.

Wt: 40.21kg  
BP: 120/70  
Temp: 98.4°F

Lmp: 25/07/22  
Rup

NT- (2)

Any Double movement

Gr - Low  
Bp - 120/70 mmHg

P2 14/10

Temp 98

HL - 14/10

PLA - at 1st wkg 14/10

- 14/10

1) 1st wkg 14/10

2nd 14/10

3rd 14/10

4th 14/10

5th 14/10

6) 1st wkg 14/10

2nd 14/10

AC992626

(3)

సురక్ష హాస్పిటల్ ప్రక్కన, బొట్టుగూడ, ప్రకాశం బజార్, నల్లగొండ - 508 001.

24 గంటలు వైద్య సదుపాయం కలదు. ♦ అన్ని రకాల టీకాలు వేయబడును. ♦ సెయిన్స్ సెయిన్స్ వేయబడును.



# Kalpana Fetal Medicine and Scan Center

AC 992626

Protecting the Precious...

MRS RAZIYA SULTHANA

Date of birth : 02 June 1991, Examination date: 18 October 2022

Address: NALGONDA

Hospital no.: KFC6918

Mobile phone: 7893395347

Referring doctor: PRANATHI

## Maternal / Pregnancy Characteristics:

Racial origin: South Asian (Indian, Pakistani, Bangladeshi).

Parity: 0.

Maternal weight: 40.0 kg; Height: 152.0 cm.

Smoking in this pregnancy: no; Diabetes Mellitus: no; Chronic hypertension: no; Systemic lupus erythematosus: no; Antiphospholipid syndrome: no; Patient's mother had preeclampsia: no.

Method of conception: Spontaneous;

Last period: 25 July 2022

EDD by dates: 01 May 2023

## First Trimester Ultrasound:

US machine: E 6. Visualisation: good.

Gestational age: 12 weeks + 1 days from dates

EDD by scan: 01 May 2023

Findings	Alive fetus
Fetal heart activity	visualised
Fetal heart rate	152 bpm
Crown-rump length (CRL)	62.0 mm
Nuchal translucency (NT)	1.6 mm
Biparietal diameter (BPD)	22.0 mm
Ductus Venosus PI	1.000
Placenta	POSTERIOR
Amniotic fluid	normal

## Chromosomal markers:

Nasal bone: present; Tricuspid Doppler: normal.

## Fetal anatomy:

Skull/brain: appears normal; Spine: appears normal; Heart: Appears normal; Abdominal wall: appears normal; Stomach: visible; Bladder / Kidneys: visible; Hands: both visible; Feet: both visible.

Uterine artery PI: 0.95 equivalent to 0.560 MoM  
Endocervical length: 34.0 mm

## Risks / Counselling:

Patient counselled and consent given.

Operator: Lekkala Kalpana, FMF Id: 173593

Condition	Background risk	Adjusted risk
Trisomy 21	1: 537	1: 8692
Trisomy 18	1: 1300	1: 6435
Trisomy 13	1: 4081	<1: 20000
Preeclampsia before 34 weeks		1: 2140
Fetal growth restriction before 37 weeks		1: 122



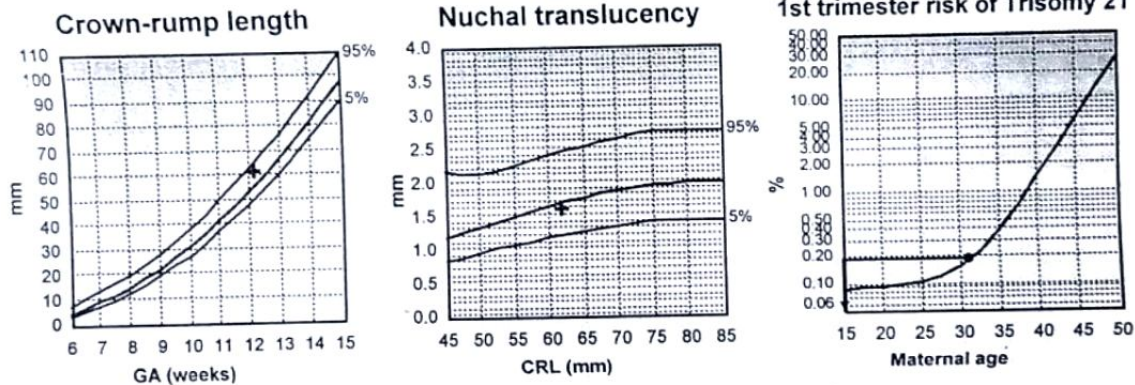
# First Trimester Screening Fetal Medicine and Scan Center

*Protecting the Precious...*

The background risk for aneuploidies is based on maternal age (31 years). The adjusted risk is the risk at the time of screening, calculated on the basis of the background risk and ultrasound factors (fetal nuchal translucency thickness, nasal bone, fetal heart rate).

Risks for preeclampsia and fetal growth restriction are based on maternal demographic characteristics, medical and obstetric history and uterine artery Doppler. All biophysical markers are corrected as necessary according to several maternal characteristics including racial origin, weight, height, smoking, method of conception and parity.

The estimated risk is calculated by the FMF-2012 software (version 2.81) and is based on findings from extensive research coordinated by the Fetal Medicine Foundation (UK Registered charity 1037116). The risk is only valid if the ultrasound scan was performed by a sonographer who has been accredited by the Fetal Medicine Foundation and has submitted results for regular audit (see [www.fetalmedicine.com](http://www.fetalmedicine.com)).



## Comments

Single live intra uterine fetus corresponding to 12 weeks 1 days.

Down syndrome screen negative based on NT scan.

Suggested DOUBLE MARKER.

Suggested TIFFA SCAN at 19 to 20 weeks. ( DEC 6th TO 10th )

I, Dr. L. Kalpana Reddy, declared that while conducting ultrasonography / imaging scanning on Mrs. RAZIYA SULTHANA, I have neither detected nor disclosed the sex of fetus to any body in any manner.

DR. L. KALPANA REDDY  
FETAL MEDICINE CONSULTANT &  
KALPANA FETAL MEDICINE &  
SCAN CENTER  
H.No 8-2-106 Ansari Colony,  
Opp: Govt. Medical College, NALGONDA  
194/100-1/ND1/NLG/200