



# అవేణి హాస్పిటల్ TRIVENI HOSPITAL



గ్రీన్లాండ్ హాస్పిటల్ గేటు ఎదురుగా, డాక్టర్స్ కాలనీ, నల్లగొండ.

**Dr. G. TRIVENI**

M.B.B.S., M.S.(Obgy.)

Obstetrician & Gynaecologist

Infertility Specialist

Regd. No. 52814

సంప్రదించు వేళలు :

ప్రతిరోజు ఉ. గం. 10-00 నుండి రాత్రి గం. 7-00 వరకు  
ఆదివారం ఉ. గం. 10-00 నుండి మ. గం. 2-00 వరకు

Cell: 7569550452, 6302900950

23595552

**డా॥ జి. త్రివేణి**

M.B.B.S., M.S.(Obgy.)

ప్రసూతి మరియు స్త్రీల వ్యాధి నిపుణులు

Regd. No. 52814

Pt.'s Name ..... Mrs. Chincha. wife - Gopi. Vill. .... M. Gudum. Age. 22. Sex. F.

**GPLAD**

E YMA E Ucy

Date: 07.11.22

Valid Upto: 2.11.22

Temp: 67.10

Temp: (N)

PR: 82b

BP: 110/70 mmHg

Heart: SIS (P)

Lungs: NAD

clo Pan abd

o 1/2 cc Pan

Abd

PR 80b

PIA. at 12-14h  
low

LMP: 27.07.2022

DOB: 07.01.1999

LMP :

EDD :

S.EDD :

ML :

Consanguinity Yes/No.

Menstrual Periods :

Reg/Irregular

Adm  
DH

T. R. B. 15d

1. T. Pan - 15d
2. T. Shelled + 15d
3. T. Fotherham + 15d
4. Syp Malt + 15d
5. Moe per per

MRS SHIRISHA

Date of birth : 01 July 1999, Examination date: 07 November 2022

Address: KATTANGUR

Hospital no.: KFC6544

Mobile phone: 950533647

Referring doctor: TRIVENI

## Maternal / Pregnancy Characteristics:

Racial origin: South Asian (Indian, Pakistani, Bangladeshi).

Parity: 1; Deliveries at or after 37 weeks: 1.

Maternal weight: 67.0 kg; Height: 152.0 cm.

Smoking in this pregnancy: no; Diabetes Mellitus: no; Chronic hypertension: no; Systemic lupus erythematosus: no; Antiphospholipid syndrome: no; Preeclampsia in previous pregnancy: no; Previous small baby: no; Patient's mother had preeclampsia: no.

Method of conception: Spontaneous;

Last period: 27 July 2022

EDD by dates: 03 May 2023

## First Trimester Ultrasound:

US machine: E 6. Visualisation: good.

Gestational age: 13 weeks + 1 days from CRL

EDD by scan: 14 May 2023

Findings	Alive fetus	
Fetal heart activity	visualised	
Fetal heart rate	146 bpm	● —
Crown-rump length (CRL)	70.0 mm	— ●
Nuchal translucency (NT)	2.0 mm	
Biparietal diameter (BPD)	27.0 mm	
Ductus Venosus PI	1.100	— ● —
Placenta	ANTERIOR	
Amniotic fluid	normal	

## Chromosomal markers:

Nasal bone: present; Tricuspid Doppler: normal.

## Fetal anatomy:

Skull/brain: appears normal; Spine: appears normal; Heart: Appears normal; Abdominal wall: appears normal; Stomach: visible; Bladder / Kidneys: visible; Hands: both visible; Feet: both visible.

Uterine artery PI: 0.85

equivalent to 0.550 MoM

Endocervical length: 32.0 mm

## Risks / Counselling:

Patient counselled and consent given.

Operator: Lekkala Kalpana, FMF Id: 173593

Condition	Background risk	Adjusted risk
Trisomy 21	1: 1044	1: 7631
Trisomy 18	1: 2623	1: 10730
Trisomy 13	1: 8208	<1: 20000
Preeclampsia before 34 weeks		1: 3628



# Kalpana Fetal Medicine and Scan Center

*Protecting the Precious...*

Fetal growth restriction before 37 weeks

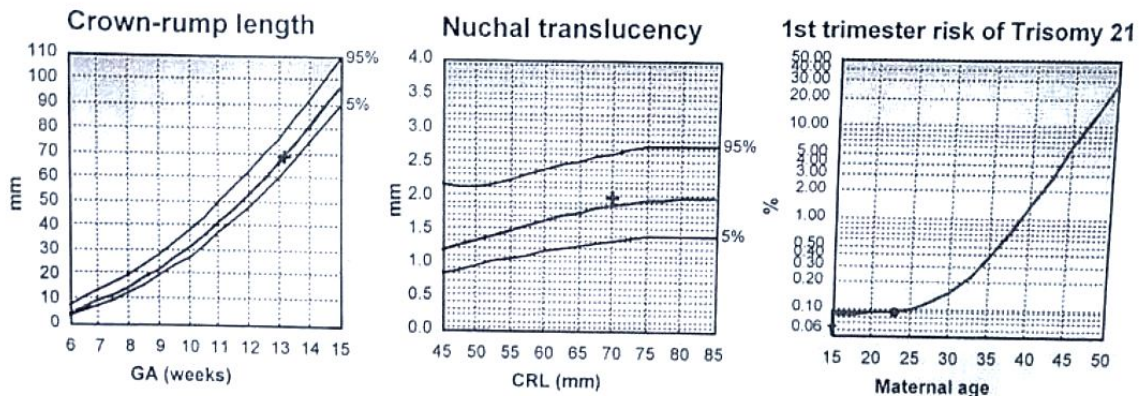
1: 503

The background risk for aneuploidies is based on maternal age (23 years). The adjusted risk is the risk at the time of screening, calculated on the basis of the background risk and ultrasound factors (fetal nuchal translucency thickness, nasal bone, fetal heart rate).

Risks for preeclampsia and fetal growth restriction are based on maternal demographic characteristics, medical and obstetric history and uterine artery Doppler.

All biophysical markers are corrected as necessary according to several maternal characteristics including racial origin, weight, height, smoking, method of conception and parity.

The estimated risk is calculated by the FMF-2012 software (version 2.81) and is based on findings from extensive research coordinated by the Fetal Medicine Foundation (UK Registered charity 1037116). The risk is only valid if the ultrasound scan was performed by a sonographer who has been accredited by the Fetal Medicine Foundation and has submitted results for regular audit (see [www.fetalmedicine.com](http://www.fetalmedicine.com)).



## Comments

Single live intra uterine fetus corresponding to 13 weeks 1 days.

Down syndrome screen negative based on NT scan.

Suggested DOUBLE MARKER.

Suggested TIFFA SCAN at 19 to 20 weeks. ( DEC 19th to 23rd )

I, Dr. L. Kalpana Reddy, declared that while conducting ultrasonography / imaging scanning on Mrs. SHIRISHA, I have neither detected nor disclosed the sex of fetus to any body in any manner.

**DR. L. KALPANA REDDY**  
FETAL MEDICINE CONSULTANT