



# త్రివేణి హాస్పిటల్ TRIVENI HOSPITAL



గ్రీన్లాండ్ హాస్పిటల్ గేటు ఎదురుగా, డాక్టర్స్ కాలనీ, నల్లగొండ.

**Dr. G. TRIVENI**

M.B.B.S., M.S.(Obgy.)

Obstetrician & Gynaecologist

Infertility Specialist

Regd. No. 52814

సంప్రదించు వేళలు :  
ప్రతిరోజు డా॥ గం. 10-00 నుండి రాత్రి గం. 7-00 వరకు  
ఆదివారం డా॥ గం. 10-00 నుండి మో॥ గం. 2-00 వరకు

Cell: 7569550452, 6302900950

23595948

**డా॥ జి. త్రివేణి**

M.B.B.S., M.S.(Obgy.)

ప్రసూతి మరియు స్త్రీల వ్యాధి నిపుణులు

Regd. No. 52814

Pt.'s Name Karuna W/o: Venkatesh Vill. Nalgonda Age 27 Sex F

**G P L A D**

E U P R 2 Bichu

Date: 28/11/22

Valid Upto: 11/12/22

Wt : 43 kgs

Temp : 98.6

PR : 82 mb

BP : 100/70 mm Hg

Heart : 84 bpm

Lungs : Clear

DOB: 07-12-1993

Adm  
DM

10/12/22/2023

10/10/22

01/11/22

PR. Solu

Placental path

LMP : 13-08-2012

EDD :

S.EDD :

ML :

Consanguinity Yes/No.

Menstrual Periods :

Reg/Irregular

1. T. Pan D  
150

2. T. Shalini  
+ 150

3. T. R. S. S.  
1150

4. Mad. Prabha  
1000

# First Trimester Screening Report

Kalpana Referral Medicine and Scan Center

Protecting the Precious...

MRS KARUNA

Date of birth : 07 December 1993, Examination date: 27 November 2022

Address: NALGONDA

Hospital no.: KFC6890

Mobile phone: 9966343720

Referring doctor: Indira

## Maternal / Pregnancy Characteristics:

Racial origin: South Asian (Indian, Pakistani, Bangladeshi).

Parity: 0.

Maternal weight: 43.0 kg; Height: 152.0 cm.

Smoking in this pregnancy: no; Diabetes Mellitus: no; Chronic hypertension: no; Systemic lupus erythematosus: no; Antiphospholipid syndrome: no; Patient's mother had preeclampsia: no.

Method of conception: Spontaneous;

Last period: 13 August 2022

EDD by dates: 20 May 2023

## First Trimester Ultrasound:

US machine: E 6. Visualisation: good.

Gestational age: 13 weeks + 1 days from CRL

EDD by scan: 03 June 2023

Findings	Alive fetus
Fetal heart activity	visualised
Fetal heart rate	159 bpm
Crown-rump length (CRL)	70.0 mm
Nuchal translucency (NT)	2.0 mm
Biparietal diameter (BPD)	23.0 mm
Ductus Venosus PI	1.000
Placenta	ANTERIOR
Amniotic fluid	normal

## Chromosomal markers:

Nasal bone: present; Tricuspid Doppler: normal.

## Fetal anatomy:

Skull/brain: appears normal; Spine: appears normal; Heart: Appears normal; Abdominal wall: appears normal; Stomach: visible; Bladder / Kidneys: visible; Hands: both visible; Feet: both visible.

Uterine artery PI: 1.40 equivalent to 0.860 MoM

Endocervical length: 33.0 mm

## Risks / Counselling:

Patient counselled and consent given.

Operator: Lekkala Kalpana, FMF Id: 173593

Condition	Background risk	Adjusted risk
Trisomy 21	1: 743	1: 5432
Trisomy 18	1: 1868	1: 7637
Trisomy 13	1: 5845	<1: 20000
Preeclampsia before 34 weeks		1: 769
Fetal growth restriction before 37 weeks		1: 112

Page 1 of 2 printed on 27 November 2022 - MRS KARUNA examined on 27 November 2022.  
# 8-2-71/1/ఎ, గ్రీన్లాండ్ హాస్పిటల్ ఎదురుగా, డాక్టర్స్ కాలనీ, నల్లగొండ - 508 001. తెలంగాణ

For Appointment : ☎ +91 8522 856 854 | +91 9704 234 016



# First Trimester Screening Report

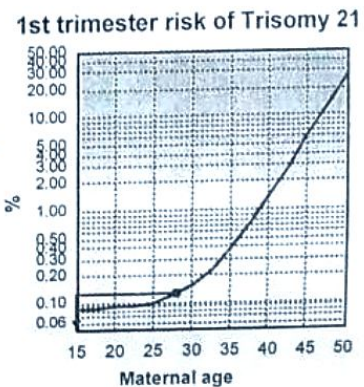
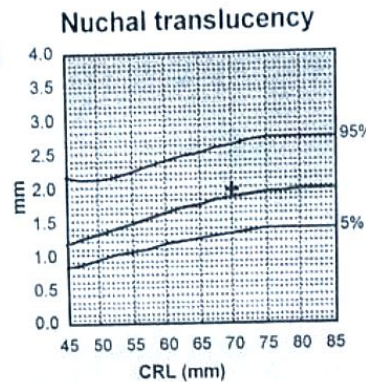
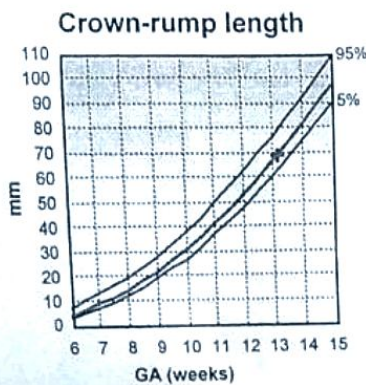
Kalpana Fetal Medicine and Scan Center

Protecting the Precious...

The background risk for aneuploidies is based on maternal age (28 years). The adjusted risk is the risk at the time of screening, calculated on the basis of the background risk and ultrasound factors (fetal nuchal translucency thickness, nasal bone, fetal heart rate).

Risks for preeclampsia and fetal growth restriction are based on maternal demographic characteristics, medical and obstetric history and uterine artery Doppler. All biophysical markers are corrected as necessary according to several maternal characteristics including racial origin, weight, height, smoking, method of conception and parity.

The estimated risk is calculated by the FMF-2012 software (version 2.81) and is based on findings from extensive research coordinated by the Fetal Medicine Foundation (UK Registered charity 1037116). The risk is only valid if the ultrasound scan was performed by a sonographer who has been accredited by the Fetal Medicine Foundation and has submitted results for regular audit (see [www.fetalmedicine.com](http://www.fetalmedicine.com)).



## Comments

Single live intra uterine fetus corresponding to 13 weeks 1 days.


Down syndrome screen negative based on NT scan.

? BICORNUATE UTERUS.

Suggested DOUBLE MARKER.

Suggested TIFFA SCAN at 19 to 20 weeks. ( Jan 10th to 14th )

I, Dr. L. Kalpana Reddy, declared that while conducting ultrasonography / imaging scanning on Mrs. KARUNA, I have neither detected nor disclosed the sex of fetus to any body in any manner.

  
DR. L. KALPANA REDDY  
FETAL MEDICINE CONSULTANT