



HINGNA SONOGRAPHY CENTRE

Dr. Rajeshwar Gudadhe
M.B.B.S., D.M.R.E.
Worked at : CHIKITSA
Diagnostic Centre, Mumbai
IGGMC, Nagpur
OCHRI, Nagpur

(Reg. No. 166/2022)



Dr. Rina Gudadhe
M.B.B.S., D.M.R.E.
Worked at : IGGMC, Nagpur
Getwell Hospital, Nagpur
Lata Mangeshkar Hospital, Nagpur
Mure Memorial Hospital, Nagpur

NAME : MRS. NAMRATA GHORMADE

AGE : 25 Yr

REF BY : DR. P.PRASAD

DATED : March 15, 2023

ANOMALY SCAN

LMP - 27.10.2022

MA - 19 wks 6 days

EDD - 03.08.2023

Real time USG of II trimester of pregnancy reveals a single live intrauterine pregnancy in changing presentation.

Normal foetal movements and cardiac activity noted. FHR-149 bpm.

The placenta is anterior and of grade I maturity. It is 1.9 cm away from the internal os (low lying placenta)

Three vessel cord seen.

Amniotic fluid is normal.

Cervical length is adequate. Internal OS is closed. Cx- 4.7 cm

Fetal maturity, as derived from fetal parameters is as follows.

BPD - 42 mm - 18 wks, 5 days

AUA - 18 wks, 6 days

HC - 163 mm - 19 wks, 0 days

USG EDD - 10.08.2023

AC - 134 mm - 18 wks, 6 days

FL - 30 mm - 19 wks, 1 days

EFW - 272 gms

ANOMALY SCAN

➤ **Cranium** - Bones of the skull appears normal.

Brain parenchyma appears normal, No e/o SOL.

Choroid plexus appears normal. No e/o hydrocephalus. E/o 7.7 x 2.6 mm and 6.6 x 2.1 mm size cyst in both left and right choroid plexus resp.

Posterior fossa shows normal features, cerebellum is w shaped with normal vermis.

Cerebellar transverse diameter 19.8 mm.

Cisterna magna 4.5 mm- normal upto 8 mm (8-10 borderline and > 10 mm abnormal).

• 3D/4D Ultrasonography • Doppler Studies • Digital X-Ray & Procedures

215, 2nd Floor, Above Reliance Smart, Jalaram-Mangalam Complex,
Opp. Mahindra & Mahindra Company, Hingna, Nagpur.

Time : 10.00 am to 6.00 pm
Mob. : 8805208080, 9765408080

HINGNA SONOGRAPHY CENTRE

Dr. Rajeshwar Gudadhe
M.B.B.S., D.M.R.E.
Worked at : CHIKITSA
Diagnostic Centre, Mumbai
IGGMC, Nagpur
OCHRI, Nagpur

(Reg. No. 166/2022)



Dr. Rina Gudadhe
M.B.B.S., D.M.R.E.
Worked at : IGGMC, Nagpur
Getwell Hospital, Nagpur
Lata Mangeshkar Hospital, Nagpur
Mure Memorial Hospital, Nagpur

Right lateral ventricle- 7.5 mm

Left lateral ventricle- 6.8 mm (abnormal > 10 mm)

- **Neck** – nuchal fold thickness is 3.5 mm – within normal limit . more than 6 mm is abnormal.
- **Face** – profile view reveals normal nasal bone. **nasal bone length - 6.4 mm**
- **Orbits** – Both orbits, OD, IOD, appears normal. Both lenses seen.
- **Lips** – appears normal.
- **Nostrils** – Both nostrils seen and normal.
- **Thorax** – **Ribs**- appears normal with normal chest wall.
Lungs – both lungs seen with normal echogenicity.
Diaphragm appears normal .
Heart appears normal in situs, position, shape, size, axis, 4 chamber view seen with normal outflow tracts and normal both arches.
- **Spine** – cervical ,dorsal, lumbar and sacro-coccygeal vertebrae appears normal.
- **Abdomen** – single bubble of stomach seen .
Liver shows normal echopattern.
Bowel shows normal echogenicity.
Both kidneys are normal in shape and position. **Both renal pelvises dilated AP diameter are 5.4 mm and 5.2 mm on left and right side resp.**
Bladder is well distended and normal.
- **Skeleton** – long bones of upper and lower limbs and mandible appears normal.

ARTERY	PI
Right uterine	0.9
Left uterine	0.7

• 3D/4D Ultrasonography • Doppler Studies • Digital X-Ray & Procedures

2nd Floor, Above Reliance Smart, Jalaram-Mangalam Complex,
Opp. Mahindra & Mahindra Company, Hingna, Nagpur.

Time : 10.00 am to 6.00 pm
Mob. : 8805208080, 9765408080

HINGNA SONOGRAPHY CENTRE

Dr. Rajeshwar Gudadhe
M.B.B.S., D.M.R.E.
Worked at : CHIKITSA
Diagnostic Centre, Mumbai
IGGMC, Nagpur
OCHRI, Nagpur

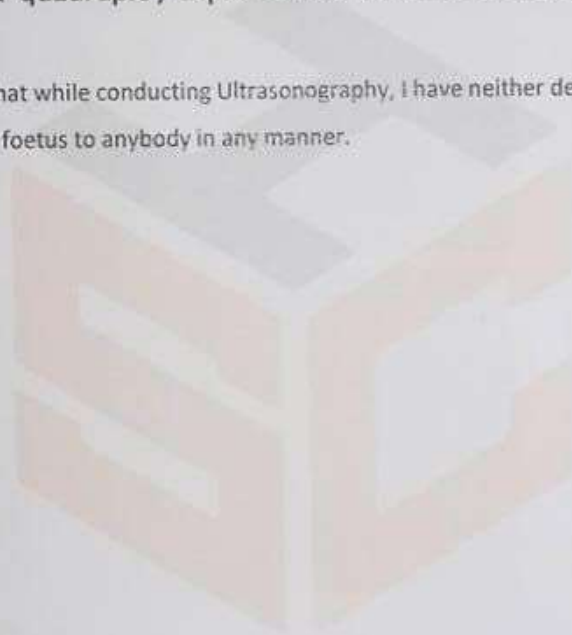
(Reg. No. 166/2022)



Dr. Rina Gudadhe
M.B.B.S., D.M.R.E.
Worked at : IGGMC, Nagpur
Getwell Hospital, Nagpur
Lata Mangeshkar Hospital, Nagpur
Mure Memorial Hospital, Nagpur

IMPRESSION: Single live intrauterine pregnancy of AUA 18 wks 6 day with dilated bilateral renal pelvises and bilateral choroid plexus cyst .
suggested quadruple / triple marker for further the evaluation

I, Dr. Rina gudadhe, declare that while conducting Ultrasonography, I have neither detected nor disclosed the sex of her foetus to anybody in any manner.



DR. R. GUDADHE
MBBS, DMRE

• 3D/4D Ultrasonography • Doppler Studies • Digital X-Ray & Procedures

2nd Floor, Above Reliance Smart, Jalaram-Mangalam Complex,
Opp. Mahindra & Mahindra Company, Hingna, Nagpur.

Time : 10.00 am to 6.00 pm
Mob. : 8805208080, 9765408080