

## Dr. Neelam Chhajed

Consultant Feto-Maternal Medicine  
Reg. No. 2001/02/469, PCPNDT Reg. No. 476  
MRCOG, MD DNB (O & G), MBBS  
International Masters in fetal Medicine ( Barcelona )  
FMF UK Certified NT & Doppler Specialist (Id-71536)  
Past Exp. North Cumbria University, Hospital (UK)



**NEWLIFE  
HOSPITAL**  
& FETAL MEDICINE CENTRE  
(A UNIT OF CHHAJED HEALTHCARE PVT. LTD.)  
Reg. No. 1031

Patient Name	Mrs. SHRUTI RAHUL NAGPURE	Age (yrs)	28Y	D.O.B: 09/04/1995
Referred by	DR. SWATI MALPANI	Visit date	29/04/2023	
Patient Id	NFMCE10/11133	Equipment	Voluson E10	
LMP	10/02/2023	LMP EDD	17/11/2023	
LMP GA	11W1D	US GA	11W5D	

### Early pregnancy (Nuchal Scan) USG report

Real time b mode ultrasonography done via transabdominal route by voluson e10

#### Indication: NT scan

A single live intrauterine gestation seen with spontaneous movements.

Liquor appears to be adequate for gestation.

Cardiac activity seen with FHR 168 BPM.

Flow across tricuspid valve and Ductus venosus is normal.

**Nuchal Translucency measures 1.6 mm and is 61 percentile for this CRL.**

Intracranial translucency appears normal. ( 1.7 mm )

Nasal bone seen measuring 2.5 mm ( 57.9 %tile)

Bladder and stomach bubble seen.

All four limbs with spontaneous movement seen.

Spine, facial skeleton forming. Midline falx seen

Placenta forming – Anteriorly, 0.72 cm from os .

No evidence of any sub chorionic collection at present.

Cervical length appears normal and measures 2.67 cm (os closed.)Transabdominal

#### Uterine Artery Doppler (Pulsatility index)

Right Uterine Artery PI	Left Uterine Artery PI	Mean uterine artery PI:
1.74	2.42	2.08
Corresponding to : 73 <sup>rd</sup> %tile which is within normal limits.		

(Ref percentiles: fetal medicine Barcelona)

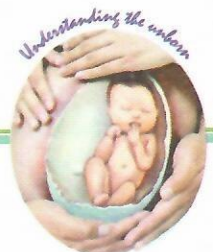Address : 253, Canal Road, Near Sewakunj Agrawal Bichayat Kendra, Giripeth, Nagpur-440 010

Tel : 0712 - 3554990 Mob : 86683 62579

Web : www.nagpurfetalmedicinecentre.com

Timing : Mor. 9.30 am to Eve. 6.00 pm (Sunday Closed)

Email : newlifeclinic15@gmail.com



## Dr. Neelam Chhajed

Consultant Feto-Maternal Medicine

Reg. No. 2001/02/469, PCPNDT Reg. No. 476

MRCOG, MD DNB (O & G), MBBS

International Masters in fetal Medicine ( Barcelona )

FMF UK Certified NT & Doppler Specialist (Id-71536)

Past Exp. North Cumbria University, Hospital (UK)



**NEWLIFE  
HOSPITAL**

& FETAL MEDICINE CENTRE

(A UNIT OF CHHAJED HEALTHCARE PVT. LTD.)

Reg. No. 1031

### Fetal Biometry

PARAMETER	MEASUREMENTS(cm)	GESTATIONAL AGE
B.P.D.	1.79	12W5D
AC	4.85	
F.L.	0.71	12W1D
C.R.L	5.08	11W5D

### Impression:

Single live intrauterine gestation corresponding to average Gestational age of 11W5D with Nuchal translucency of 1.6 mm

Estimated fetal weight as per BPD, AC& FL is approximately 53+/-8g

Ultrasound age and gestational age of fetus corresponding hence EDD assigned as per LMP

(Detailed Anomaly scan suggested @ 18-20 weeks)

  
**Dr. Neelam Chhajed**

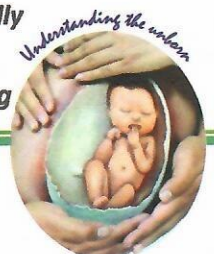
Consultant fetal medicine

**Many thanks for the referral.**

### Declaration of doctor/person conducting ultrasonography/image scanning.

I, Dr. Neelam Chhajed, declare that while conducting ultrasonography, I have neither detected nor disclosed the sex of the fetus to anybody in any manner.

*(P.S It must be noted that detailed feta anatomy may not always be clear due to technical difficulties related to advanced gestational age, feta position, reduced liquor, maternal abdominal wall thickness fetal movements etc. therefore all fetal anomalies may not be detected, also kindly note that ear and digits examination is not a routine part of this exam, also kindly note that anomalies like isolated anal atresia may not be picked up on scan due to limitation of imaging these organs.)*



Address : 253, Canal Road, Near Sewakunj Agrawal Bichayat Kendra, Giripeth, Nagpur-440 010

Tel : 0712 - 3554990 Mob : 86683 62579

Web : www.nagpurfetalmedicinecentre.com

Timing : Mor. 9.30 am to Eve. 6.00 pm (Sunday Closed)

Email : newlifeclinic15@gmail.com



**NEW LIFE FETAL MEDICINE AND THERAPY CENTRE**  
253, Canal Road, Near Sewakunj Bichyat Kendra , Giripeth Nagpur 440010

**Patient ID: NFMCE10/11133**  
**Name: NAGPURE SHRUTI RAHUL**  
**Sex: F**

**Date: 29-Apr-2023**  
**Ref By: DR. SWATI MALPANI**  
**Study: NT SCAN**

