

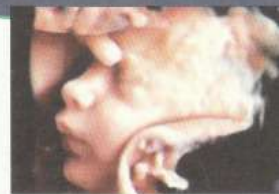

DR. UTKARSH MODAK

MBBS - NKPSIMS

DMRD - Govt Medical College, Nagpur

DNB - Breach Candy Hospital, Mumbai



■ Ultrasonography ■ Advanced 3D /4D Sonography ■ Colour Doppler ■ 2D ECHO ■ Digital X Ray

Patients Name : Mrs. Yogita Kamble
Age : 34 Years / F
Referred by : Dr. Rohini Dravid
Date : 25 / June / 2023
Examination : USG - Obstetric Anomaly Scan

OBSERVATION:

EDD assigned as per dating scan - 21/11/2023

Corrected GA - 18 Weeks , 5 Days.

#> Single live intra-uterine fetus with , changing lie , presently cephalic presentation.

#> Fetal body movements & cardiac activity appears normal. FHR - 148 BPM.

FOETAL BIOMETRY:-

	mm	Weeks	Days
BPD	45	19	6
HC	57	19	4
AC	130	18	4
FL	28	18	6
AGA		19	1

	mm
TCD	19.2
Lateral ventricle	6.0
Cisterna magna	4.8
Nuchal skin fold thickness	1.8
Inter-ocular distance	11.3
Bi-ocular dist	33.3

#> GA by USG - 19 weeks 1 days

#> Fetal weight - 258 gms \pm 38 gms.

#> Placenta is posterior , grade I maturity. Cord is normal and three vesseled.

#> Liquor is adequate for the period of gestational age.

#> Cervix appears normal in length, measuring 3.4 cm. Internal os closed.

Anatomical survey:

FETAL BRAIN:

Fetal cranial vault appears normal in size, shape & shows normal Echogenicity.

B/L thalami appear normal. Ventricular system appears normal.

CSP appears normal. B/L Choroid Plexus appears normal.

Post-Fossa structure appears normal. Cisterna magna appears normal.

Visualized brain parenchyma appears normal in echoes. No focal lesion seen.

FETAL FACE:

Nasal bone appears normal. Bony orbits appear normal.

Nose & lip appears normal. No obvious e/o cleft lip seen.

DR. UTKARSH MODAK

MBBS, DMRD, DNB

Reg. No. - MMC 2014/03/0476

PTO

Disclaimer : Patient's identity based on his declaration. Report not valid for medico-legal purpose. Different diseases may produce similar appearance hence to be correlated clinically. Radiological measurements may have variations due to technical reasons. The report is for information and for interpretation of the referring doctor only. Should the results indicate an unexpected abnormality, the same should be reconfirmed. Neither Sunshine Advanced Imaging Centre nor its employees / representatives assume any liability, responsibility for any loss or damage that may be incurred by any person as a result of presuming the meanings or contents of the report. All fetal congenital may not be visualized on ultrasound. This report is subject to the jurisdiction of the courts at Nagpur only.

Address : Plot No. 3, Radke Layout, Hingna Road, Near Banshi Nagar Metro Station, Nagpur. Contact : 7020331727 | Email : sunshineimagingcentre@gmail.com

Patient Name: Yogita Kambale. D/A 27/06/23


DOB: 5/11/88

Weight: 49 kg

Height: 5.3

Adm: Quadruple marker.

Ref by True Care Clinical Path lab

 लता मंगेशकर हॉस्पिटल, हिंगना रोड, नागपुर. फोन : 07104-665000

महाराष्ट्र ज्योतिबा फुले जन आरोग्य योजना (राजीव गांधी जीवनदायी आरोग्य योजना), सी.जी.एच.एस., डब्ल्यू.सी.एल.,
महाराष्ट्र पोलीस कुटुंब आरोग्य योजना, बी.पी.एल. योजना, जननी सुरक्षा योजना, प्रधानमंत्री जन आरोग्य योजना (आयुष्मान भारत)

★ अल्प दूरों में उत्कृष्ट उपचार सेवाएं ★

संपर्क : श्री. जितेंद्र नुले (9923041907) । श्री. विशाल खुरसंगे (9730921410)