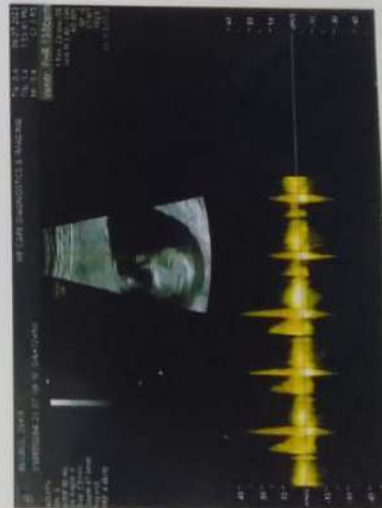
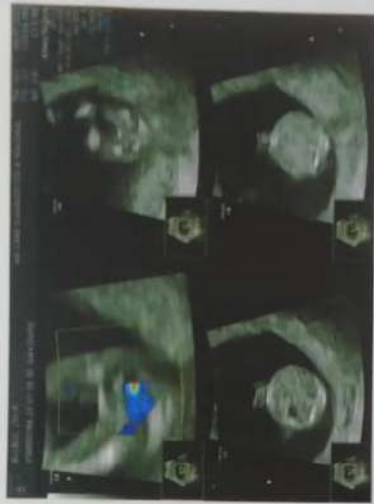
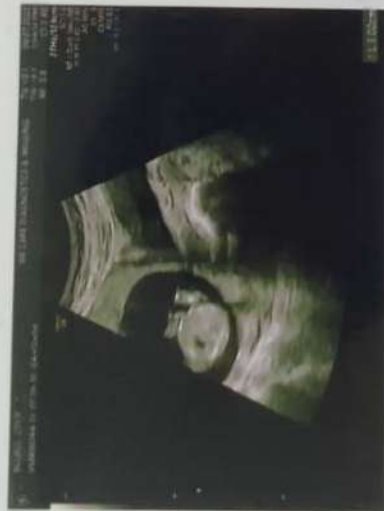
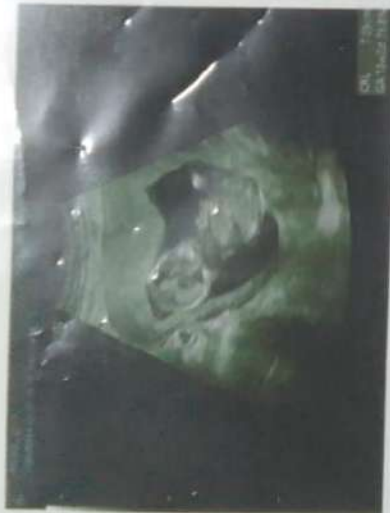
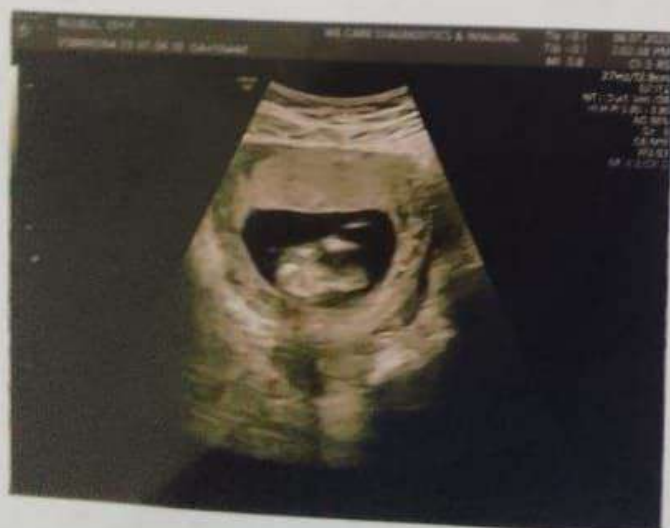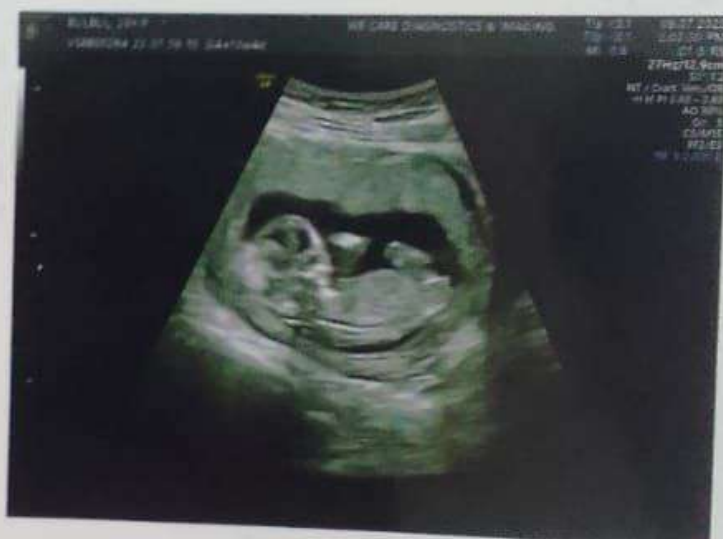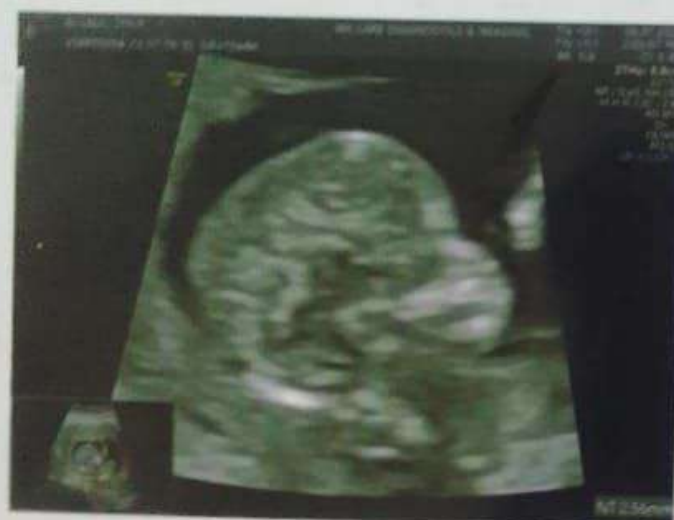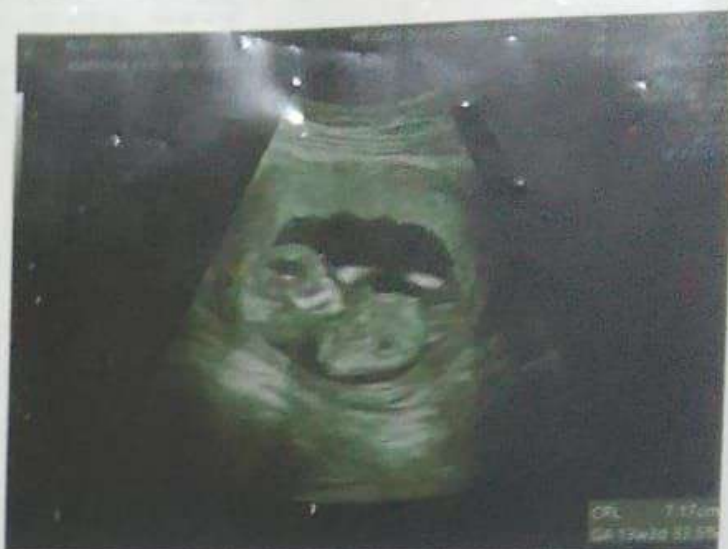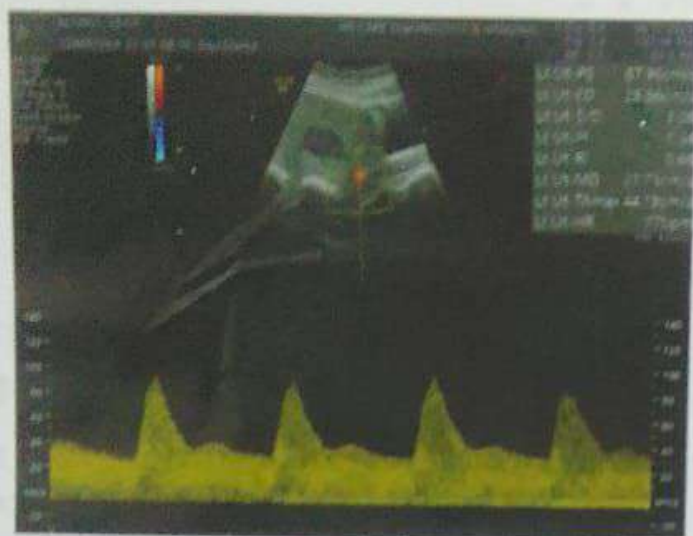| WT CART LACADRE'S MAGNUS   |       |         |     |    |      |        |        |     |     |
|----------------------------|-------|---------|-----|----|------|--------|--------|-----|-----|
| Date: 4.05.2018            |       |         |     |    |      |        |        |     |     |
| Time: 17.00.00.00          |       |         |     |    |      |        |        |     |     |
| Name: [Blank]              |       |         |     |    |      |        |        |     |     |
| Age: [Blank]               |       |         |     |    |      |        |        |     |     |
| Sex: [Blank]               |       |         |     |    |      |        |        |     |     |
| Height: [Blank]            |       |         |     |    |      |        |        |     |     |
| Weight: [Blank]            |       |         |     |    |      |        |        |     |     |
| Blood Pressure: [Blank]    |       |         |     |    |      |        |        |     |     |
| Heart Rate: [Blank]        |       |         |     |    |      |        |        |     |     |
| Respiratory Rate: [Blank]  |       |         |     |    |      |        |        |     |     |
| Oxygen Saturation: [Blank] |       |         |     |    |      |        |        |     |     |
| Pain Scale: [Blank]        |       |         |     |    |      |        |        |     |     |
| Mental Status: [Blank]     |       |         |     |    |      |        |        |     |     |
| Vital Signs Summary:       |       |         |     |    |      |        |        |     |     |
| Temp                       | Pulse | BP      | HR  | RR | SpO2 | Weight | Height | Age | Sex |
| 37.5                       | 90    | 120/80  | 75  | 18 | 98   | 70     | 170    | 25  | M   |
| 37.8                       | 95    | 125/85  | 78  | 20 | 97   | 72     | 172    | 26  | M   |
| 38.0                       | 100   | 130/90  | 80  | 22 | 96   | 74     | 174    | 27  | M   |
| 38.2                       | 105   | 135/95  | 85  | 25 | 95   | 76     | 176    | 28  | M   |
| 38.5                       | 110   | 140/100 | 90  | 28 | 94   | 78     | 178    | 29  | M   |
| 38.8                       | 115   | 145/105 | 95  | 30 | 93   | 80     | 180    | 30  | M   |
| 39.0                       | 120   | 150/110 | 100 | 32 | 92   | 82     | 182    | 31  | M   |
| 39.2                       | 125   | 155/115 | 105 | 35 | 91   | 84     | 184    | 32  | M   |
| 39.5                       | 130   | 160/120 | 110 | 38 | 90   | 86     | 186    | 33  | M   |
| 39.8                       | 135   | 165/125 | 115 | 40 | 89   | 88     | 188    | 34  | M   |
| 40.0                       | 140   | 170/130 | 120 | 42 | 88   | 90     | 190    | 35  | M   |

## First Trimester Screening Report

Fetal growth restriction before 37 weeks

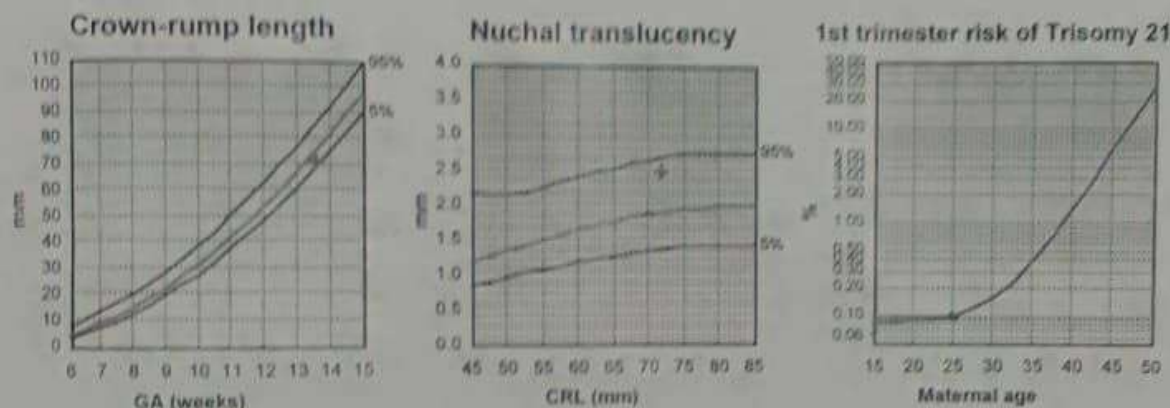
1: 196

The background risk for aneuploidies is based on maternal age (25 years). The adjusted risk is the risk at the time of screening, calculated on the basis of the background risk and ultrasound factors (fetal nuchal translucency thickness, nasal bone, tricuspid Doppler, ductus venosus Doppler, fetal heart rate).

Risks for preeclampsia and fetal growth restriction are based on maternal demographic characteristics, medical and obstetric history, uterine artery Doppler and mean arterial pressure (MAP).

All biophysical markers are corrected as necessary according to several maternal characteristics including racial origin, weight, height, smoking, method of conception and parity.

The estimated risk is calculated by the FMF-2012 software (version 2.81) and is based on findings from extensive research coordinated by the Fetal Medicine Foundation (UK Registered charity 1037116). The risk is only valid if the ultrasound scan was performed by a sonographer who has been accredited by the Fetal Medicine Foundation and has submitted results for regular audit (see [www.fetalmedicine.com](http://www.fetalmedicine.com)).





# First Trimester Screening Report

Verma Bulbul

Date of birth : 26 February 1998, Examination date: 06 July 2023

Address: Hno. 446 B- sector om nagar  
kolar road  
BHOPAL  
INDIA

Referring doctor: DR. PRIYANKA TIWARI

## Maternal / Pregnancy Characteristics:

Racial origin: South Asian (Indian, Pakistani, Bangladeshi).

Parity: 0.

Maternal weight: 54.0 kg; Height: 157.5 cm.

Smoking in this pregnancy: no; Diabetes Mellitus: no; Chronic hypertension: no; Systemic lupus erythematosus: don't know; Antiphospholipid syndrome: don't know; Patient's mother had preeclampsia: no.

Method of conception: Spontaneous;

Last period: 02 April 2023

EDD by dates: 07 January 2024

## First Trimester Ultrasound:

US machine: voluson S8. Visualisation: good.

Gestational age: 13 weeks + 4 days from dates

EDD by scan: 07 January 2024

|                          |               |   |
|--------------------------|---------------|---|
| Findings                 | Alive fetus   |   |
| Fetal heart activity     | visualised    |   |
| Fetal heart rate         | 138 bpm       | • |
| Crown-rump length (CRL)  | 71.7 mm       | • |
| Nuchal translucency (NT) | 2.5 mm        | • |
| Ductus Venosus PI        | 0.990         | • |
| Placenta                 | anterior high |   |
| Amniotic fluid           | normal        |   |
| Cord                     | 3 vessels     |   |

## Chromosomal markers:

Nasal bone: present; Tricuspid Doppler: normal.

## Fetal anatomy:

Skull/brain: appears normal; Spine: appears normal; Heart: No TR; Abdominal wall: appears normal; Stomach: visible; Bladder / Kidneys: visible; Hands: both visible; Feet: both visible.

|                         |           |                         |
|-------------------------|-----------|-------------------------|
| Uterine artery PI:      | 1.40      | equivalent to 0.890 MoM |
| Mean Arterial Pressure: | 74.6 mmHg | equivalent to 0.910 MoM |
| Endocervical length:    | 30.2 mm   |                         |

## Risks / Counselling:

Patient counselled and consent given.

Operator: DR. ANKITA VIJAYVARGIYA, FMF Id: 204664

| Condition                    | Background risk | Adjusted risk |
|------------------------------|-----------------|---------------|
| Trisomy 21                   | 1: 972          | 1: 19438      |
| Trisomy 18                   | 1: 2460         | <1: 20000     |
| Trisomy 13                   | 1: 7694         | <1: 20000     |
| Preeclampsia before 34 weeks |                 | 1: 3144       |

**DR. ANKITA VIJAYVARGIYA**  
MBBS, DMRD  
Reg. No. MP-8932

FORMER RADIOLOGIST AT:  
• FORTIS HOSPITAL, NOIDA  
• G.T.B HOSPITAL, DELHI  
• REGENCY HOSPITAL LTD, KANPUR  
• JAWAHAR LAL NEHRU CANCER HOSPITAL, BHOPAL



FMF CERTIFIED FROM  
FETAL MEDICINE FOUNDATION  
• FOR NT/B SCAN  
• FOR PRE - ECLAMPSIA SCREENING

MRI FELLOWSHIPS :  
• NANAVATI HOSPITAL, MUMBAI  
• HINDUJA HOSPITAL, MUMBAI

PATIENT'S NAME : MRS. BULBUL VERMA

REF. BY : DR. PRIYANKA TIWARI

AGE/SEX : 25 Y/F

DATE : 06.07.2023

**OBSTETRIC USG ( EARLY ANOMALY SCAN ) WITH PRE-ECLAMPSIA SCREENING**

LMP: 02.04.2023 (corrected according to dating scan)

GA (LMP) : 13wk 4d

EDD : 07.01.2024

- Single live fetus seen in the intrauterine cavity in **variable** presentation.
- Spontaneous fetal movements are seen. Fetal cardiac activity is regular and normal & is 138 beats /min.
- PLACENTA: is **grade I, high anterior & not low lying**.
- LIQUOR: is **adequate** for the period of gestation.

**Fetal morphology for gestation appears normal.**

- Cranial ossification appears normal. Midline falx is seen. Choroid plexuses are seen filling the lateral ventricles. No posterior fossa mass seen. Spine is seen as two lines. Overlying skin appears intact.
- No intrathoracic mass seen. No TR .
- Stomach bubble is seen. Bilateral renal shadows is seen. Anterior abdominal wall appears intact.
- Urinary bladder is seen, appears normal. 3 vessel cord is seen.
- All four limbs with movement are seen. Nasal bone well seen & appears normal. Nuchal translucency measures 2.5 mm ( WNL ).
- Ductus venosus shows normal spectrum with positive "a" wave ( PI ~ 0.99 ) .

**FETAL GROWTH PARAMETERS**

- |     |      |    |   |    |     |   |                    |
|-----|------|----|---|----|-----|---|--------------------|
| CRL | 71.7 | mm | ~ | 13 | wks | 3 | days of gestation. |
|-----|------|----|---|----|-----|---|--------------------|
- Estimated gestational age is **13 weeks 3 days (+/- 1 week)**. EDD by USG : 08.01.2024
  - Internal os closed. Cervical length is WNL ( 30.2 mm ).
  - Baseline screening of both uterine arteries was done & reveals mean PI of ~ 1.40 ( WNL for gestation )

**IMPRESSION:**

- Single, live, intrauterine fetus of 13 weeks 3 days +/- 1 week.
- Gross fetal morphology is within normal limits.

Follow up at 19-20 weeks for target scan for detailed fetal anomaly screening.

Declaration : I have neither detected nor disclosed the sex of the fetus to pregnant woman or to anybody. (It must be noted that detailed fetal anatomy may not always be visible due to technical difficulties related to fetal position, amniotic fluid volume, fetal movements, maternal abdominal wall thickness & tissue ecogenicity. Therefore all fetal anomalies may not be detected at every examination. Patient has been counselled about the capabilities & limitations of this examination. )

( DR. ANKITA VIJAYVARGIYA )





भारतीय विशिष्ट पहचान प्राधिकरण

Unique Identification Authority of India



पता:

द्वारा: विजय वर्मा, म. न. 446, बी-सेक्टर, ओम नगर  
अकबरपुर, हुजुर, भोपाल,  
मध्य प्रदेश - 462042

**Address:**

C/O: Vijay Verma, H. No. 446, B-Sector, Om  
Nagar Akbarpur, Huzur, Bhopal,  
Madhya Pradesh - 462042



**4699 4681 5445**

**VID : 9146 4018 3490 7142**



1947



help@uidai.gov.in



www.uidai.gov.in



भारत सरकार  
Government of India



Download Date: 29/09/2020



बुलबुल वर्मा  
Bulbul Verma  
जन्म तिथि/DOB: 10/07/1997  
महिला/ FEMALE

Issue Date: 22/09/2020

**4699 4681 5445**

VID : 9146 4018 3490 7142

मेरा **आधार**, मेरी पहचान