

NAME: MRS. VARIDHI CHAUHAN
REF BY: DR. KHANDAGALE

DATED: 31 July 2023
AGE/SEX: 37Y/F

OBSTETRIC SONOGRAPHY REPORT

LMP: 01/05/2023

GEST AGE: 13WKS 0DAYS

EDD: 05/02/2024

- Uterus is bulky and shows Single live intrauterine gestation.
- The CRL measures 6.74cm and corresponds to the gestational age of 13wks 0days.
- Fetal cardiac activity is appreciated (154bpm). Yolk sac is seen.
- Normal blood flow in ductus venosus and tricuspid valve seen.
- Nasal bone is visualized. Nuchal translucency is normal in size (0.18cm).
- Intracranial translucency appears normal.
- Calvarium is seen in present scan.
- Placenta is developing globally. No retro chorionic hematoma/collection.
- Cervix measures 3.7cm and is normal in length.
- On Doppler study, mean PI of uterine artery is 0.7 and is normal for gestation.

To rule out foetal anomalies, scan at 18-22 wks is advisable.


OPINION:

SINGLE LIVE INTRAUTERINE FOETUS WITH SONIC MATURITY OF 12-13WKS.
SONIC EDD - 05/02/2024

CRL	NT	PERCENTILE
6.74	0.18	46

(Ref - FMF calculator)

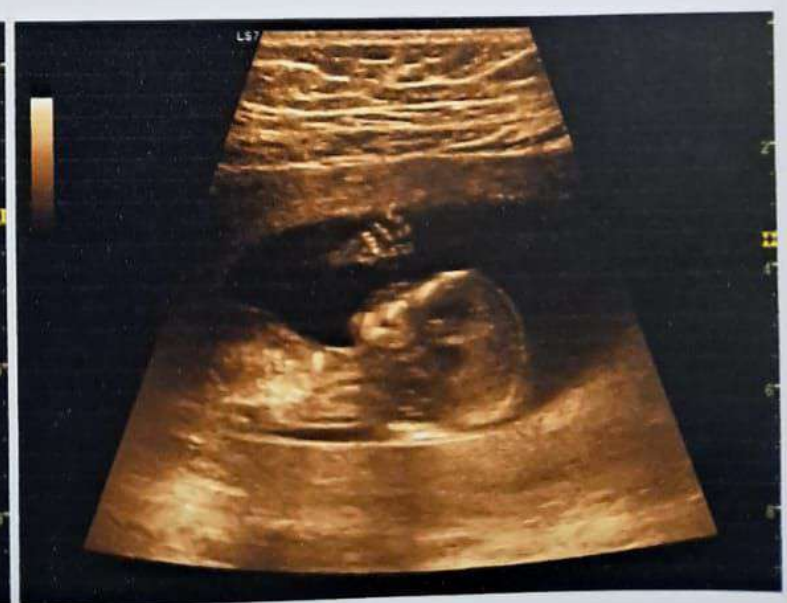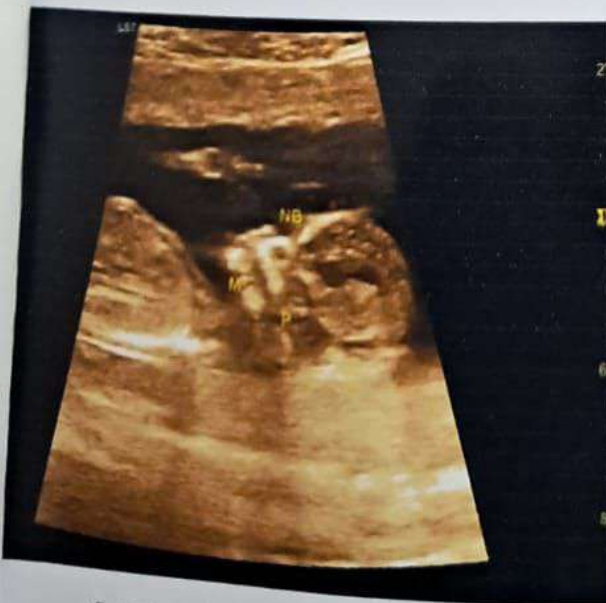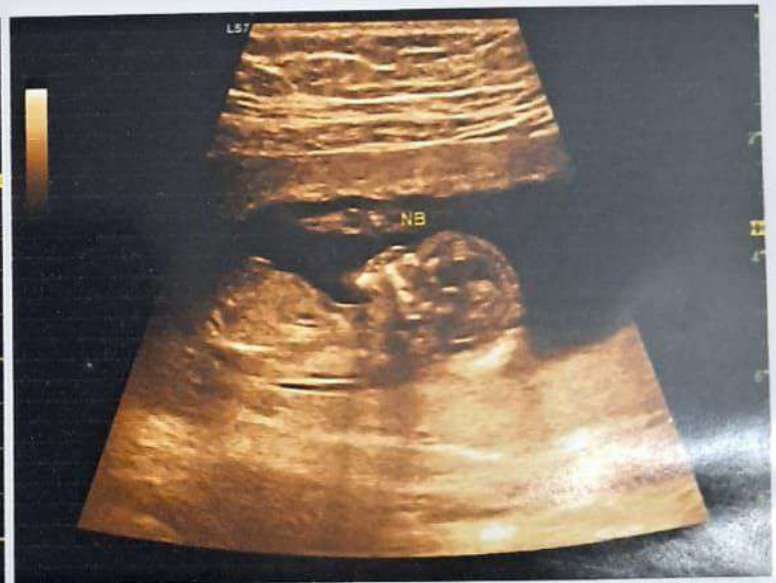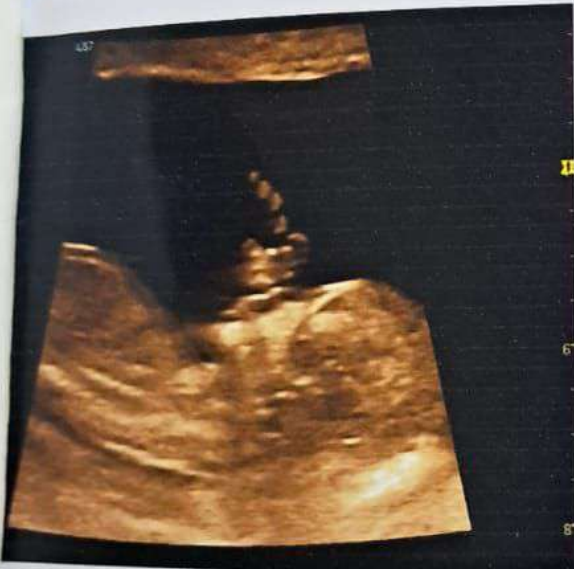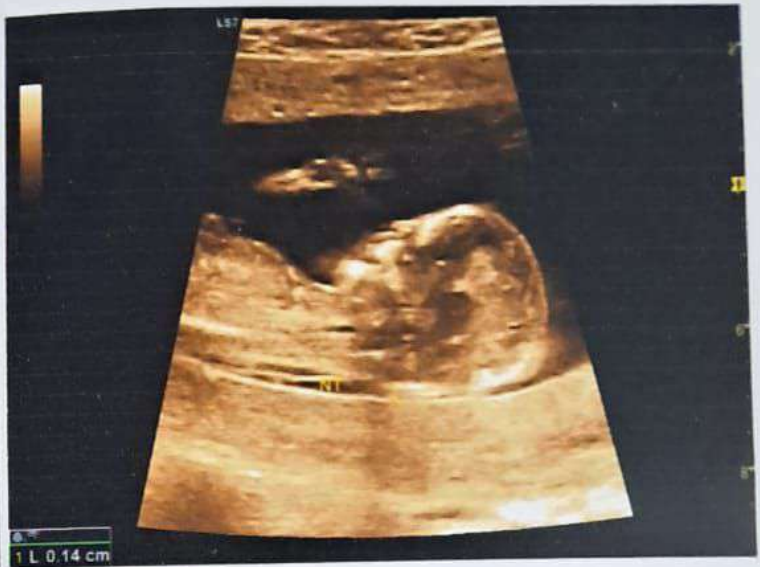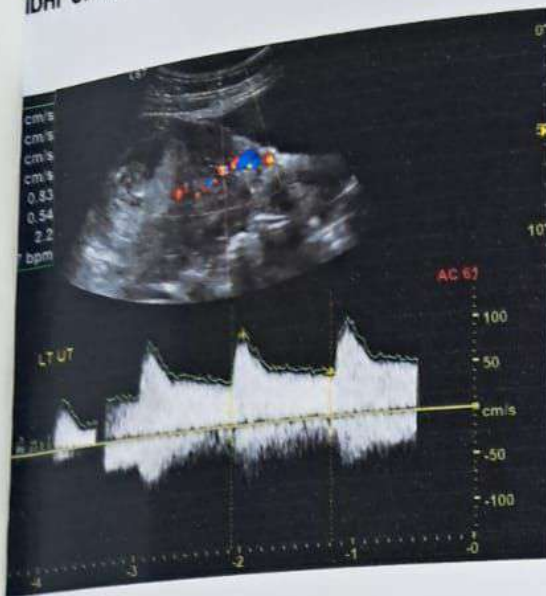
All measurements including estimated foetal weight, are subject to statistical variations.
Not all anomalies can be detected on sonography. Much of them depends on fetal position at the time of sonography.
I have neither detected nor disclosed sex of fetus to anybody in any manner.


DR. SNEHAL VAIDYA JIBHAKATE
MBBS, MD, BCFRG
(2010/04/1044)

Thanks for referral!!!

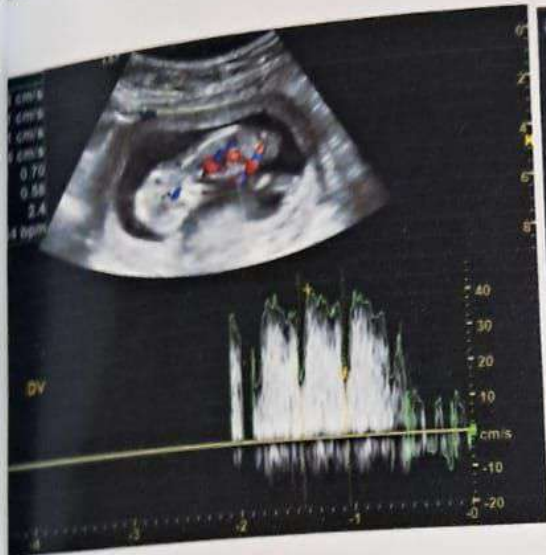Date: 31-Jul-2023

IDHI CHAUHAN



Date: 31-Jul-2023

VIDHI CHAUHAN



MAHANAGAR DIAGNOSTICS		VARISH CHAUHAN	31/07/23 12:30:11PM	ADM	310725-122925PM	36.1.1	Tx 0.1
Origin	LMP	LMP	01/05/2023	BBT	GA	13w0d	EDOLMP: 25/02/2024
Fetus A-1	AUA	13w0d-1w1d					EDOLMP: 25/02/2024
FetusPos	PLAC				Ref Physician		Page 1/1
B Mode Measurements							
CRL(Medlock)		6.74 cm	6.74		Last	13w0d	

