



**SANJEEVANI
HOSPITAL**

Reg.No. NH

संजीवनी हॉस्पिटल

डॉमा, मेटरनिटी, सर्जिकल एवं क्रिटिकल

(A Unit of Satguru Kirpa Hospital Pvt. Ltd., CIN No. U85100MH

Patient Visit Report

Patient Name : Mrs. RINITA ROY / 21 Years - Female

OPD No : OPD//6

Patient UHID : 5170

Visit Date : 03/08/

Doctor Name : Dr. PREETI BHADAURIA

Visit Time : 02:44P

Category :

Details

0 cms

Weight 39.40 kgs

Blood Pressure 91/65

89 0 bpm

SPO2 99 %

Resp. T. 97.

G/P at 20th wk
TT covered

Level II scan - w/out
single loop of cord

Inv

Ad

Quadruple
test

- Tab Orphen

- Tab Lanasol

- Masepate powder

BD 2 milk

- For chest cup apt

~ Preeti

📍 जे.जे. रोड, बरेली, जिला-रायसेन (म.प्र.) 464668

☎ +91 74898 10940, 7486 299 007 ✉ sanjeevanihospitalbar

श्रीमती रीनिता रॉय अप्र 21/16

①

TEST REQUISITION FORM (TRF)



Patient Details (PLEASE FILL IN CAPITAL LETTERS ONLY):

Name: MRS. RINITA ROY
Age: 21 Yrs: _____ Months _____ Days
Sex: Male ☐ Female ☒ Date of Birth: ☐☐☐☐☐☐☐☐☐☐
Ph: _____

Client Details:

SPP Code: _____
Customer Name: Shreyas Pathak
Customer Contact No: _____
Ref Doctor Name: Dr. Preet Bhadainia (MS)
Ref Doctor Contact No: _____

Specimen Details:

Sample Collection date:	Sample Collection Time: AM / PM	Specimen Temperature:	Sent		
			Frozen (-20°C) <input type="checkbox"/>	Refrigerator ($2-8^{\circ}\text{C}$) <input type="checkbox"/>	Ambient ($18-22^{\circ}\text{C}$) <input type="checkbox"/>
Received			Frozen (-20°C) <input type="checkbox"/>	Refrigerator ($2-8^{\circ}\text{C}$) <input type="checkbox"/>	Ambient ($18-22^{\circ}\text{C}$) <input type="checkbox"/>

Test Name / Test Code

Sample Type

SPL Barcode No

IGV
Quadruplicate Test

Serum 26015170

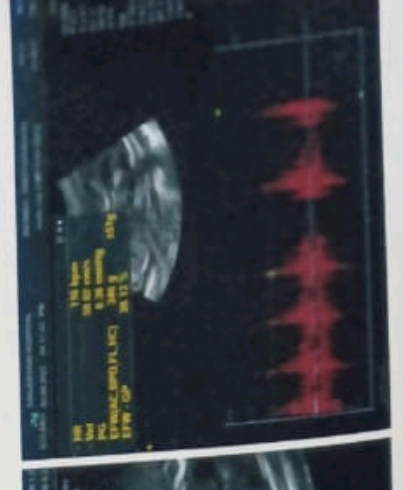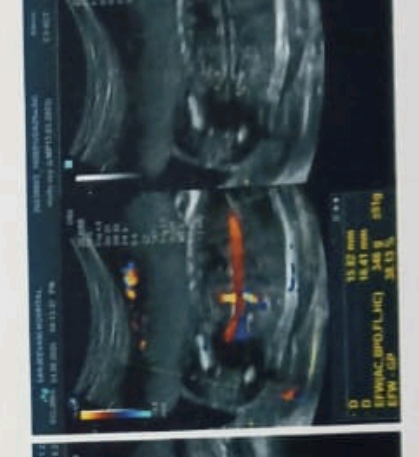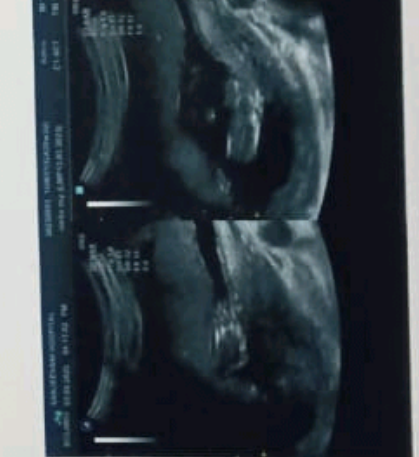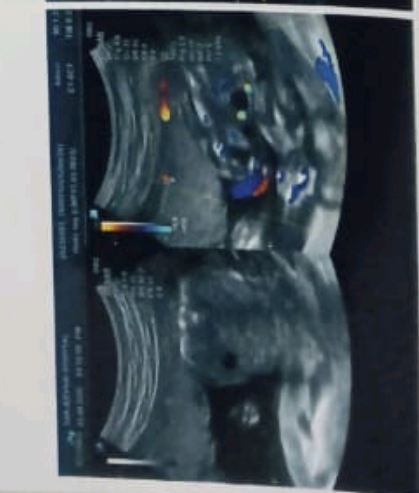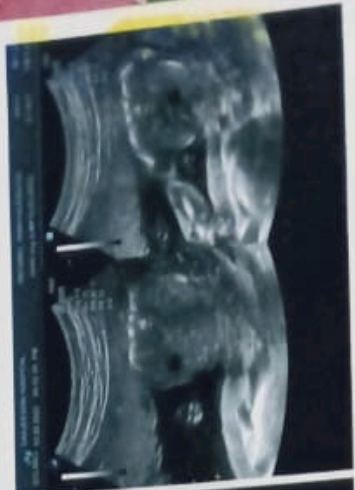
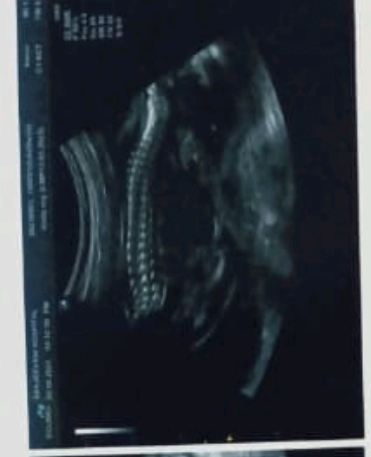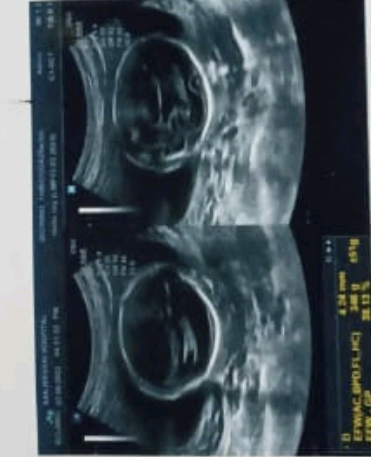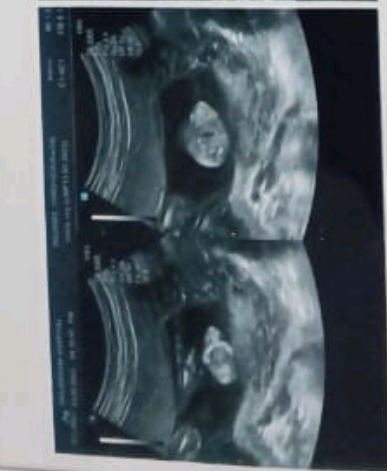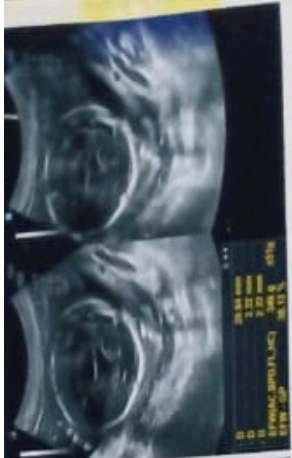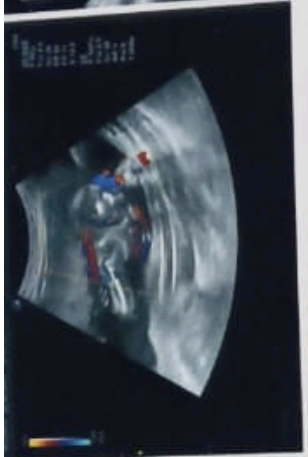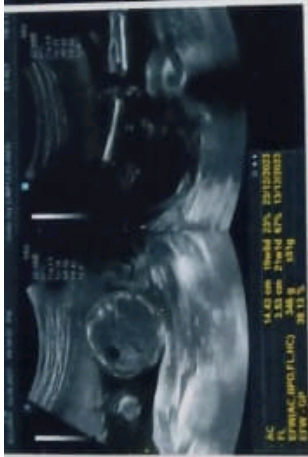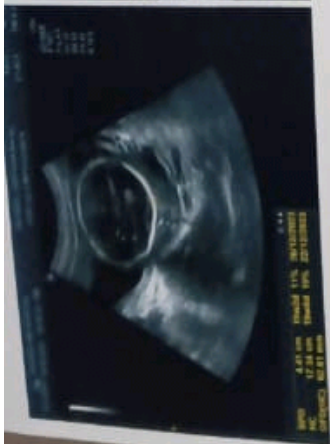Clinical History:

Dr. Preet Bhadainia (MS)

No. of Samples Received:

Received by:

Note: Attach duly filled respective forms viz. Maternal Screening form (for Dual, Triple & Quad markers), HIV consent form, Karyotyping History form, IHC form, HLA Typing form along with TRF.



- Head:** normal in size and shape.
Both lateral ventricles appear normal.
Midline echoes appear normal.
Cerebellum appears normal.
Cisterna magna normal. No sol is seen.
- Spine:** Full length of the vertebral column is visualized and appears normal.
- Neck:** No cystic lesion is visible around the fetal neck.
Nuchal fold is normal.
- Face:** Fetal face was visualized in profile and coronal scans.
Eyeballs, nose and lips appear normal.
Nasal bone was well visualized.
- Thorax:** Normal cardiac situs & position.
Four chambers view and out flow tract view appear normal.
Both lungs were visualized.
No evidence of pleural or pericardial effusion
No sol seen in thorax.
- Abdomen:** Abdominal circumference is normal.
Anterior abdominal wall appears normal.
Normal abdominal situs. Liver & gb appear normal.
Fetal stomach and bowel loops appear normal.
No ascites.
- K.U.B.:** Both kidneys appear normal in size. No pelvicalyceal dilatation.
Urinary bladder appears normal.
- Limbs:** All the four limbs are seen. The long bones appear normal.
Both the hands and feet appear normal.

No obvious structural anomaly is seen in the fetus.

I, DR KANCHAN CHOUBEY, DMRD, DNB DECLARE THAT WHILE CONDUCTING USG I HAVE NEITHER DECLARED NOR DISCLOSED THE SEX OF HER FETUS TO ANYBODY IN ANY MANNER.


DR KANCHAN CHOUBEY, DMRD, DNB



**SANJEEVANI
HOSPITAL**

संजीवनी हॉस्पिटल
ट्रॉमा, मेटर्निटी, सर्जिकल एवं क्रिटिकल केयर सेंटर
(A Unit of Satguru Kirpa Hospital Pvt. Ltd., CIN No. U85100MP2021PTC058054)

PT. NAME:	MRS RINITA ROY	AGE/SEX:	21/FEMALE
REF. BY:	DR. PREETI BHADAURIA	DATE:	03/08/2023

TARGET SCAN (ANOMALY SCAN)

CGA: 20WEEKS 3DAYS

LMP: 13/03/2023

Single live foetus in variable presentation at the time of scan.

Fetal parameter:

BPD measures	4.4cm corresponding to	19Weeks	2Days
HC measures	17.3cm corresponding to	19Weeks	6Days
AC measures	14.4cm corresponding to	19Weeks	5Days
FL measures	3.5cm corresponding to	21Weeks	1Days
Composite gestational age by Sonography		20weeks	0Days
Expected date of delivery by Sonography		21/12/2023	
Effective Fetal weight is approximately		346Gm +51 gm	

Fetal cardiac activity: is regular. Fetal heart rate is 145 beats/min.

Fetal body and limb movements are normal.

Placenta: on ANTERIOR uterine wall, lower and away from OS shows grade- 1 maturation.

Umbilical cord: 3 vessels cord is seen. Placental insertion is central. SINGLE LOOP OF CORD AROUND THE NECK IS SEEN.

Liquor: is adequate in amount.

Internal OS: is closed. Cervix is normal in length. Endocervical canal appears normal.

Impression: Intrauterine single live fetus of 20 weeks and 0 days duration with CEPHALIC presentation.

Continue...