Dr. Pooja Shrivastava

MBBS
MS (Obstetrics & Gynaecology)
Reg No. MP-4298

- Ex. Resident Gynaecologist MY Hospital Indore.
- Trained in Obstetric Ultrasonography, Wadia Hospital Mumbai.
- Ex. Consultant Gynaecologist and Sonologist Urban RCH programme J P Hospital, Bhopal.

Obstetrician & Gynaecologist

Trained in : Gynaecological Endoscopy Laparoscopy & Hysteroscopy. Obstetric & Gynaecological Ultrasonography Laparoscopic Sterlization & Family Planning

onsultation fee valid for 3 visits/15 days whichever is earlier in routine d hours only (Monday to Saturday)

Name :	**MRS. ANJU MARAN**	**Age/Sex :**	22 Years / Female	LH-A-008845	
Address :	Guradighat Misrod Bhopal	Mobile No.:	8435690086	**Date :**	12-Sep-2023

BP 109/65
Pulse 77/mt
Temp 97.2F
20T 57.1kg

Adv
Double marker test
Test

Tab Tonkinetic [illegible]
Tab Dephasion 10mg [illegible]
Tab Thyronorm 25mg [illegible]
Tab Linogen 100
Tab Triple [illegible]
Pans [illegible] 1 hr [illegible]

Rev
[illegible]

Signature

In Emergency Call : 9425005377

Email id : poojadr2003@gmail.com

LOTUS HOSPITAL
M-351, Rajharsh Colony, Nayapura, Kolar main road, Bhopal
Ph.: 0755-4093322, 6262093322, 8085441332

ivo T1 5G
ep 12, 2023, 15:02

DR. ANKITA VIJAYVARGIYA
MBBS, DMRD
Reg. No. MP-8932

FORMER RADIOLOGIST AT:
FORTIS HOSPITAL, NOIDA
G.T.B HOSPITAL, DELHI
REGENCY HOSPITAL LTD, KANPUR
JAWAHAR LAL NEHRU CANCER HOSPITAL, BHOPAL

We Care
DIAGNOSTICS & IMAGING

FMF CERTIFIED FROM
FETAL MEDICINE FOUNDATION
- FOR NT/NB SCAN
- FOR PRE - ECLAMPSIA SCREENING

MRI FELLOWSHIPS :
- NANAVATI HOSPITAL, MUMBAI
- HINDUJA HOSPITAL, MUMBAI

PATIENT'S NAME : MRS. ANJU

AGE/SEX : 21 Y/F

REF. BY : DR. POOJA SHRIVASTAVA (MBBS, MS)

DATE : 12.09.2023

OBSTETRIC USG (EARLY ANOMALY SCAN) WITH PRE-ECLAMPSIA SCREENING

LMP: 11.06.2023 GA (LMP) : 13wk 2d EDD : 17.03.2024

- Single live fetus seen in the intrauterine cavity in **variable** presentation.
- Spontaneous fetal movements are seen. Fetal cardiac activity is regular and normal & is 155 beats /min.
- PLACENTA: is **grade I, high posterior & not low lying.**
- LIQUOR: **is adequate** for the period of gestation.

Fetal morphology for gestation appears normal.

- **Cranial ossification appears normal. Midline falx is seen. Choroid plexuses are seen filling the lateral ventricles. No posterior fossa mass seen. Spine is seen as two lines. Overlying skin appears intact.**
- **No intrathoracic mass seen. No TR .**
- **Stomach bubble is seen. Bilateral renal shadows is seen. Anterior abdominal wall appears intact.**
- **Urinary bladder is seen, appears normal. 3 vessel cord is seen.**
- **All four limbs with movement are seen. Nasal bone well seen & appears normal. Nuchal transluscency measures 1.8 mm (WNL).**
- **Ductus venosus shows normal spectrum with positive "a" wave (PI ~ 1.14) .**

FETAL GROWTH PARAMETERS

CRL	69.5	mm	~	13	wks	1	days of gestation.

- Estimated gestational age is **13 weeks 1 days** (+/- 1 week). **EDD by USG** : 18.03.2024
- Internal os closed. Cervical length is WNL (31.2 mm).
- **Baseline screening of both uterine arteries was done & reveals mean PI of ~ 1.68 (WNL for gestation)**

IMPRESSION:

- **Single, live, intrauterine fetus of 13 weeks 1 days +/- 1 week.**
- **Gross fetal morphology is within normal limits.**

Follow up at 19-20 weeks for target scan for detailed fetal anomaly screening.

Declaration : I have neither detected nor disclosed the sex of the fetus to pregnant woman or to anybody. (It must be noted that detailed fetal anatomy may not always be visible due to technical difficulties related to fetal position, amniotic fluid volume, fetal movements, maternal abdominal wall thickness & tissue ecogenicity. Therefore all fetal anomalies may not be detected at every examination. Patient has been councelled about the capabilities & limitations of this examination.)

(DR. ANKITA VIJAYVARGIYA)

First Trimester Screening Report

Maran Anju

Date of birth : 27 October 2001, Examination date: 12 September 2023

Address: hno.- 28 , guradighat , misrod
BHOPAL
INDIA

Referring doctor: DR. POOJA SHRIVASTAVA (MBBS, MS)

Maternal / Pregnancy Characteristics:

Previous chromosomally abnormal child or fetus:H/o first trimester miscarriage , one .
Racial origin: South Asian (Indian, Pakistani, Bangladeshi).
Parity: 0.
Maternal weight: 56.0 kg; Height: 162.6 cm.
Smoking in this pregnancy: no; Diabetes Mellitus: no; Chronic hypertension: no; Systemic lupus erythematosus: don't know; Antiphospholipid syndrome: don't know; Patient's mother had preeclampsia: no.
Method of conception: Spontaneous;
Last period: 11 June 2023 EDD by dates: 17 March 2024

First Trimester Ultrasound:

US machine: voluson S8. Visualisation: good.
Gestational age: **13 weeks + 2 days** from dates EDD by scan: 17 March 2024

Findings	Alive fetus
Fetal heart activity	visualised
Fetal heart rate	155 bpm
Crown-rump length (CRL)	69.5 mm
Nuchal translucency (NT)	1.8 mm
Ductus Venosus PI	1.140
Placenta	posterior high
Amniotic fluid	normal
Cord	3 vessels

Chromosomal markers:

Nasal bone: present; Tricuspid Doppler: normal.

Fetal anatomy:

Skull/brain: appears normal; Spine: appears normal; Heart: No TR; Abdominal wall: appears normal; Stomach: visible; Bladder / Kidneys: visible; Hands: both visible; Feet: both visible.

Uterine artery PI:	1.68	equivalent to 1.060 MoM
Mean Arterial Pressure:	92.0 mmHg	equivalent to 1.110 MoM
Endocervical length:	31.2 mm	

Risks / Counselling:

Patient counselled and consent given.

Operator: DR. ANKITA VIJAYVARGIYA, FMF Id: 204664

Condition	*Background risk*	*Adjusted risk*
Trisomy 21	1: 1081	<1: 20000
Trisomy 18	1: 2709	<1: 20000
Trisomy 13	1: 8479	<1: 20000

First Trimester Screening Report

Preeclampsia before 34 weeks	1: 243
Fetal growth restriction before 37 weeks	**1: 124**

The background risk for aneuploidies is based on maternal age (21 years). The adjusted risk is the risk at the time of screening, calculated on the basis of the background risk and ultrasound factors (fetal nuchal translucency thickness, nasal bone, tricuspid Doppler, ductus venosus Doppler, fetal heart rate).

Risks for preeclampsia and fetal growth restriction are based on maternal demographic characteristics, medical and obstetric history, uterine artery Doppler and mean arterial pressure (MAP). The adjusted risk for PE < 34 weeks or the adjusted risk for FGR < 37 weeks is in the top 10% of the population. The patient may benefit from the prophylactic use of aspirin.
All biophysical markers are corrected as necessary according to several maternal characteristics including racial origin, weight, height, smoking, method of conception and parity.

The estimated risk is calculated by the FMF-2012 software (version 2.81) and is based on findings from extensive research coordinated by the Fetal Medicine Foundation (UK Registered charity 1037116). The risk is only valid if the ultrasound scan was performed by a sonographer who has been accredited by the Fetal Medicine Foundation and has submitted results for regular audit (see www.fetalmedicine.com).

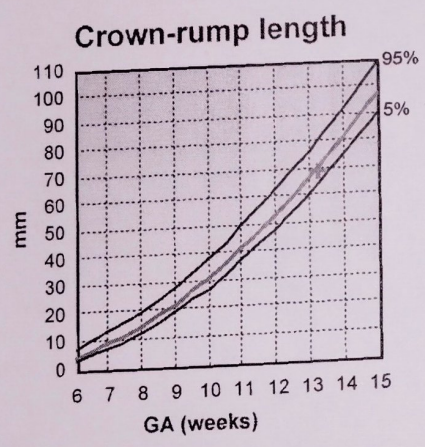

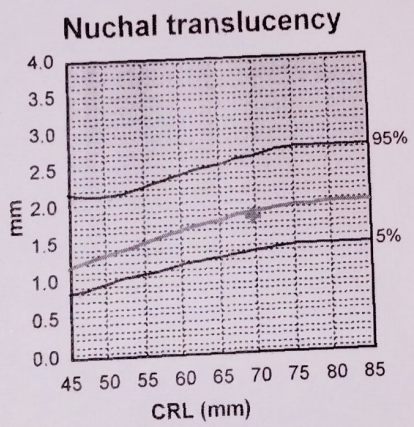

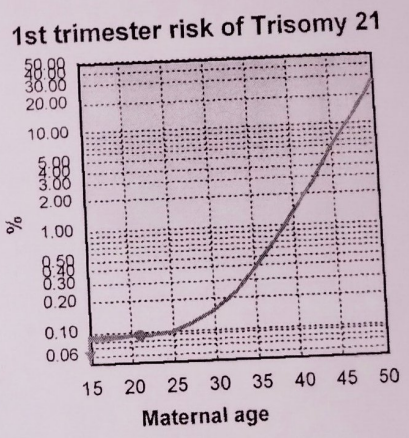

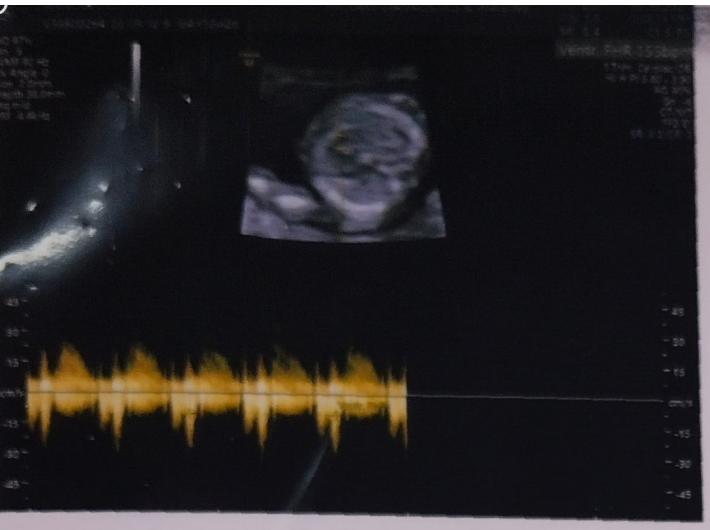

WE CARE DIAGNOSTICS & IMAGING.

WE CARE DIAGNOSTICS & IMAGING.
CRL 6.95cm
GA 13w1d 38.3%

NT 1.83mm


WE CARE DIAGNOSTICS & IMAGING.

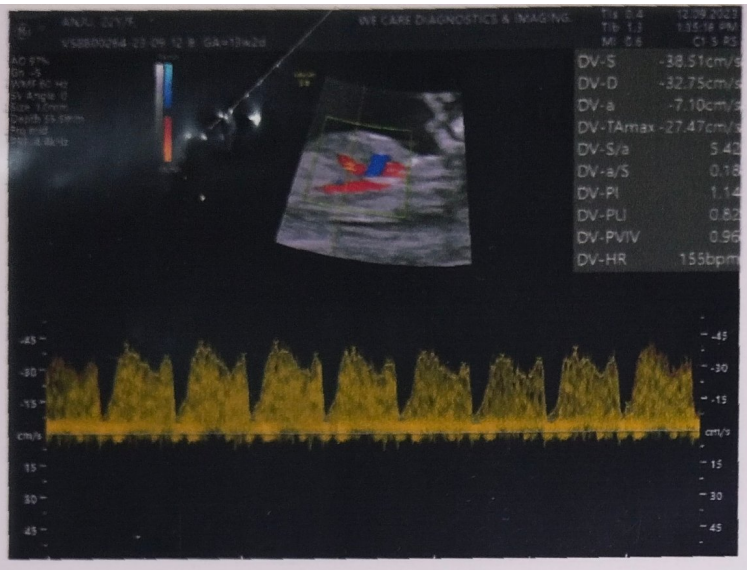
ANJU, 22Y/F
WE CARE DIAGNOSTICS & IMAGING.
VS8800264 23-09-12 8 GA=13w2d
DV-S -38.51cm/s
DV-D -32.75cm/s
DV-a -7.10cm/s
DV-TAmax -27.47cm/s
DV-S/a 5.42
DV-a/S 0.18
DV-PI 1.14
DV-PLI 0.82
DV-PVIV 0.96
DV-HR 155bpm

ANJU, 22Y/F
WE CARE DIAGNOSTICS & IMAGING.
VS8800264 23-09-12 8 GA=13w2d
1 D 3.12cm

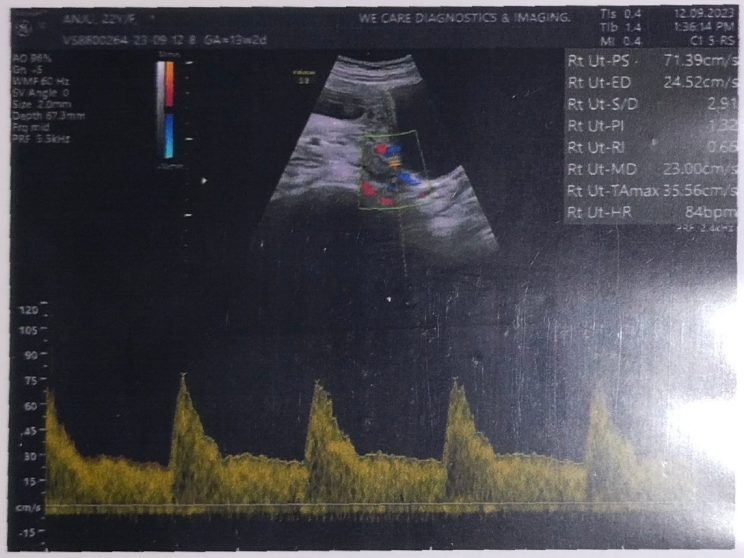
ANJU, 22Y/F
WE CARE DIAGNOSTICS & IMAGING.
VS8800264 23-09-12 8 GA=13w2d
Rt Ut-PS 71.39cm/s
Rt Ut-ED 24.52cm/s
Rt Ut-S/D 2.91
Rt Ut-PI 1.22
Rt Ut-RI 0.66
Rt Ut-MD 23.00cm/s
Rt Ut-TAmax 35.56cm/s
Rt Ut-HR 84bpm

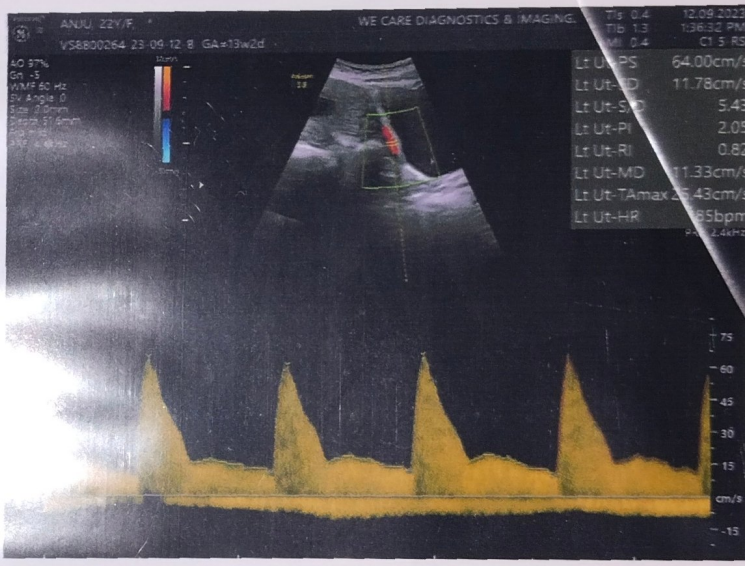
ANJU, 22Y/F
WE CARE DIAGNOSTICS & IMAGING.
VS8800264 23-09-12 8 GA=13w2d
Lt Ut-PS 64.00cm/s
Lt Ut-ED 11.78cm/s
Lt Ut-S/D 5.43
Lt Ut-PI 2.09
Lt Ut-RI 0.82
Lt Ut-MD 11.33cm/s
Lt Ut-TAmax 25.43cm/s
Lt Ut-HR 85bpm

ANJU, 22Y/F
WE CARE DIAGNOSTICS & IMAGING.
VS8800264 23-09-12 8 GA=13w2d

ANJU, 22Y/F
WE CARE DIAGNOSTICS & IMAGING.
VS8800264 23-09-12 8 GA=13w2d