



GeneTech
Genetics and Genomics

Call for pick-up or transportation
98480-41127, 040-68168700

PRENATAL SCREENING Test Requisition Form

Physician: Dr. Padma MBBS obs & Gynaecology
Hospital/Clinic: Padma Hospital

First Trimester (10-14 wks)

Double Marker *

Second Trimester (15-21 wks)

☐ Triple Screen Marker

☐ Quadruple Screen

☐ Penta Screen *

Patient Details

Patient Name: Chandratala Age: 25/F DOB: Weight:
Mobile No: 836703299 E-Mail:
Address: NLG IDDM: ☐ Yes ☐ No

Pregnancy Details

Conception Type: ☒ Normal ☐ IUI ☐ IVF ☐ ICSI
LMP Date: 17 06 23

Other Details

Family History of Down Syndrome: ☐ Yes ☒ No
Family History of Neural Tube Defect: ☐ Yes ☒ No
Maternal Valporate therapy: ☐ Yes ☒ No

Additional Notes: 2 Times miss
courage (abortions)

Central Lab Address: 8-2-293/174/A25, Opposite KBR Park, Road No. 14
Banjara Hills, Hyderabad, Telangana 500034

Scan Details

Scan Date: 13 09 23 Gestation (on Scan): 12 Weeks 4 Days

Pregnancy: ☒ Single ☐ Twin ☐ Triplet **CRL (mm): 63.0

**Nasal Bone: ☐ Normal ☐ Absent ☐ Hypoplastic **NT (mm): 1.6

*Mean Arterial Pressure (mmHg): EDD: 23 08 24

*Mean Uterine Artery PI Left: Right: For twins, use Additional Notes section.

Sample Data

Sample Type: ☒ Blood ☐ Serum

Volume (ml): 4.0 ml

Collection Date-Time: 13 09 23 04 10 ☐ AM ☒ PM



Phone: Hosp: 08682-230756
Cell: 6300650008, 9989763594

PADMA HOSPITAL

Opp: Ravi Medical Hall Lane, Prakasham Bazar, Bottuguda, NALGONDA.

Dr. Mrs. PADMA

M.B.B.S., M.S.

Obstetrician & Gynaecologist

Assistant Professor

(OBG Dept., Nalgonda Govt. Hospital)

డా. శ్రీమతి పద్మ

జనన శిశు వైద్యం, గర్భ వైద్యం

జీల వైద్య నిపుణులు

Regd No 60113

♦ 24 గంటలు వైద్య సౌకర్యం కలదు

Name: Smt. Chandrakala

Vill. Uttapally

Age: 27y Date: 12/9/22

Valid up to: 29/9/22

12.10.2022

G₃A₂ 4mm

Wt. : 42.7kg

No complaint

Temp. :

P.R. : 108b/min

of 100b/min

B.P. : 100/60mm/Hg

Amniotic

SPO₂ : 99%

per

1A5A

Adv
Niscan -
Double marker test
Nuchal bone. Canot Examine

11/10

1) Tab. Ecosprin 150mg (15)

oo - 1 -

2) Tab. Crestofit 200mg (30)

po - Bd

3) Tab. pregnacare (15)

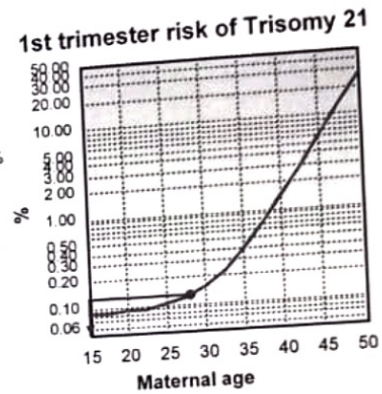
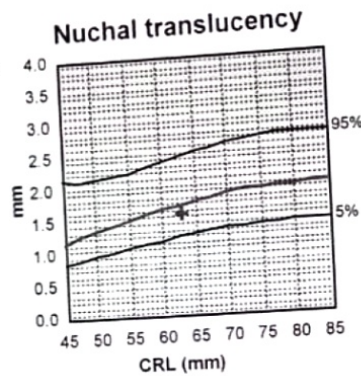
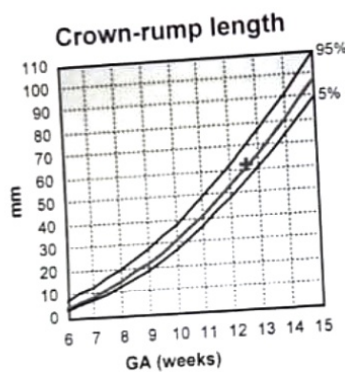
oo - 1 -

Kalpana Fetal Medicine and Scan Center

1st Trimester Screening Report
Protecting the Precious...
The background risk for aneuploidies is based on maternal age (28 years). The adjusted risk is the risk at the time of screening, calculated on the basis of the background risk and ultrasound factors (fetal nuchal translucency thickness, fetal heart rate).

Risks for preeclampsia and fetal growth restriction are based on maternal demographic characteristics, medical and obstetric history and uterine artery Doppler.
All biophysical markers are corrected as necessary according to several maternal characteristics including racial origin, weight, height, smoking, method of conception and parity.

The estimated risk is calculated by the FMF-2012 software (version 2.81) and is based on findings from extensive research coordinated by the Fetal Medicine Foundation (UK Registered charity 1037116). The risk is only valid if the ultrasound scan was performed by a sonographer who has been accredited by the Fetal Medicine Foundation and has submitted results for regular audit (see www.fetalmedicine.com).



Comments

Single live intra uterine fetus corresponding to 12 weeks 4 days.

Down syndrome screen negative based on NT scan.

NASAL BONE CAN NOT EXAMINE.

Suggested **DOUBLE MARKER**.

Suggested **EARLY TIFFA SCAN** at 16 weeks. (OCT 8TH TO 11TH)

I, Dr. L. Kalpana reddy, declared that while conducting ultrasonography / imaging scanning on Mrs. CHANDRAKALA, I have neither detected nor disclosed the sex of fetus to any body in any manner.

DR. L. KALPANA REDDY
FETAL MEDICINE CONSULTANT

MRS CHANDRAKALA

Date of birth : 05 June 1995, Examination date: 13 September 2023

Address: NALGONDA

Hospital no.: KFC11044

Mobile phone: 8367032992

Referring doctor: PADMA

Maternal / Pregnancy Characteristics:

Racial origin: South Asian (Indian, Pakistani, Bangladeshi).

Parity: 0.

Maternal weight: 42.0 kg; Height: 152.0 cm.

Smoking in this pregnancy: no; Diabetes Mellitus: no; Chronic hypertension: no; Systemic lupus erythematosus: no; Antiphospholipid syndrome: no; Patient's mother had preeclampsia: no.

Method of conception: Spontaneous;

Last period: 17 June 2023

EDD by dates: 23 March 2024

First Trimester Ultrasound:

US machine: E 6. Visualisation: good.

Gestational age: 12 weeks + 4 days from dates

EDD by scan: 23 March 2024

Findings	Alive fetus
Fetal heart activity	visualised
Fetal heart rate	162 bpm
Crown-rump length (CRL)	63.0 mm
Nuchal translucency (NT)	1.6 mm
Biparietal diameter (BPD)	23.0 mm
Ductus Venosus PI	1.000
Placenta	anterior low
Amniotic fluid	normal

Chromosomal markers:

Nasal bone: can not examine; Tricuspid Doppler: normal.

Fetal anatomy:

Skull/brain: appears normal; Spine: appears normal; Heart: Appears normal; Abdominal wall: appears normal; Stomach: visible; Bladder / Kidneys: visible; Hands: both visible; Feet: both visible.

Uterine artery PI: 0.75 equivalent to 0.440 MoM

Endocervical length: 32.0 mm

Risks / Counselling:

Patient counselled and consent given.

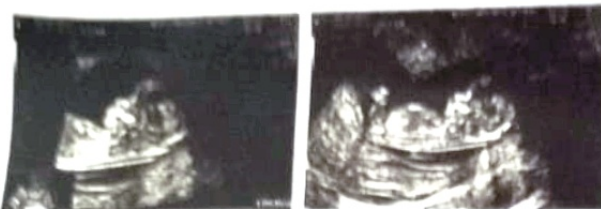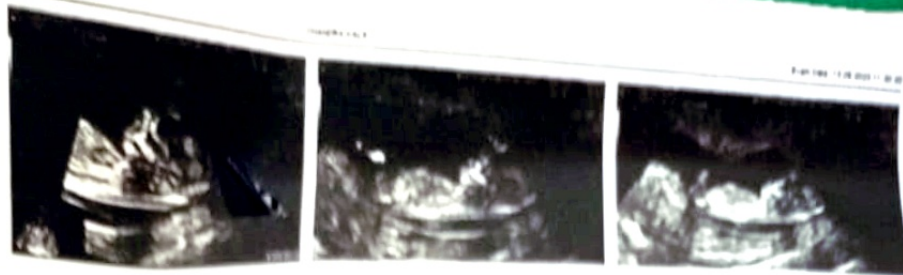Operator: Lekkala Kalpana, FMF Id: 173593

Condition	Background risk	Adjusted risk
Trisomy 21	1: 782	1: 3909
Trisomy 18	1: 1901	1: 5762
Trisomy 13	1: 5967	<1: 20000
Preeclampsia before 34 weeks		1: 2898
Fetal growth restriction before 37 weeks		1: 128

Page 1 of 2 printed on 13 September 2023 - MRS CHANDRAKALA examined on 13 September

8-2-71/1/ఎ, గ్రీన్‌లాండ్ హాస్పిటల్ ఎదురుగా, డాక్టర్స్ కాలనీ, నల్లగొండ - 508 001. తెలంగాణ

For Appointment : +91 8522 856 854 | +91 9704 234 016

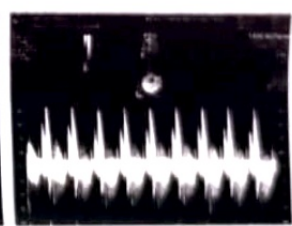
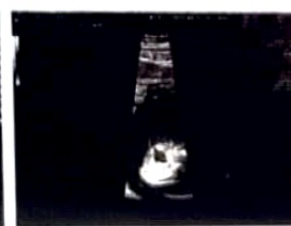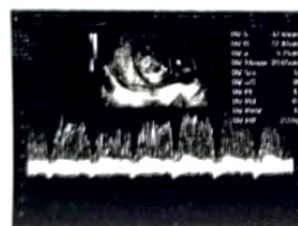
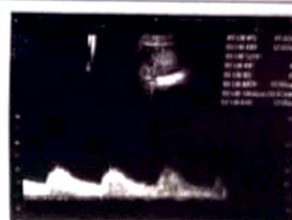
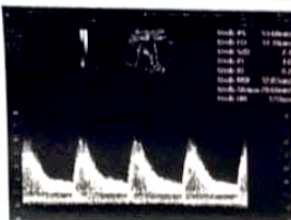

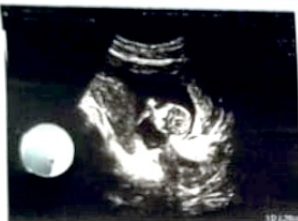
Medicine

September 20

ital no.: K

e phone: 8



S:
eshi).

io; Chronic hype
; Patient's moth

dates



normal

Chromosomal markers:

Nasal bone: can not examine; Tricuspid Doppler: normal

Fetal anatomy:

Skull/brain: appears normal; Spine: appears normal; Head: appears normal; Stomach: visible; Bladder / Kidneys: visible;

Uterine artery PI:

0.75

Endocervical length:

32.0 mm

equivalent to 0.440

Risks / Counsel: