

PUGALIA DIAGNOSTIC CENTRE

SHIVAM TOWER, Satnami nagar ,besides Relience office,Old Bhandara Road
,Wardhaman nagar , Nagpur-8
A unit of Pugalia Nursing Home

DR NAVEEN PUGALIA MBBS MD (Radio-Diagnosis)

Consultant Radiologist and Sonologist, Reg.No. 076125 Mobile :9822643999
Ex-Lecturer :Sir J J Group Of Hospitals & GMC Mumbai

Ex-Registrar : Lilavati Hospital & Research Centre, Mumbai, Bombay Hospital & Research Centre, Mumbai

Name: MRS PRIYANKA NAGOSE Age: Sex:F Date: 28-09-2023

Ref.By: DR. AKASH DANGE BAMS

LMP 01-07-23 LMP GA 12 weeks 5 days LMP EDD 06-04-24

USG OBSTETRICS NT SCAN

A Single live intrauterine foetus seen .

Fetal movements and Cardiac pulsations are well appreciated

CRL measures 6.2, BPD 1.9 cm corresponding with gestational age of
12 Weeks 6 days

Nuchal Thickness measures 1.0 mm and appears normal

Intracranial translucency appears normal

Nasal bone and retranasal triangle seen

Bladder and stomach bubble seen

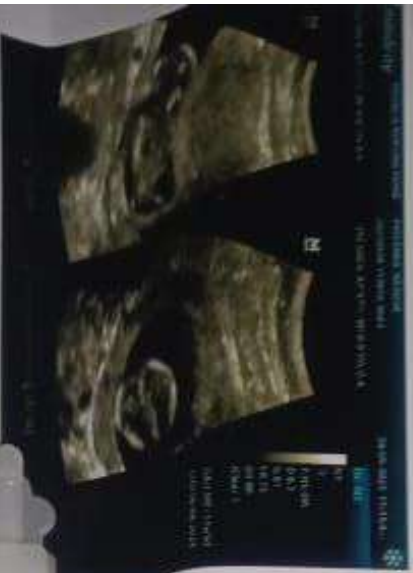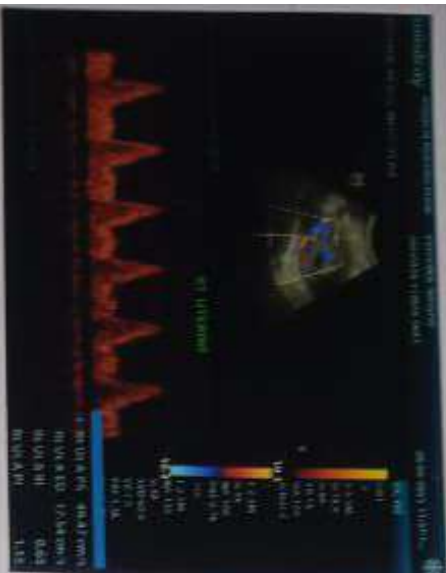
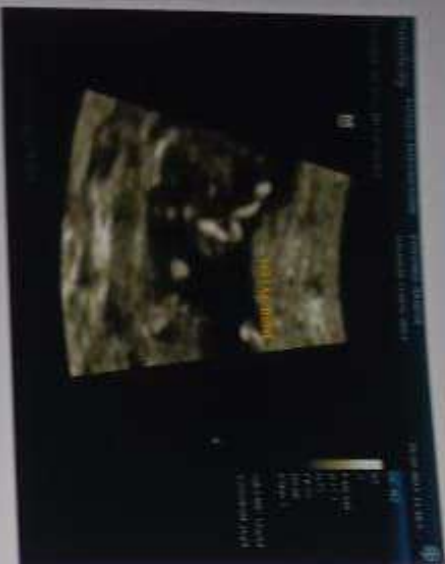All four limbs with spontaneous movements seen

Flow across Ductus Venosus and tricuspid valve appears normal

Both uterine arteries show normal diastolic flow
Right Uterine artery PI 1.15 Left Uterine artery PI 2.15 Mean PI 1.65
Percentile 55 (Ref percentile: fetal medicine Barcelona)

EDD- 05-04-24

PTO



Measurement: 1.00 cm

Area: 1.00 cm²

Volume: 1.00 cm³

Flow: 1.00 cm³/min

Velocity: 1.00 cm/s

Pressure: 1.00 mmHg

Resistance: 1.00 mmHg/cm³/min

Compliance: 1.00 cm³/mmHg

Stiffness: 1.00 mmHg/cm³

Flow: 1.00 cm³/min

Velocity: 1.00 cm/s

Pressure: 1.00 mmHg

Resistance: 1.00 mmHg/cm³/min

Compliance: 1.00 cm³/mmHg

Stiffness: 1.00 mmHg/cm³

