

SHIVNANDAN HOSPITAL & TEST TUBE BABY CENTER

Deshpande Estate, Opposite M.E.S. English Medium School,
Indapur Road, Baramati, Dist. Pune-413102 Ph. 9158992829, 9607992829



Dr. Tushar Govind Gadade

M.B.B.S. MS
(Obstetric & Gynecology)
(Endoscopy & I.V.F. Consultant)

Dr. Supriya Tushar Gadade

M.B.B.S. D.A.
Anaesthetist

Date:- 13/10/2023

ULTRA SONOGRAPHY REPORT

Patient Name:- Shendkar Pooja Tushar

OPD No:- 20222191

Sex:- Female

AGE:- 23

Referred By Dr. Tushar Gadade

L.M.P:- 11/7/2023

E.D.D.BY L.M.P:- 16/4/2024

G.A.BY L.M.P:- 13 Weeks and 3 Days

Indication Detection And Viability

Is Gravid And Bulky Showing Single Intrauterine gestational sac with surrounding good decidual reaction.

A single normal live fetus with CRL measuring 67 mm corresponding to 13 wks 0 days +/- 7 days of gestation.

Fetal Cardiac activity Is Well Seen

No retrochorionic haematoma.

Both OVARIES are normal.

Cervical Length Is Adequate

Internal OS is Closed

EDD by calculated gestational age 19/4/2024

IMPRESSION

Single live intrauterine pregnancy of 13 wks 3days

good decidual reaction

interval growth satisfactory

NT scan normal

nasal bone seen 4.0 mm

NT 1.1 mm

Adv.: F/U for Target scan at 20 wks

Comments: This sonography is mainly done for screening purpose . All congenital anomalies are not detected on sonography. Some May remain undetected for some cases second opinion is needed for expert sonologist. All measurements subject to statical variations. Because of foetal position during sonography some foetal part may get hidden and may not be seen. I have nether detected nor disclosed the sex of her foetus to anybody in manner.


Tush
Dr. Tushar Gadade M.B.B.S.M.S

मी Shendkar Pooja Tushar

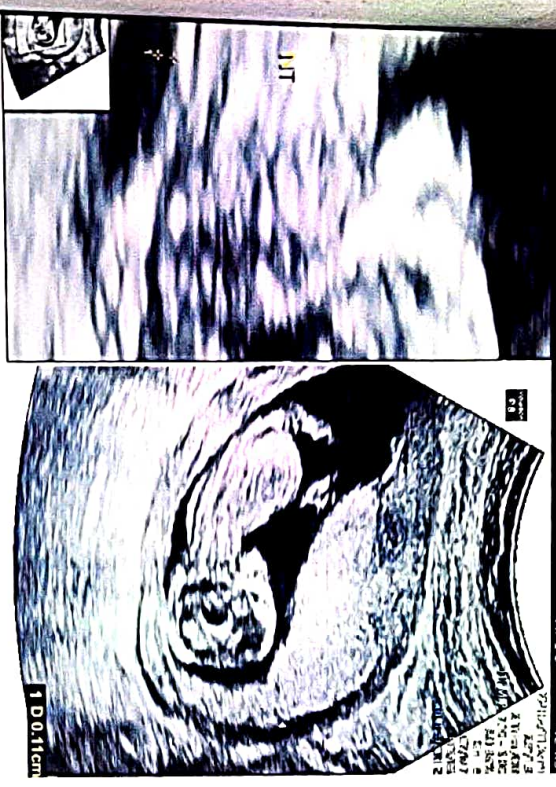
असे घोषित करते कि अल्ट्रा सोनोग्राफी प्रतिमा स्कॅनिंग करून मी माझ्या गर्भाचे लिंग जाणून घेऊ इच्छित नाही.

I Shendkar Pooja Tushar declare that my undergoing ultrasonography / image scanning ect . I do not want to know that sex of my foetus

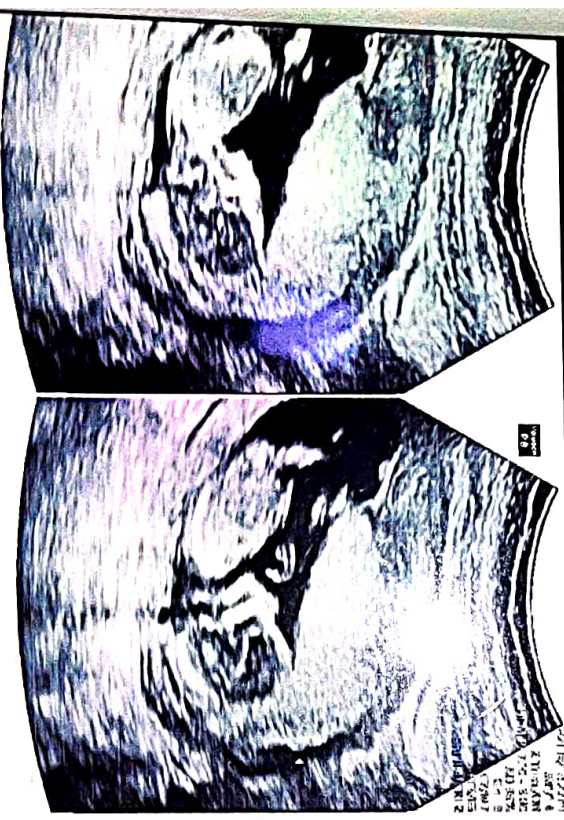
Save Girl Child



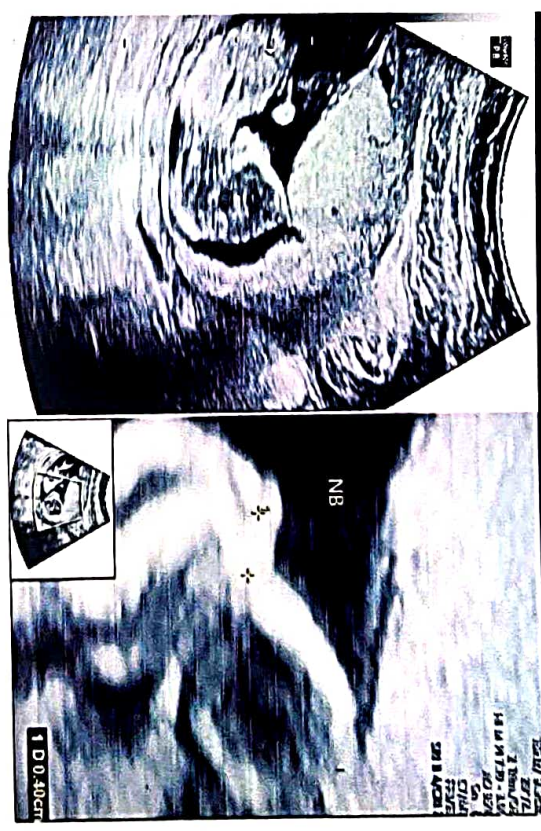
13.10.2023 11:36:58 AM
Tib-01 11:36:58 AM
MI 10 AC-RS



SHIVNANDAN HOSPITAL, BARAMATI
Tib-01 13.10.2023
Tib-01 11:38:10 AM
MI 10 AC-RS



SHIVNANDAN HOSPITAL, BARAMATI
Tib-01 11:37:46 AM
MI 10 AC-RS



SHIVNANDAN HOSPITAL, BARAMATI
Date of Exam: 13.10.2023 Page: 2/22
Event Type: SON Female

Name: SHENDKAR, POOLATUSHAR
Pat ID: VP8802791-23-10-13-2
DOR:
Ref: Phys:
Sonogr:
Indication:
LMP: 11.07.2023 GALLMP: 13w3d EDD(LMP): 16.04.2024 G: 1 Ab
DOC: GALLUA 13w0d EDD(GALLUA): 19.04.2024 P: Ec

UTW/Head/Doc	Value	Range	Age	Range	Gr	Weeks	Age
AC/BPD/FL/HC						N/A	
20 Measurements	AWA U/W	Value	mL	mL	mL	Gr	Age
CRL (Hodloch)	<input checked="" type="checkbox"/>	6.75 cm	6.75			21.9%	13w0d