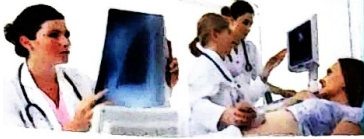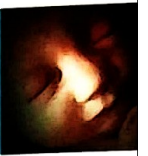


SUNITA DIAGNOSTIC CENTER



- ▶ Anomaly Scan (Level II) Obstetric Sonography
- ▶ Computerised Digital X-Ray
- ▶ Whole Body Colour Doppler & Sonography, USG Guided Interventional Procedures.
- ▶ 3D/4D Obstetric Scan



Name: Mrs. SNEHAL SAGAR LOKARE

Ref.By: Dr. TEJAS GUNDEWR,

Study: NT scan

Age: 24 Years

Sex: Female

Date: 30-Oct-23

NT SCAN

LMP 12-Jul-23 EDD 17-Apr-24 GA BY LMP- 15 weeks 5 days

Real time ultrasonography of the gravid uterus has been performed.

The uterus is enlarged in size and shows well defined gestational sac within. The fetal cardiac pulsation is well visualized.

Fetal Aneuploidy markers: Nasal bone seen. Ductus venosus shows normal waveform. There is no reversal of 'a' wave. No regurgitation seen across the Tricuspid valve.

Fetal Anatomy: Skull bones are well ossified, no distortion skull shape. Both lateral ventricles and choroid plexus seen.

Stomach bubble and urinary bladder are well seen. All four limbs are seen. **Placenta is developing Anteriorly and just touching internal os.** Grade 0. The internal os is closed. The cervix is 3 cm in length. **FHR= 168bpm.**

The gestational parameters are as follows:

Measurement	GA			
Crown Rump Length	7.21 cm	13 weeks 3 days		
Biparietal Diameter	2.28 cm	13 weeks 0 days		
Head Circumference	8.30 cm	13 weeks 4 days		
Average Ultrasound Age	13 weeks 2 days	04-May-24		
DUCTUS VENOSUS PI	0.98			
NT	1.3 mm			
Artery	P.I.	R.I.	S/D	Diastolic notch
RIGHT UTERINE ARTERY	1.97	0.80	5.09	Absent
LEFT UTERINE ARTERY	2.06	0.80	5.06	present
Mean Uterine Artery PI	2.02			

IMPRESSION: SINGLE, LIVE INTRAUTERINE PREGNANCY OF 13 weeks 2 days WITH EDD 05-05-24(BY CRL).

Suggest Anomaly scan around 18 to 20 weeks. This is not dedicated fetal anomaly scan, all foetal anomalies may not necessarily be detected at every examination.

Dr. Suhas Sambhaji

Anantkavalas

MBBS, DMRE

Consultant Radiologist And

Sonologist

📍 Sahayog Society, Solapur Road, **TEMBURNI**, Tal. Madha, Dist. Solapur. Mob. 8424351970

📍 Station Road, Behind Market Yard, Infront Shah Jewellers, **MODNIMB**, Tal. Madha, Dist. Solapur.

Note : Investigations have their own limitations, Solitary Pathological or Radiological & other investigations never confirm the final diagnosis of disease. They only help in diagnosing the disease in correlation to clinical symptoms and other related tests. Please interpret accordingly.