

PATIENT'S PARTICULARS: Ms. Jenima Yesmin

Age: 24 Yrs/Female.

DATE: 06th November, 2023

Regd. No: OCS- 111446

REFD. BY: Dr. Ira Biswas. MBBS,MS.

USG OF EARLY PREGNANCY (11 – 13 weeks):

LMP: 13 – 08 – 2023.

Single live foetus is seen in variable presentation. Maternal cervix is normal in length (5 cm). Internal os is closed.

The placenta is anterior. Liquor volume is adequate.

The markers for chromosomal defects are absent.

Nuchal fold thickness is 1.1 mm. Nasal bone present. Facial angle is normal.

The head, heart, spine, stomach, liver, kidney and urinary bladder appear normal. The limbs are normal.

Fetal parameters are as follows.....

CRL = 51.9 mm.

GSD = 52.6 mm.


GA by LMP = 12 weeks 1 day.

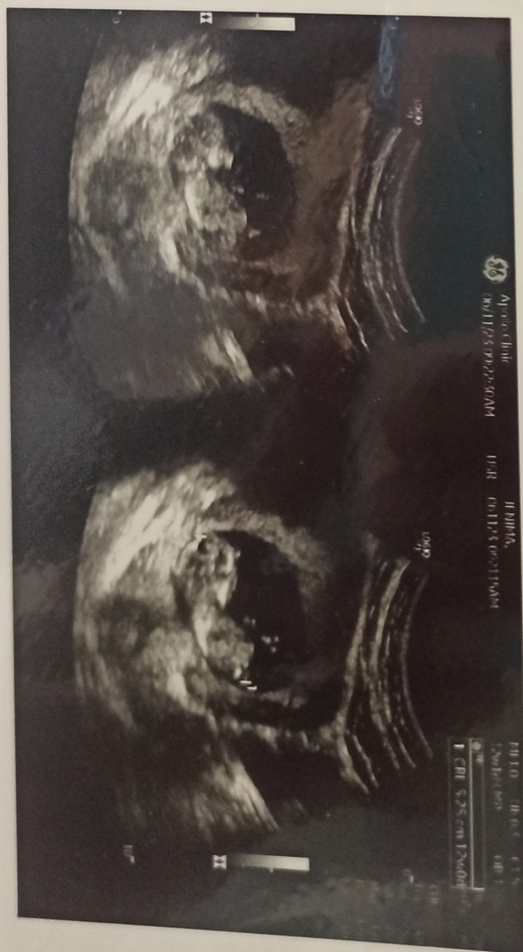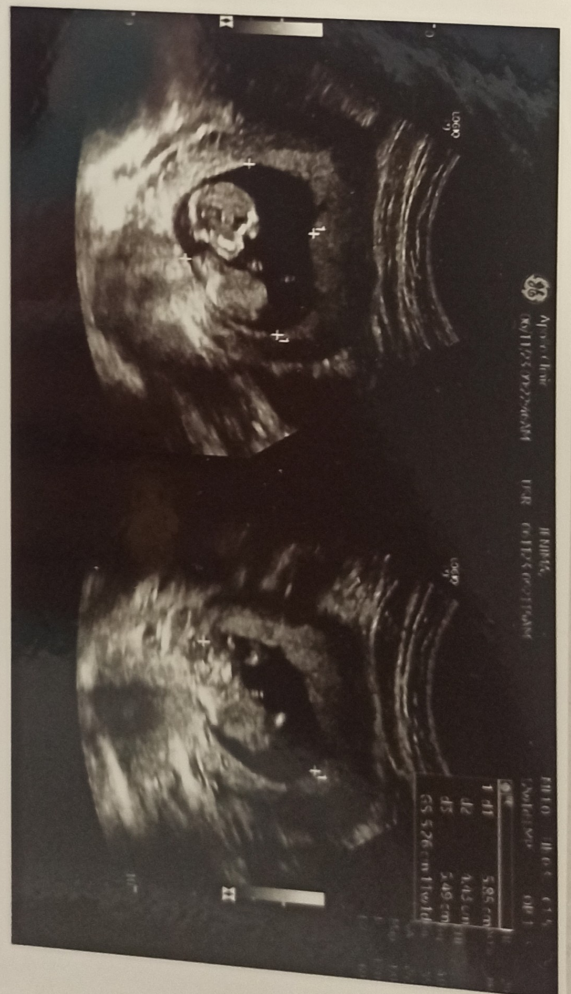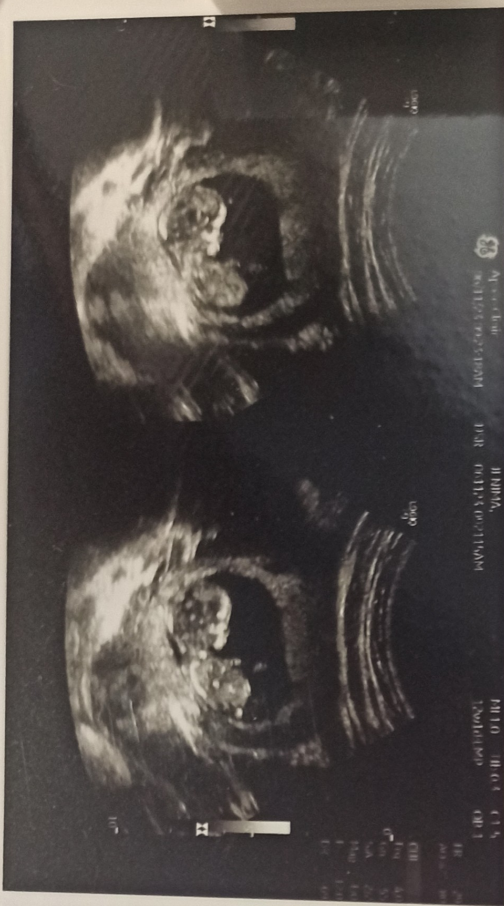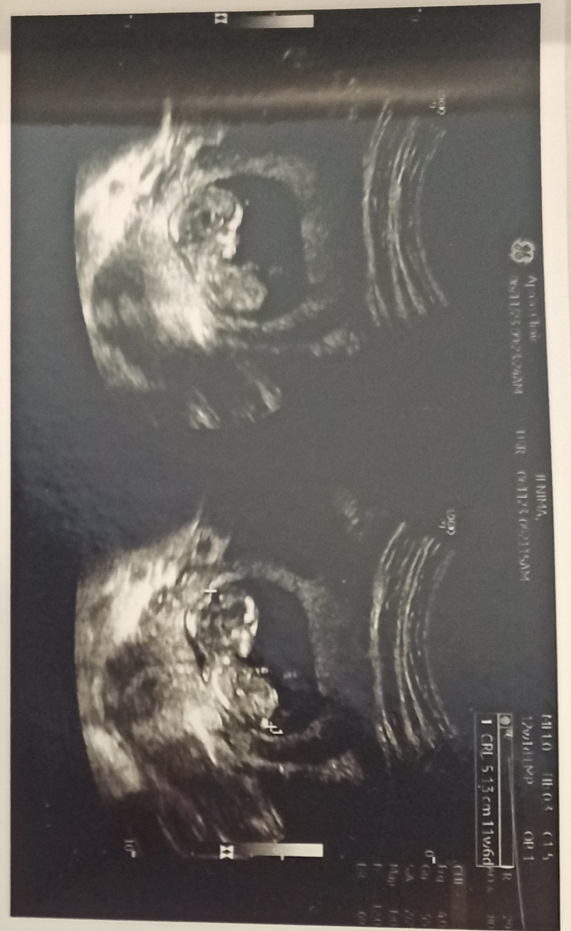
EDD by LMP = 19 – 05 – 2024.

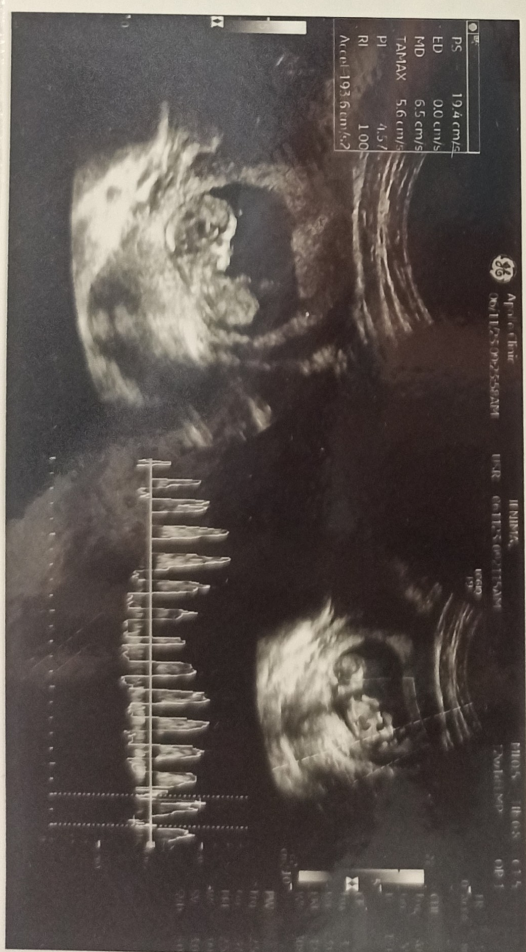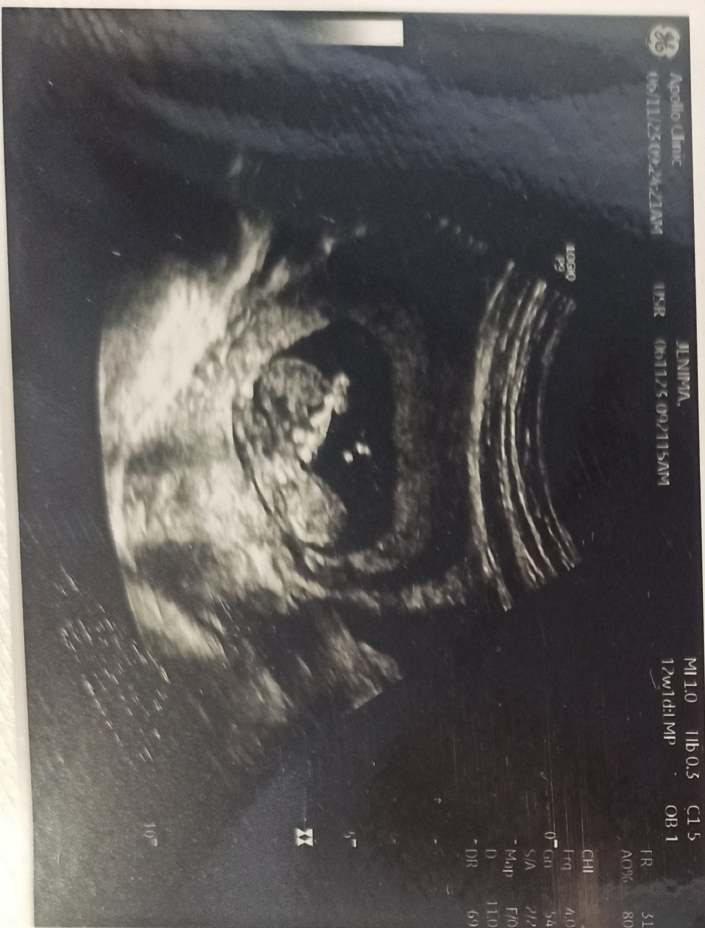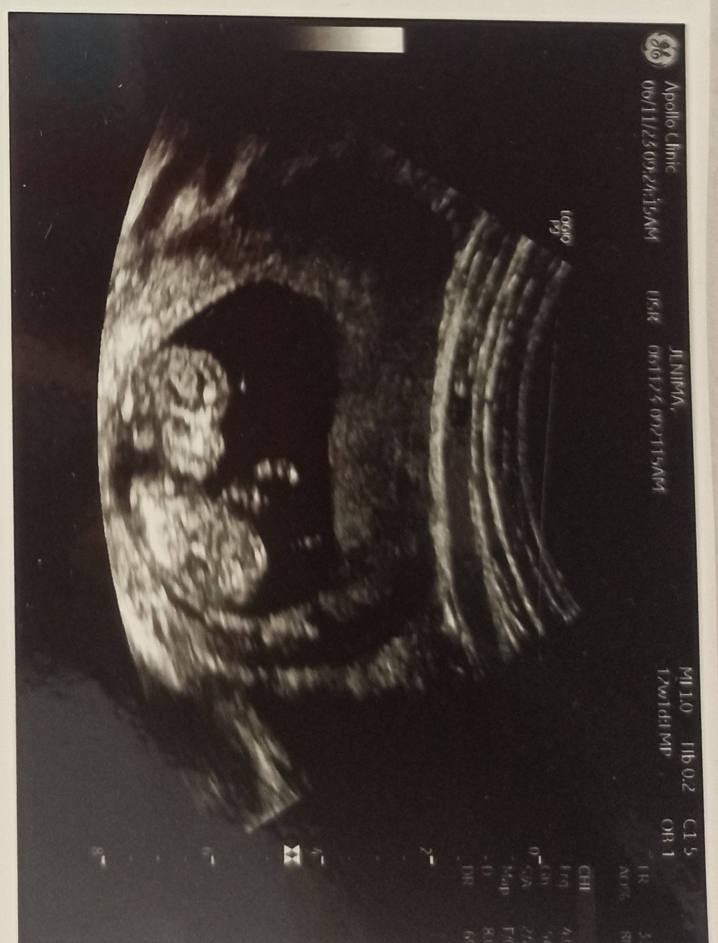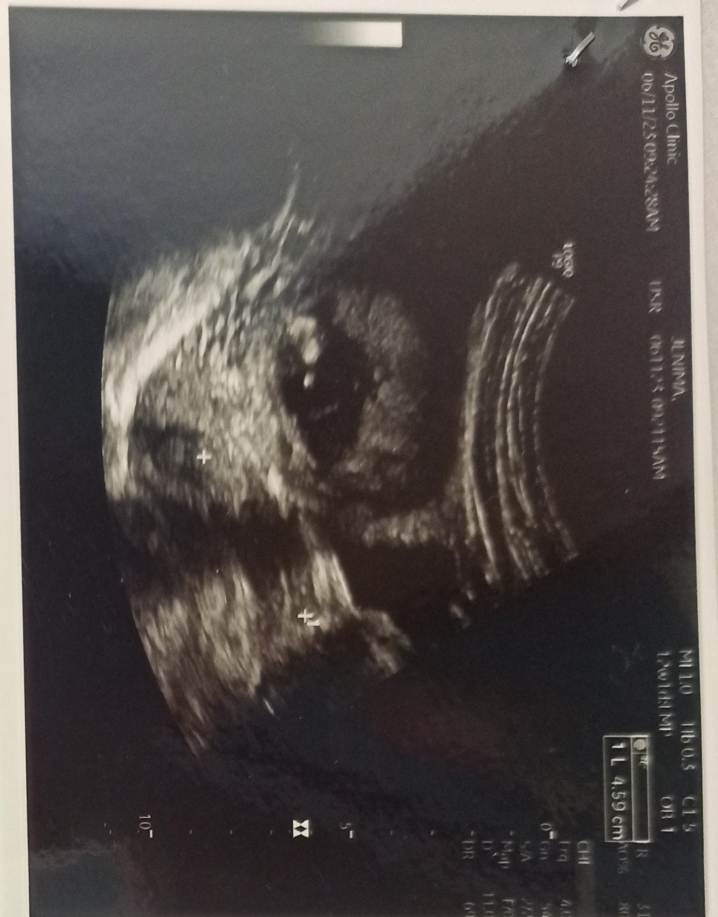EDD by USG = 23 – 05 – 2024.

Somatic Size = 11 weeks 4 days.

Doppler study: Fetal heart rate is 170 BPM. Flow in the ductus venosus and tricuspid valve is normal. The uterine and umbilical artery flow is normal. Doppler screening for prediction of PIH do not reveal any positive sign.


Dr. Pradeep Hatimora, MD (AIIMS)
Consultant Radiologist







Apollo Clinic

06/11/23 09:25:20AM

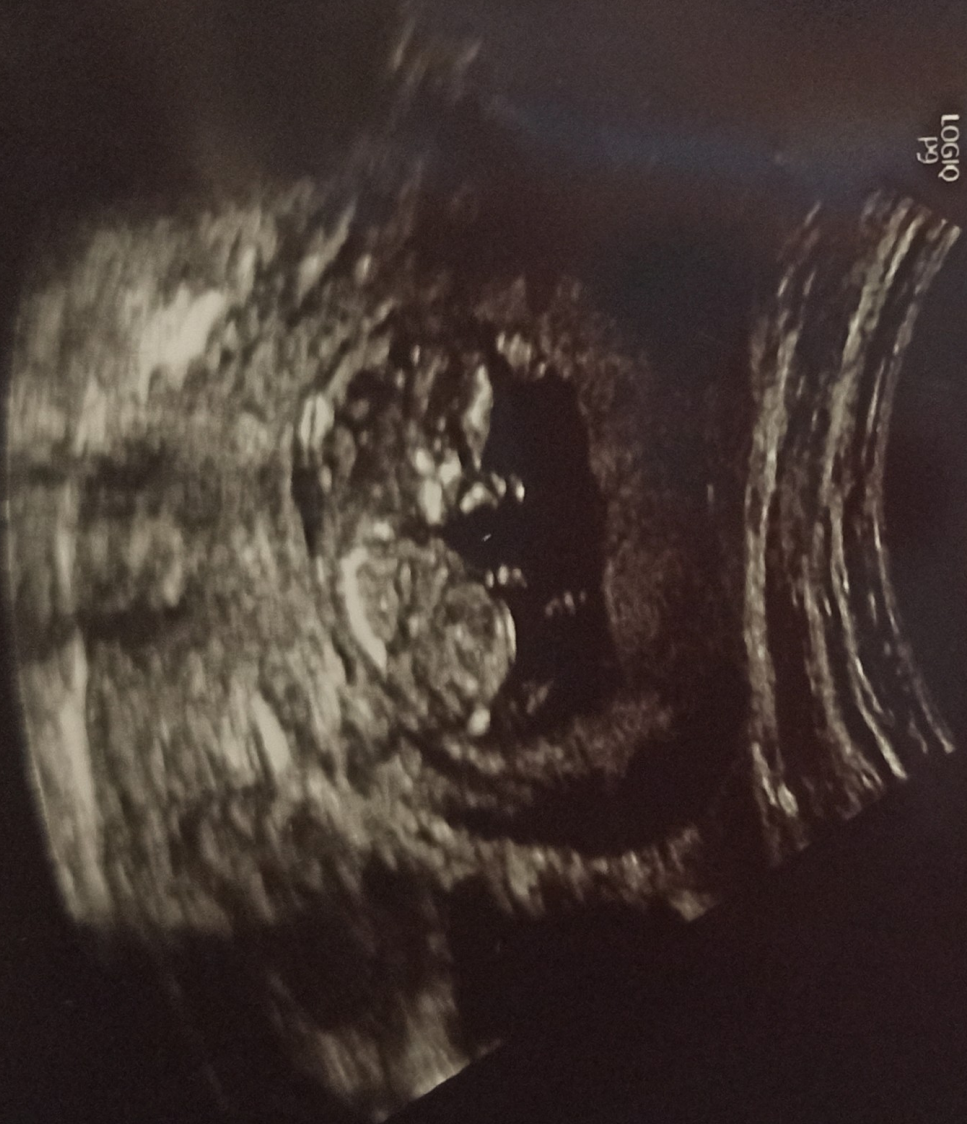JLNIMA,

USR 061123 092115AM

M1 1.0 11b 0.5
12w1d:1MP

CI 5
OB 1

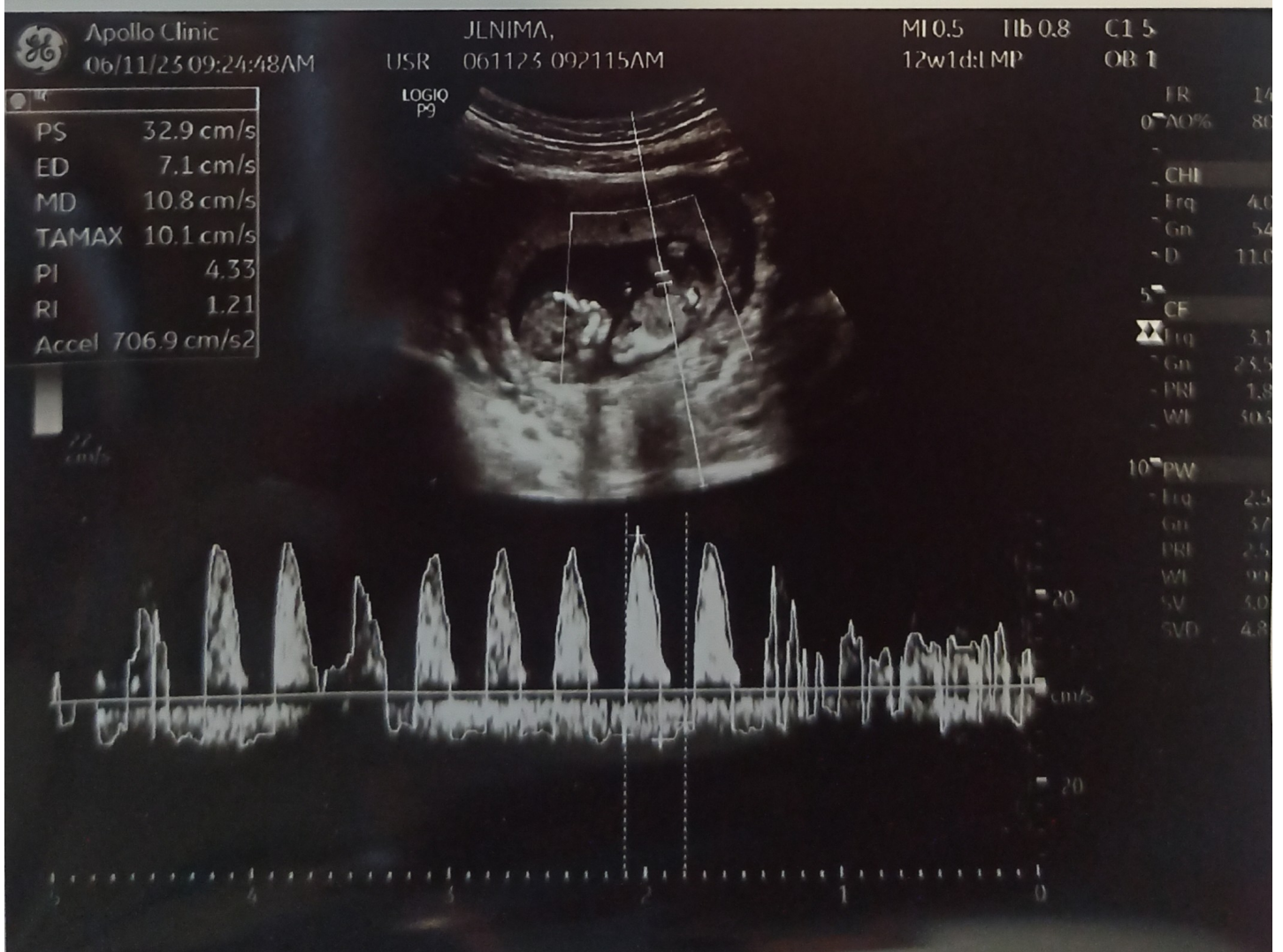
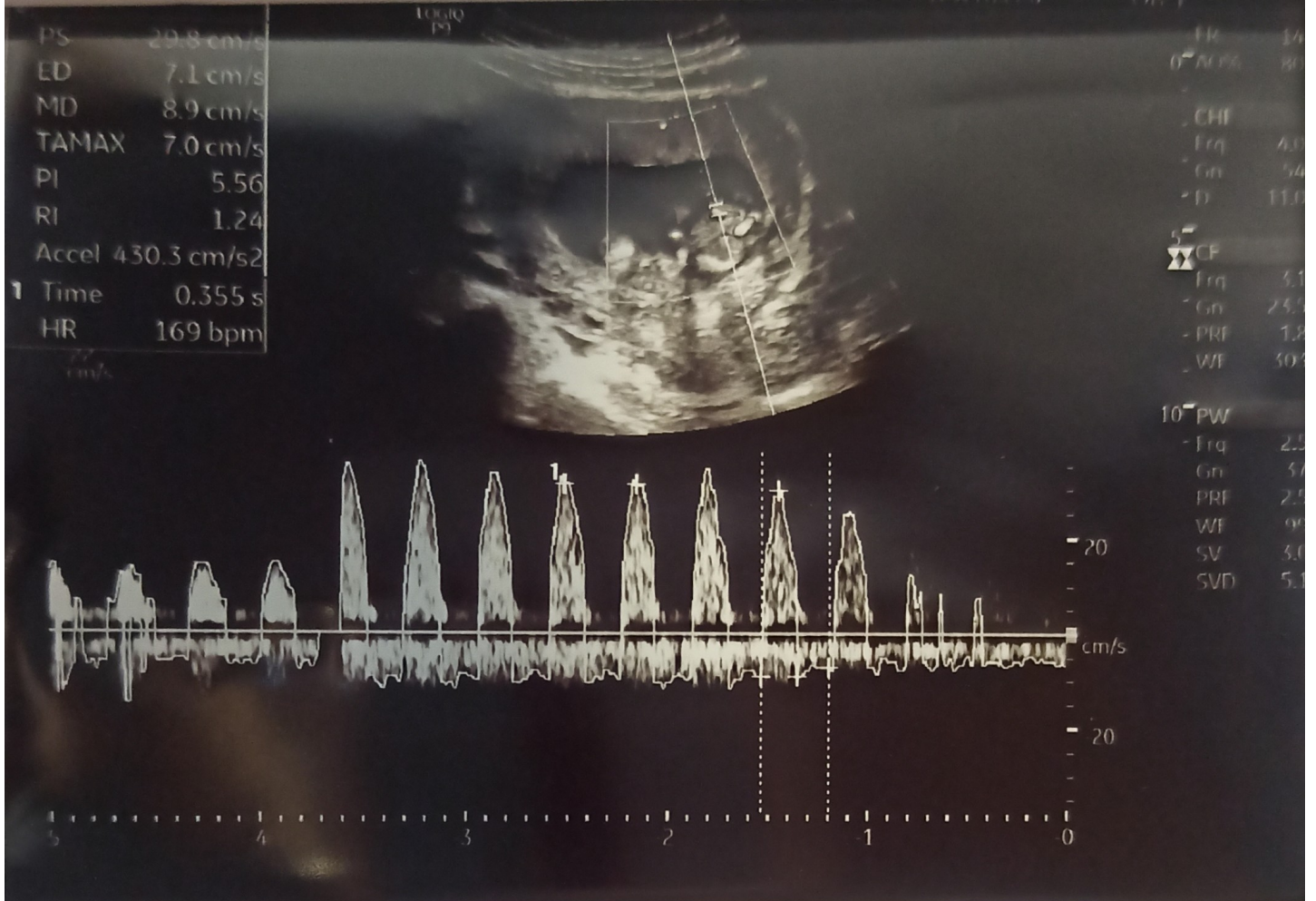
LOGIO
p3




FR 51
AO% 80

CHI
Frq 4.0
0 Gn 54
S/A 272
Map F/D
D 11.0
DR 60

107





Dr. Ira Biswas

MBBS, MS (O&G)

Fellowship in Minimal Access Surgery (FMS, Chennai)

Fellowship in Reproductive Medicine (FRM, Chennai)

Consultant Obstetrics & Gynaecology

Endo-Laparoscopic Surgeon & Infertility Specialist



Mob No: 9707802599

Reg No. MCI-43241

Name: Jerina Yashmin

Age/Sex: 23 / F

Date: 04/11/23

BP: 100/58 mmHg

PR:

Wt: 49.3 kg

LMP - 13/08/23

EDD - 20/5/24

PGR - 11+6 wks.

TT, ✓

R

① T. Vomikind MS
once daily SOS.

② T. Zecal Gold / Calzik
once daily X 30 days

③ T. Crinor XT
once daily X 30 days.

④ Pro-PL ——— ①.

⑤ ~~Syr Benon / Dycopro.~~
~~2 tef 2. once daily~~
X

NT scan
double markers