

Dr. MANSI JAIN

MBBS, MD (Gold Medalist)
DNB, FRCR(2A) UK
Consultant Radiologist
Trained in Fetal Medicine from Scholar MD
FMF Certified (11-13 wks Scan)



Dr. PANKAJ GOYAL

MBBS, DNB, FRCR(2A) UK
Consultant Interventional Radiologist
Clinical Fellowship in
Interventional Radiology
TATA Memorial Hospital, Mumbai

Patient name	Mrs. VARSHA	Age/Sex	26 Years / Female
Patient ID	E36745-23-11-16-24	Visit No	1
Referred by	Dr. Aradhna Gupta	Visit Date	16/11/2023 03:00:25 PM
LMP Date	28/08/2023 LMP EDD: 03/06/2024 ET Date: 12/09/2023 User EDD: 04/06/2024		

OB - First Trimester Scan Report

Real time B-mode ultrasonography of gravid uterus done.

Route: Transabdominal

Twin intrauterine gestation

Type of twinning

Dichorionic Diamniotic Twin

Maternal

Cervix measured 3.60 cms in length.

Fetus A

Survey

Liquor - Normal

Fetal activity absent

Cardiac activity absent

Biometry(Hadlock)

CRL - 24.5 mm(9W 1D)

Fetus B

Survey

Placenta - Anterior

Liquor - Normal

Umbilical cord - 3 vessel cord

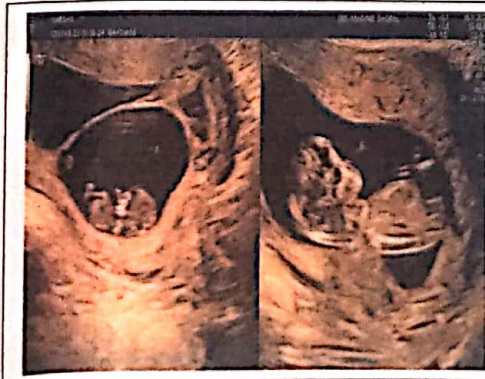
Fetal activity present

Cardiac activity present

Fetal heart rate - 166 bpm

Biometry(Hadlock)

CRL - 52.4 mm(11W 5D)



Dr. MANSI JAIN

MBBS, MD (Gold Medalist)
DNB, FRCR(2A) UK
Consultant Radiologist
Trained in Fetal Medicine from Scholar MD
FMF Certified (11-13 wks Scan)



Dr. PANKAJ GOYAL

MBBS, DNB, FRCR(2A) UK
Consultant Interventional Radiologist
Clinical Fellowship in
Interventional Radiology
TATA Memorial Hospital, Mumbai

Mrs. VARSHA / E36745-23-11-16-24 / 16/11/2023 / Visit No 1

Aneuploidy Markers

Nasal Bone : Present
Nuchal translucency : 1.4 mm Normal.
Ductus venosus : Normal flow.
Tricuspid regurgitation : No TR.


Fetal Anatomy

Head: normal, Neck: normal, Spine: normal, Face: normal, Thorax: normal, Heart: normal, Abdomen: normal, KUB: normal, Extremities: normal

Impression

Dichorionic Diamniotic Twin pregnancy with single live gestation corresponding to a gestational age of 11 Weeks 3 Days

Fetus A,B - Intrauterine
Gestational age assigned as per LMP
Fetus - A
Liquor - Normal
Fetus - B
Placenta - Anterior
Liquor - Normal
CRL discordancy :
Fetus A - 53%


DR. MANSI JAIN MD, DNB, FRCR(2A) UK
CONSULTANT RADIOLOGIST

Disclaimer

To book prior appointment for scan - call 8989635539
All Anomalies cannot be detected by sonography & a normal ultrasound does not guarantee a normal baby.
For any typing error , kindly contact at reception.