



# First Trimester Screening Report

## Kalpana Fetal Medicine and Scan Center

Protecting the Precious...

MRS Sandhya

Date of birth : 11 February 2001, Examination date: 21 November 2023

Hospital no.: KFC8869

Mobile phone: 7729918031

Referring doctor: TRIVENI

### Maternal / Pregnancy Characteristics:

Racial origin: South Asian (Indian, Pakistani, Bangladeshi).

Parity: 1; Deliveries at or after 37 weeks: 1.

Maternal weight: 53.0 kg; Height: 152.0 cm.

Smoking in this pregnancy: no; Diabetes Mellitus: no; Chronic hypertension: no; Systemic lupus erythematosus: no; Antiphospholipid syndrome: no; Preeclampsia in previous pregnancy: no;

Previous small baby: no; Patient's mother had preeclampsia: no.

Method of conception: Spontaneous;

Last period: 21 August 2023

EDD by dates: 27 May 2024

### First Trimester Ultrasound:

US machine: E 6. Visualisation: good.

Gestational age: 12 weeks + 2 days from CRL

EDD by scan: 02 June 2024

|                           |              |  |
|---------------------------|--------------|--|
| Findings                  | Alive fetus  |  |
| Fetal heart activity      | visualised   |  |
| Fetal heart rate          | 196 bpm      |  |
| Crown-rump length (CRL)   | 57.0 mm      |  |
| Nuchal translucency (NT)  | 1.5 mm       |  |
| Biparietal diameter (BPD) | 21.0 mm      |  |
| Ductus Venosus PI         | 1.200        |  |
| Placenta                  | anterior low |  |
| Amniotic fluid            | normal       |  |

### Chromosomal markers:

Nasal bone: can not examine; Tricuspid Doppler: normal.

### Fetal anatomy:

Skull/brain: appears normal; Spine: appears normal; Heart: Appears normal; Abdominal wall: appears normal; Stomach: visible; Bladder / Kidneys: visible; Hands: both visible; Feet: both visible.

Uterine artery PI: 0.85 equivalent to 0.500 MoM

Endocervical length: 29.0 mm

### Risks / Counselling:

Patient counselled and consent given.

Operator: Lekkala Kalpana, FMF Id: 173593

| Condition                    | Background risk | Adjusted risk |
|------------------------------|-----------------|---------------|
| Trisomy 21                   | 1: 1027         | 1: 5134       |
| Trisomy 18                   | 1: 2424         | 1: 7346       |
| Trisomy 13                   | 1: 7627         | 1: 595        |
| Preeclampsia before 34 weeks |                 | 1: 6360       |

Page 1 of 2 printed on 21 November 2023 - MRS Sandhya examined on 21 November 2023.

-2-71/1/ఎ, గ్రీన్లాండ్ హాస్పిటల్ ఎదురుగా, డాక్టర్స్ కాలనీ, నల్లగొండ - 508 001. తెలంగాణ

For Appointment : ☎ +91 8522 856 854 | +91 9704 234 016

Call : 756821143

# Kalpana Fetal Medicine and Scan Center

## Trimester Screening Report

Protecting the Precious...

1: 377

growth restriction before 37 weeks

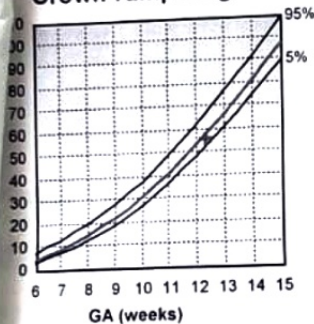
Background risk for aneuploidies is based on maternal age (22 years). The adjusted risk is the time of screening, calculated on the basis of the background risk and ultrasound factors (nuchal translucency thickness, fetal heart rate).

for preeclampsia and fetal growth restriction are based on maternal demographic characteristics, medical and obstetric history and uterine artery Doppler.

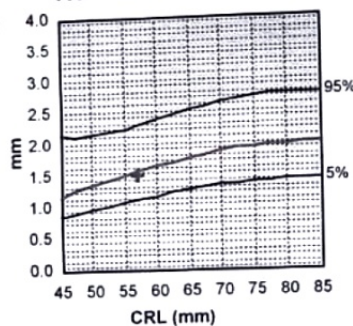
Physical markers are corrected as necessary according to several maternal characteristics including racial origin, weight, height, smoking, method of conception and parity.

Estimated risk is calculated by the FMF-2012 software (version 2.81) and is based on findings of extensive research coordinated by the Fetal Medicine Foundation (UK Registered charity 11116). The risk is only valid if the ultrasound scan was performed by a sonographer who has been accredited by the Fetal Medicine Foundation and has submitted results for regular audit (see www.fetalmedicine.com).

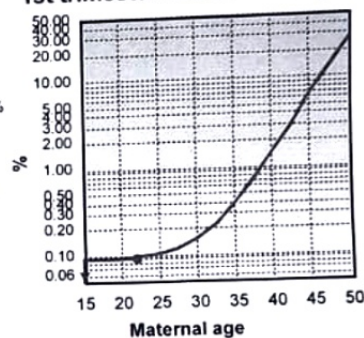
Crown-rump length



Nuchal translucency



1st trimester risk of Trisomy 21



### Comments

Single live intra uterine fetus corresponding to 12 weeks 2 day.

Down syndrome screen negative based on NT scan.

Suggested DOUBLE MARKER.

Suggested EARLY TIFFA SCAN at 16 weeks. ( Dec 19th to 21st )

I, Dr. L. Kalpana reddy, declared that while conducting ultrasonography / imaging scanning on Mrs. SANDHYA, I have neither detected nor disclosed the sex of fetus to any body in any manner.

DR. L. KALPANA REDDY  
FETAL MEDICINE CONSULTANT



O+ve

CMP: 21/8/23

END: 28/5/26

SEND: 1/6/24  
(9wks)

MC: 21yrs

NCOM

MH Reg

CCB: 3y

TSH: (N)



# త్రివేణి హాస్పిటల్

## TRIVENI HOSPITAL



గ్రీన్లాండ్ హాస్పిటల్ గేటు ఎదురుగా, డాక్టర్స్ కాలనీ, నల్లగొండ.

**Dr. G. TRIVENI**

M.B.B.S., M.S.(Obgy.)  
Obstetrician & Gynaecologist  
Infertility Specialist  
Regd. No. 52814

సంప్రదించు వేళలు :  
ప్రతిరోజు ఉ॥ గం. 10-00 నుండి రాత్రి గం. 7-00 వరకు  
ఆదివారం ఉ॥ గం. 10-00 నుండి మ॥ గం. 2-00 వరకు

Cell: 7569550452, 6302900950

**డా॥ జి. త్రివేణి**

M.B.B.S., M.S.(Obgy.)  
ప్రసూతి మరియు స్త్రీల వ్యాధి నిపుణులు  
Regd. No. 52814

Name: Mrs. Sahdya w/o: Rama Krishna Challedu Age 22 Sex F

**PLAD**

E 3MA CUG

Date: 19.11.23

Valid Upto: 21/2/23

53kg

100

82cm

100 (normal) / kg

Heart: 55 bpm

Lungs: normal

C/O Bummy mild disten

o/c ec: Fair  
offen

per 80/60

PA: Soft

1st pulse

100

LMP :

EDD :

S.EDD :

ML :

Consanguinity Yes/No.

Menstrual Periods :

Reg/Irregular

Adv  
CUG

Cy. 1 : 2.9m

Sup. Gestat cont  
E 250ml feral  
T. UTE cont  
154

Barcode: 24832764

EMP: 21-08-2023

DOB: 11-02-2001

Weight: 53 kgs

Phone: 7729918031