

**OM PATHOLOGY LAB**  
Shivaji Nagar Silwani Mob. 8109961486

**BLOOD GROUP CARD**

Name: MRS. Kirti Sahu  
Age/Sex: 22/21 Mobile: \_\_\_\_\_  
Address: \_\_\_\_\_  
Blood Group & Rh Factor: B - ve Rh Negative  
Date: 14/05/2023 Sig. Pathologist

Dr. Zinsi Thakur  
MBBS MS DNB  
Gynaecologist & Obstetrician  
Reg No. MP-12329

सिद्धि विनायक मेडिकल स्टोर के ऊपर, यशवंत नगर, सागर रोड, रायसेन  
सोमवार, बुधवार, शुक्रवार - समय: दोपहर 3:00 बजे से सायं 5:30 बजे तक

दिनांक 28/4/23

नाम Kirti आयु 22 लिंग F

R/O Silwani

ANC 2 with  
c/o. cough

UPT +ve

done at  
home

80k  
-120/80 mm Hg  
P/A 80/60

Adm.  
ANC 10

1/2

Q11b  
LMP 11/5/23

- Tb - 21F1 - 30x30
- Syp. giiloumb (H) 80
- Tb. SOLVITE - 00x30
- Tb. SUSTAIN - 00x10

**सिद्धि विनायक मेडिकल स्टोर**

मोबा. 8989163446, 7869694757, गार्ल्स स्कूल के सामने, सागर रोड, रायसेन

अंग्रेजी, आयुर्वेदिक एवं पशुओं की दवाईयाँ उचित दाम पर मिलने का एक मात्र सर्वसुविधायुक्त एवं विश्वसनीय स

# डॉ. जिंसी ठाकुर

एम.बी.बी.एस. एम.एस. डी.एन.बी.  
स्त्री एवं प्रसूती रोग विशेषज्ञ  
मोबा.: 8964803005  
रजि. नं.: MP-12329



Dr. Zinsi Thakur

M.B.B.S. M.S. D.N.B.  
Gynaecologist & Obstetrician  
Reg. No. MP-12329

परामर्श का स्थान: सिद्धि विनायक मेडिकल स्टोर के ऊपर, यशवंत नगर, सागर रोड, रायसेन

सोमवार, बुधवार, शुक्रवार - समय: दोपहर 3:00 बजे से सायं 5:30 बजे तक

दिनांक 26/11/23

नाम Kirbi आयु 22yr लिंग F

R/O Silman

ANC 2 with  
40. cough

80kms  
-120/80kms leg  
PIA 80kms

UP Thine  
done at  
hau  
Adm.  
ANC 80kms  
/

Q.16.  
Lup 11/5/23

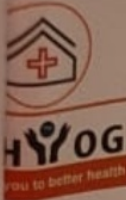
Rx -  
- Tb. ZIFI - 100 x 3d  
- Syg. gillomub (H) 800  
- Tb. SOLVITE - 100 x 30d  
- Tb. SUSTAIN - 100 x 15d

सिद्धि विनायक मेडिकल स्टोर

मोबा. 8989163446, 7869694757, गर्ल्स स्कूल के सामने, सागर रोड, रायसेन

अंग्रेजी, आयुर्वेदिक एवं पशुओं की दवाईयाँ उचित दाम पर मिलने का एक मात्र सर्वसुविधायुक्त एवं विश्वसनीय स्थान।





# SAHYOG DIAGNOSTICS

## SONOGRAPHY, CT-SCAN

### X-RAY, COLOR DOPPLER, PATHOLOGY

**Dr. YUVRAJ**

MD (Radiodiagnosis), DMRD (Gold Medalist)  
Ex. Sr. Resident Hamidia Hospital, Bhopal  
Ex. Consultant Sanya Diagnostics, Bhopal  
Ex. Consultant Siddhanta Red Cross, Bhopal  
Reg. No. MP17584

**Abdomen:** Abdominal circumference is normal. Anterior abdominal wall appears intact. No evidence of omphalocele/gastroschisis seen. Liver, GB & spleen appear normal. Fetal stomach and bowel loops appear normal. No evidence of ascites seen.

**KUB:** Both kidneys appear normal in size. PCS compact. Urinary bladder appears normal in size.

**Limbs:** All four limbs are seen and appear normal for the period of gestation. The bones and soft tissues in proximal, mid and distal segments of both upper and lower limbs are normal. Digit count not included in this scan. Digit count not included in this scan.

**Impression:** Intrauterine single live fetus of 28 weeks and 3 days duration  $\pm$  1 week with breech presentation. No gross foetal anomaly seen.

Expected date of delivery by sonography 16/02/2024

DR. YUVRAJ, MBBS, MD, DMRD, declare that while conducting USG on Mrs. KIRTI SAHU, I have neither declared nor disclosed the sex of her fetus to anybody in any manner.

It must be noted that detailed fetal anatomy may not be visible due to technical difficulties, fetal position and fetal movements etc. Therefore all fetal abnormalities may not be detected. This report is not for medico-legal purpose. Fetal ECHO is not done in this study.

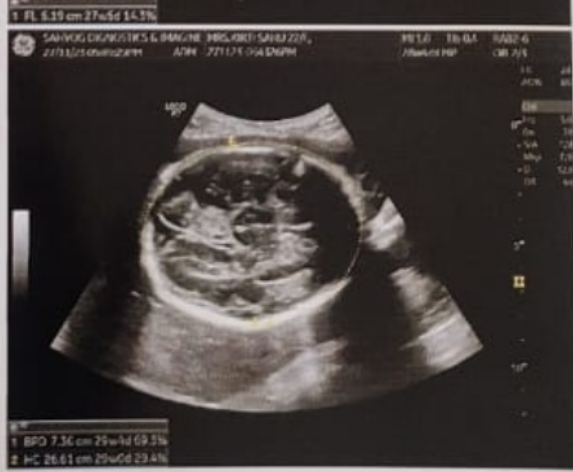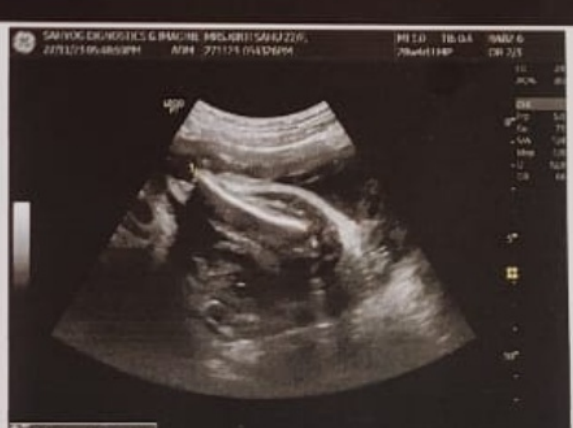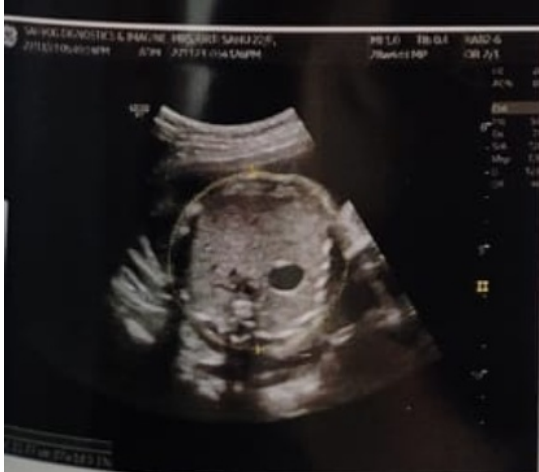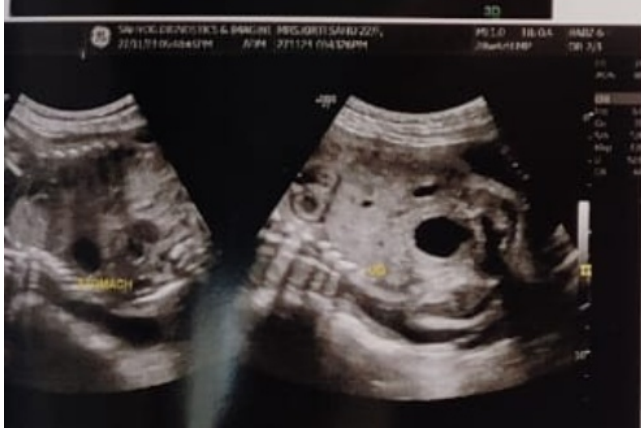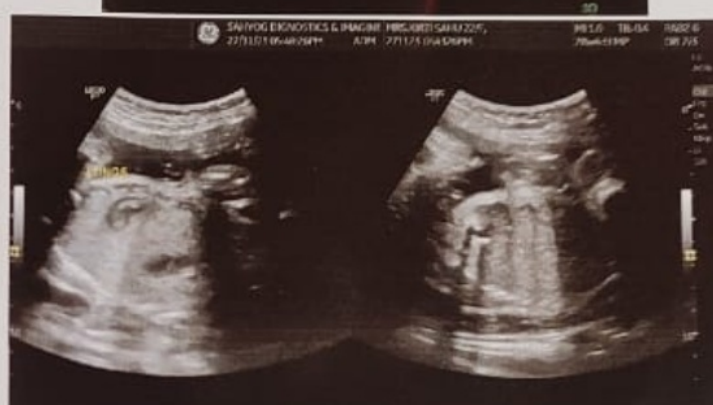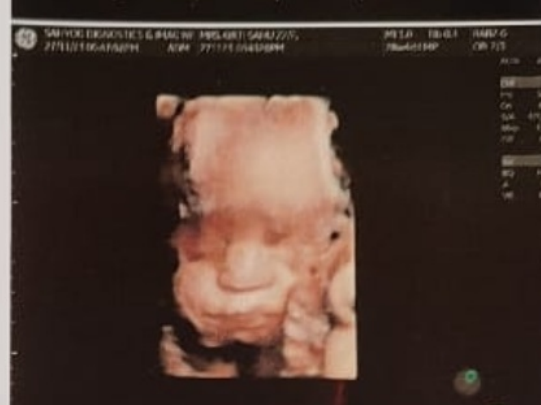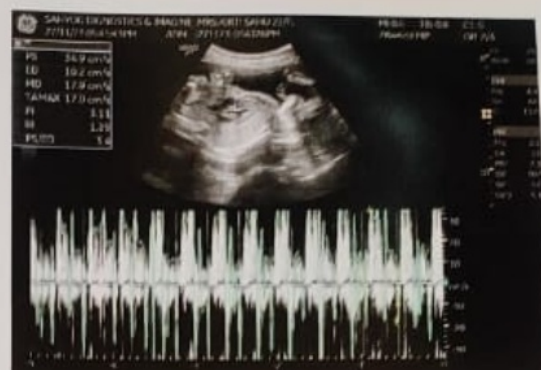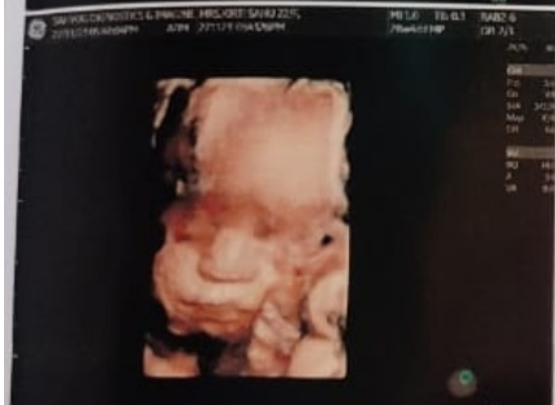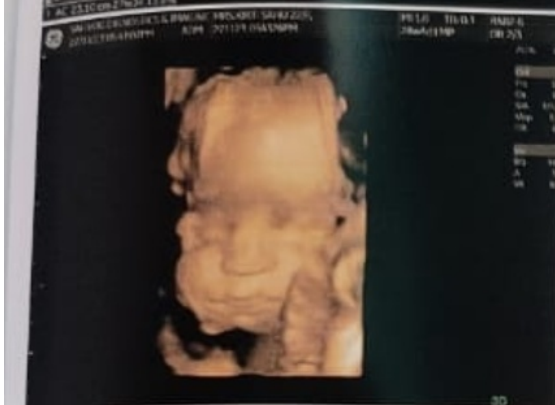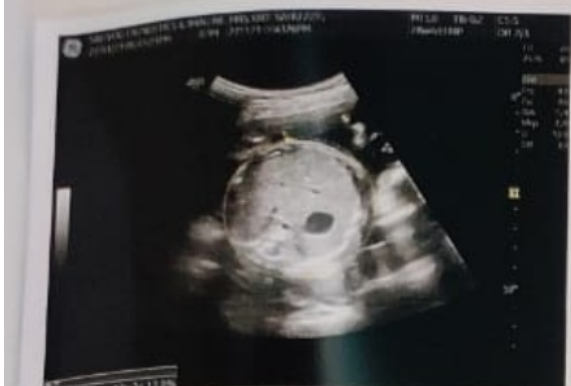DR. YUVRAJ  
MBBS, MD, DMRD (Gold medalist)  
Consultant Radiologist

Dr. YUVRAJ RAJAK  
MD, DMRD.  
Reg. No. MP-17584

**SAHYOG**  
Leading you to better health











**SAHYOG**  
Leading you to better health

# SAHYOG DIAGNOSTICS SONOGRAPHY, CT-SCAN X-RAY, COLOR DOPPLER, PATHOLOGY

**Dr. YUVRAJ**

MD (Radiodiagnosis), DMRD (Gold Medalist)  
Ex. Sr. Resident Hamidia Hospital, Bhopal  
Ex. Consultant Sanya Diagnostics, Bhopal  
Ex. Consultant Siddhanta Red Cross, Bhopal  
Reg. No. MP17584

Pt. Name:	MRS. KIRTI SAHU	Age/Sex:	22 Year /Female
Ref. By:	DR. ZINSI THAKUR, MBBS, MS, DNB	Date:	27/11/2023

## TARGET SCAN OF PREGNANCY FOR FOETAL ANOMALY

LMP: 11.05.2023

GA by LMP: - 28W 4D

Single live foetus in breech presentation and longitudinal lie at the time of scan.

### **Foetal Parameter:**

BPD measures	7.3cm corresponding to	29weeks and	4days
HC measures	26.6cm corresponding to	29weeks and	0days
AC measures	22.7cm corresponding to	27weeks and	1days
FL measures	5.1cm corresponding to	27weeks and	5days
Composite gestational age by sonography		28weeks and	3days
Expected date of delivery by sonography		16/02/2024	
Effective fetal weight is approximately		1108gm $\pm$ 166gm.	

**Foetal cardiac activity:** is regular. Foetal heart rate is 157 beats/min. Foetal body and limb movements are normal.

**Placenta:** is on fundoposterior wall and away from OS, shows grade-II maturation.

**Umbilical cord:** 3 vessels cord is seen. Placental insertion is central. No loop of cord is seen around the neck.

**Liquor:** is adequate in amount. AFI measures 12 cm.

**Internal os:** is closed. Cervix is normal in length (4.5 cm). Endocervical canal appears normal.

**Head:** Appears normal in size and shape. Intracranial assessment of cerebral parenchyma, thalami, basal ganglia and cerebellum is normal. Transcerebellar distance is normal. Both lateral ventricles appear normal in size and show brightly echogenic choroid plexuses. Cavum septum pellucidum and midline falx are well visualized. Cisterna magna is normal. No SOL is seen. No encephalocele detected.

**Spine:** Full length of the vertebral column is visualized and appears normal. Posterior elements are seen as parallel bands of echoes with normal flaring in cervical region and convergence in sacrum. No evidence of spina bifida and sacral agenesis seen.

**Face:** Fetal face was visualized in profile and coronal scans. Anatomic assessment for forehead, orbits, eyeballs, lenses, nasal bone, lips, maxilla, hard palate and mandible is done. No gross facial anomaly detected. Intraorbital distance is normal. Cleft lip and cleft palate is not always detected on USG.

**Neck:** The anterior, posterior and lateral masses of neck are well appreciated. No cystic lesion is visible around the fetal neck. Nuchal thickness is normal.

**Heart:** Normal cardiac size, situs & position. Fetal echo is not done in this scan.

**Chest:** The thorax is assessed for the chest wall, lungs, mediastinum and diaphragm. Both lungs are echogenic, no lung cyst or SOL seen. No evidence of pleural or pericardial effusion seen. Fetal diaphragm is seen as smooth hypoechoic band of tissue. No diaphragmatic hernia seen.

34, Santoshi Vihar Colony, Narela Jod, Bhopal (M.P.)

Ph. No. 0755-3572722, 6266309310, Email : sahyogdiagnosticsbhopal@gmail.com

29/8/23

7.7

ICR

AM 30th.

R. 80k PIA  
88 100/70mtg

Gib. LMR 11/5/23  
EOD 18/2/24

PIA. Soft Adv. Obs. 108%

Rp -

- 7b. KOSFER-00  
- 7b. CC RTCH-00

22/11/23, Adv. TARGET.

SCAN.

fib quadruple  
stacky.

- Syn. WFL-B 17sf

- S. PRO POWORK





भारत सरकार  
Government of India



Issue Date: 16/11/2013



Keerti Sahu  
Keerti Sahu  
जन्म तिथि/DOB: 25/11/2000  
महिला/ FEMALE

**3614 5536 5884**

VID : 9145 9457 0135 9305

मेरा **आधार**, मेरी पहचान





भारतीय विशिष्ट पहचान प्राधिकरण

Unique Identification Authority of India




पता:

द्वारा: सुनील साहू, शिवाजी नगर वॉर्ड 04 सिलवानी, तह -  
सिलवानी, सिलवानी, रायसेन,  
मध्य प्रदेश - 464886

Address:

C/O: Sunil Sahu, shivaji nagar ward 04  
silwani - silwani, Silwani, Raisen,  
Madhya Pradesh - 464886



**3614 5536 5884**

**VID : 9145 9457 0135 9305**



1947



help@uidai.gov.in



www.uidai.gov.in