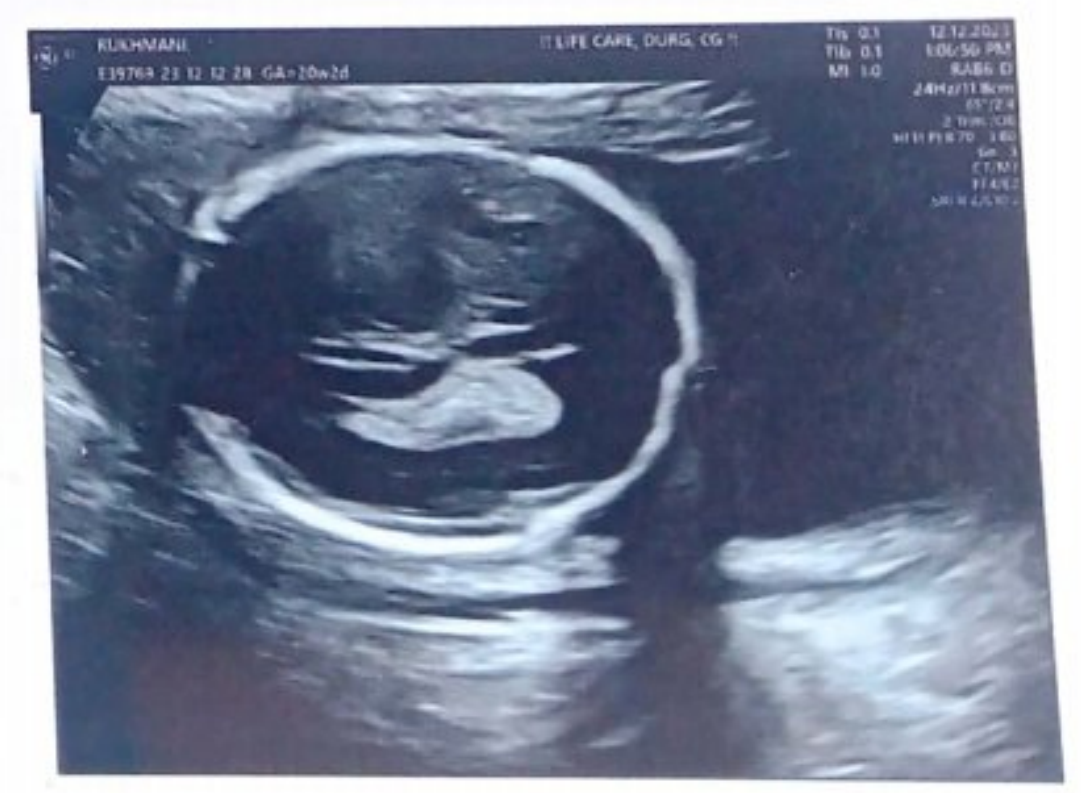
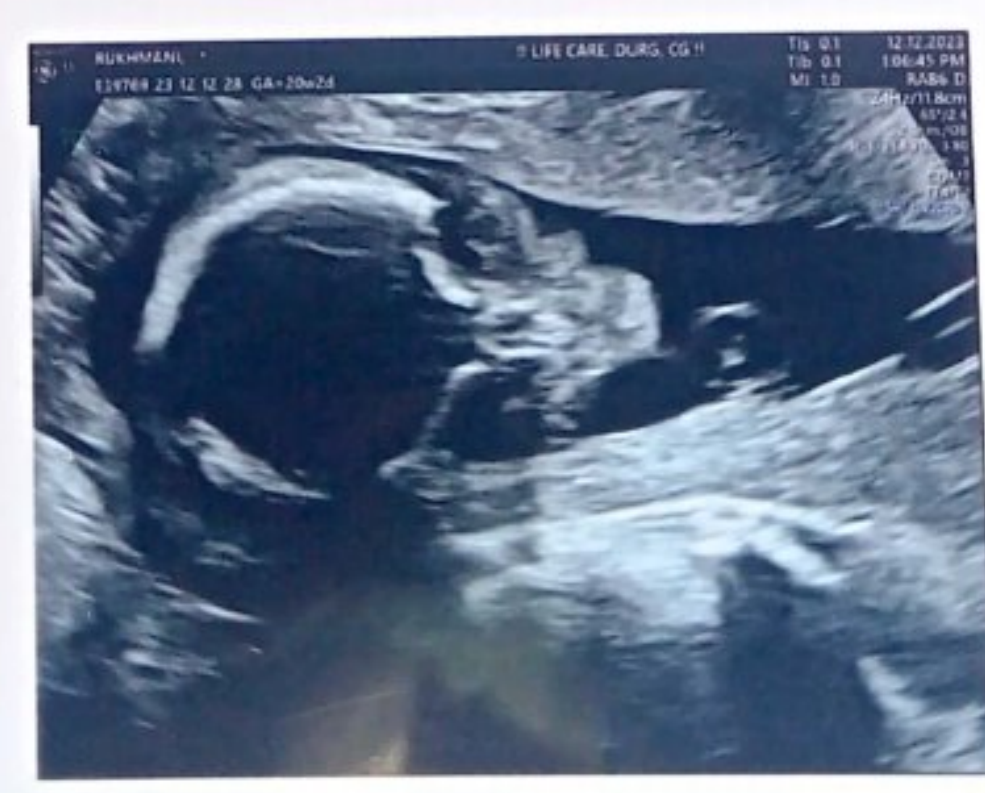
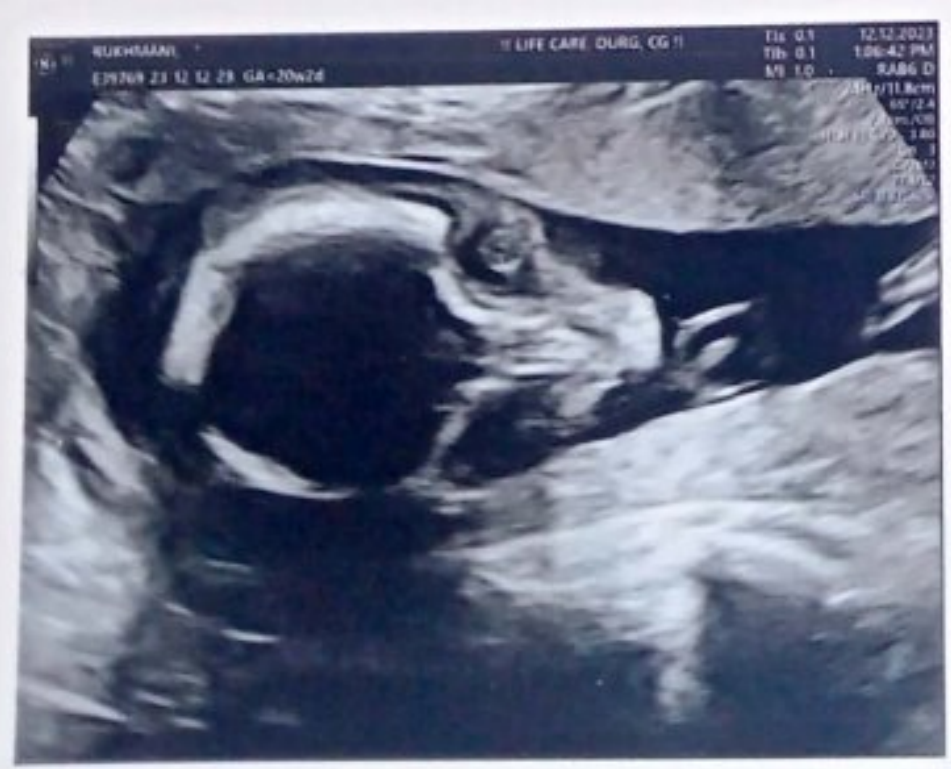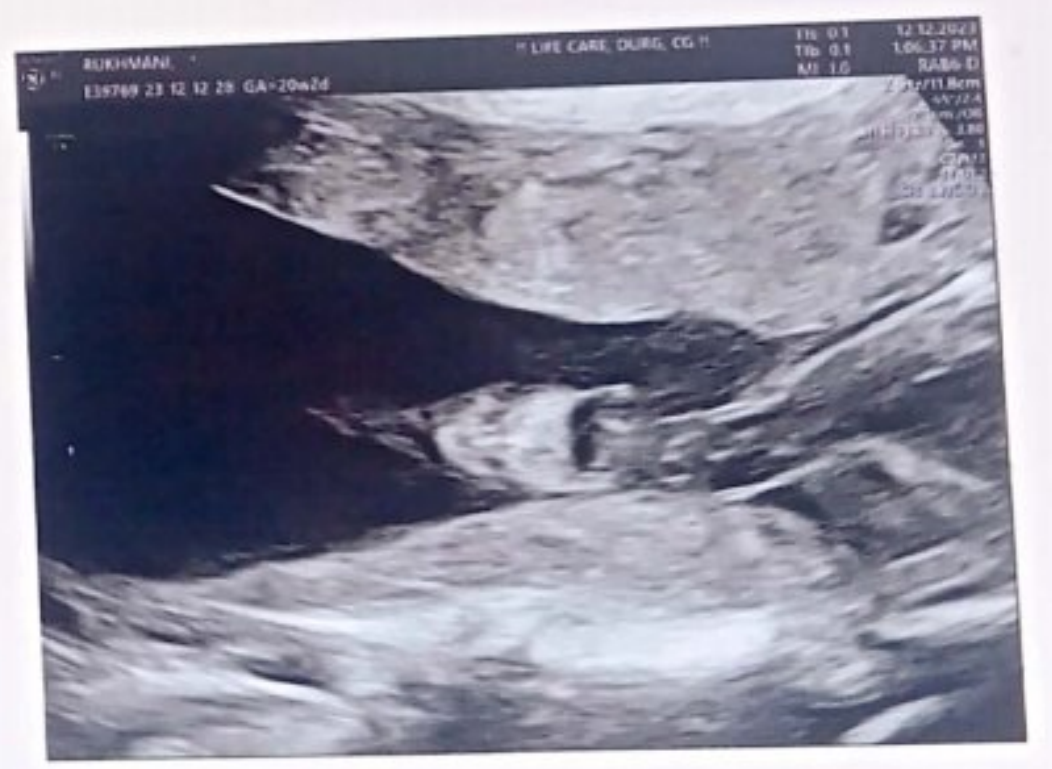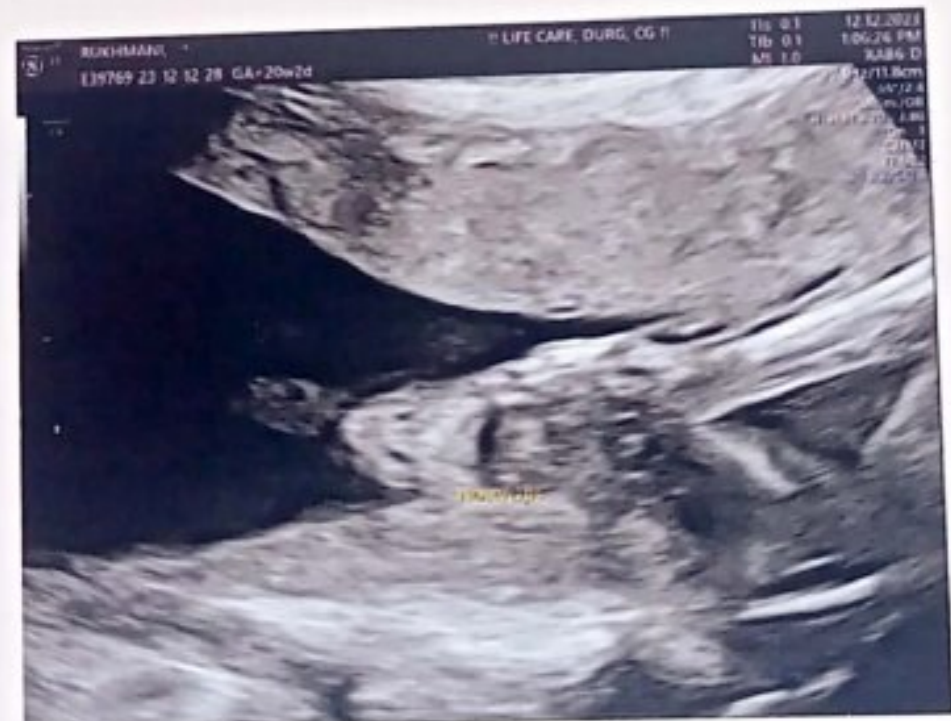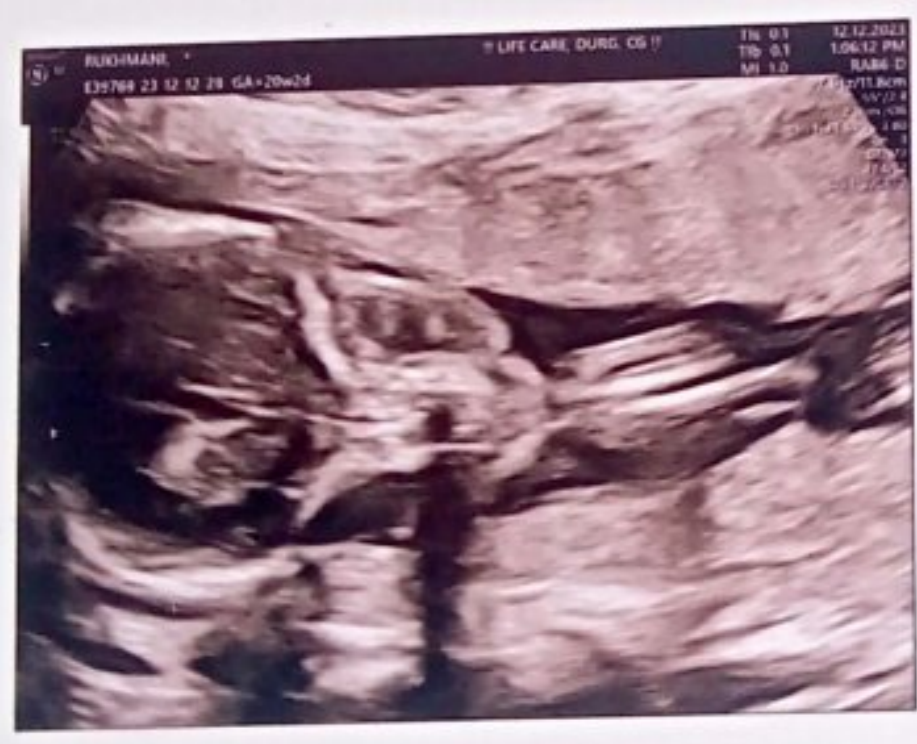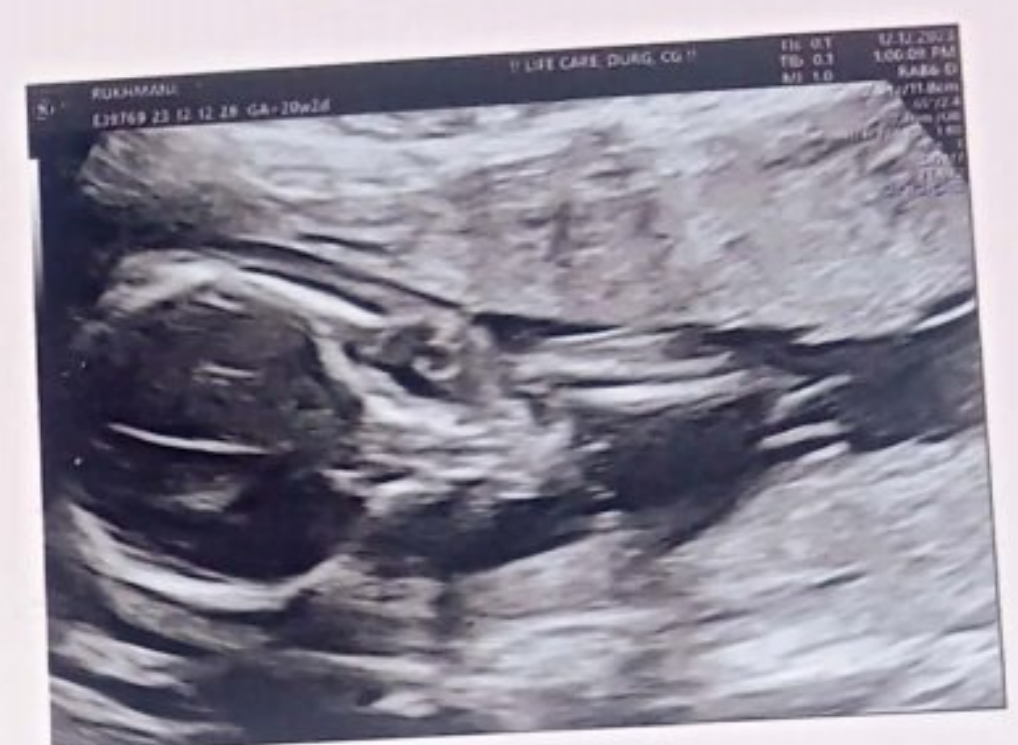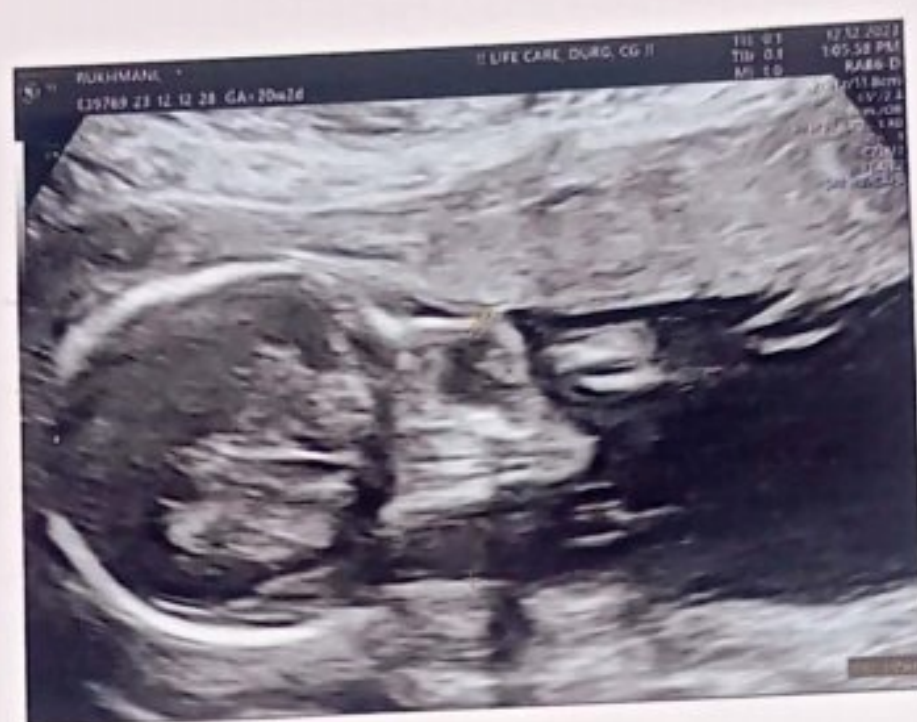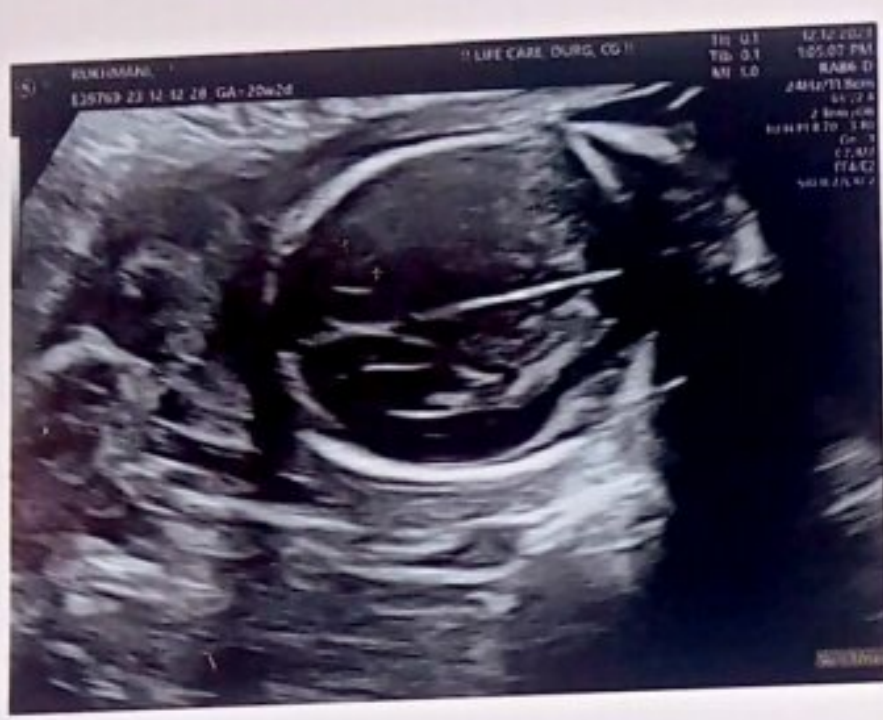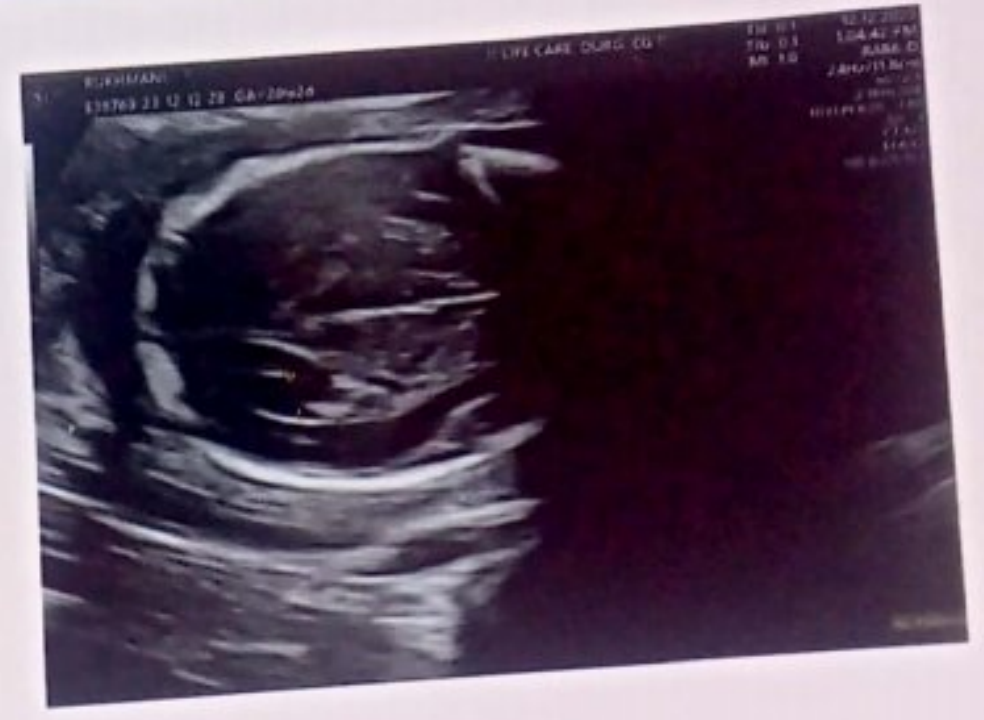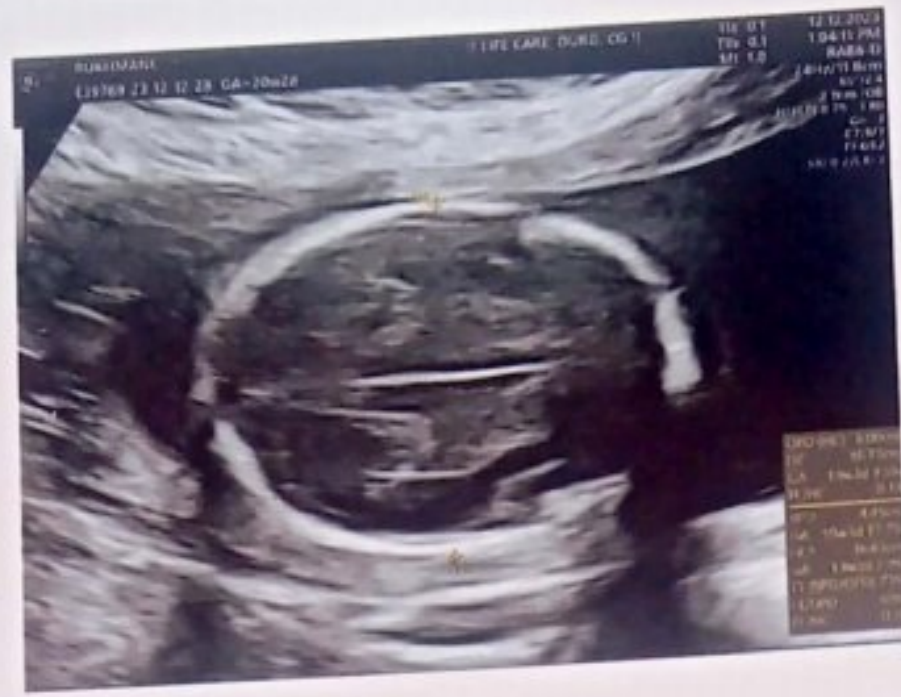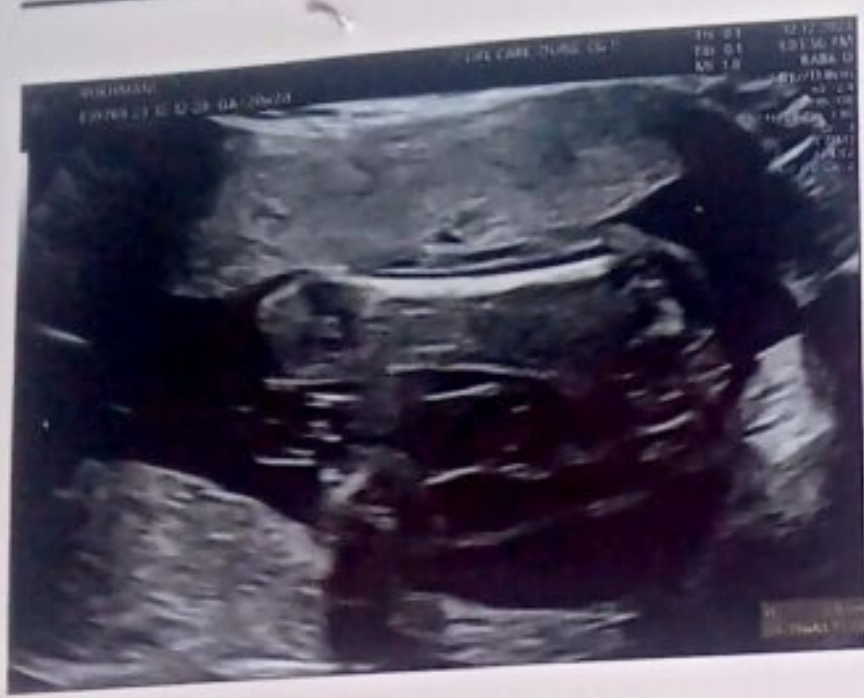ID: E39769-23-12-12-28

RUKHMANI







Exam Type:

Name RUKHMANI

DOB

Sex Female

Pat. ID E39769-23-12-12-28

Perf. Phys.

Ref. Phys.

Indication

Sonogr.

LMP 23.07.2023

GA(LMP) 20w2d

EDD(LMP) 28.04.2024

G

Ab

DOC

GA(AUA) 20w1d

EDD(AUA) 29.04.2024

P

Ec

EFW (Hadlock)

Value

Range

Age

Range

GP

Williams

AC/BPD/FL/HC

295g

± 43g

19w3d

N/A

2D Measurements AUA

Value

m1

m2

m3

Meth.

GP

Age


BPD (Hadlock)



4.45 cm

4.45

avg.



17.7%

19w3d

OFD (HC)

6.06 cm

6.06

avg.


HC (Hadlock)



16.73 cm

16.73

avg.



9.5%


19w3d

HC\* (Hadlock)



16.63 cm

16.63



7.9%

19w2d


AC (Hadlock)



14.08 cm

14.08

avg.



19.1%

19w3d


FL (Hadlock)



3.07 cm

3.07

avg.



17.3%

19w4d


TIB (Jeanty)



3.08 cm

3.08

avg.



84.8%

21w2d

FIB (Jeanty)



2.91 cm

2.91

avg.



52.1%

20w3d


HL (Jeanty)



3.29 cm

3.29

avg.



80.0%

21w1d


RAD (Jeanty)



2.96 cm

2.96

avg.



66.9%

21w2d


Ulna (Jeanty)



3.10 cm

3.10

avg.



77.3%

21w5d

Cereb (Hill)




1.93 cm

1.91

1.95

avg.



19.8%

18w5d

CM

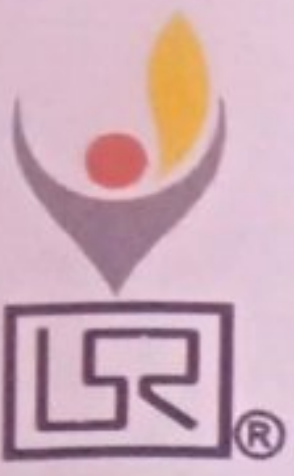3.98 mm

3.98

avg.







**Life  
Care**

**SCAN & RESEARCH CENTRE  
DIAGNOSTIC CENTRE**

Om Parisar, Arya Nagar, Durg (C.G.) 491 001  
Ph : 0788-2355701, 2355702, Mo.: 8349999518  
E-mail : lsr@lifecarescan.com | website : www.lifecarescan.com

Shivnath Complex, Beside Chouhan Estate, Bhilai (C.G) 490 023  
Ph : 0788-4910002, 4910003, Mo.: 9109176001  
E-mail : isdbhilai@gmail.com | website : www.lifecarescan.com



**Free Blood Sample Collection From Home, 24x7 Service**

**TEST REPORT**

Reg. No :121223/140  
NAME : MRS. RUKHMANI SAHU

AGE : 32 YEARS

Date: 12.12.2023  
SEX : F

REF. BY. : DR. MANSI GULATI DGO

TYPED BY - AT

**USG OBSTETRICS WITH TARGETED IMAGING FOR FOETAL ANOMALIES (TIFFA)**

- Suboptimal scan due to patient excessive anterior abdominal wall fat.
- (No previous USG performed).
- NT scan is not done by the patient.

Single live intrauterine fetus with **cephalic** presentation is seen at the time of examination.

Liquor is adequate in amount AFI-11-12 cm.

The cardiac pulsations and fetal movements are well seen.

The fetal heart rate is = **149 b/minute**.

The approximate gestational age is as follows:

Biparietal diameter	= 4.45 cm corresponds to 19.3 weeks.
Head circumference	= 16.73cm corresponds to 19.3 weeks.
Abdominal circumference	= 14.08 cm corresponds to 19.3 weeks.
Femur length	= 3.07cm corresponds to 19.4 weeks.
TIB	= 3.08 cm corresponds to 21.2 weeks.
FIB	= 2.91 cm corresponds to 20.3 weeks.
HL	= 3.29 cm corresponds to 21.1 weeks.
RAD	= 2.96 cm corresponds to 21.2 weeks.
Ulnar	= 3.10 cm corresponds to 21.5 weeks.
Cereb	= 1.93 cm corresponds to 18.5 weeks.

**Placenta- Anterior wall, mid uterine segment. Grade-II maturity.**

No obvious gross fetal anomaly is noticed in this examination.

The internal os and cervical canal are unremarkable.

The cervix is normal (3.4 cm).

P.T.O.





**Life Care**

**SCAN & RESEARCH CENTRE**

**DIAGNOSTIC CENTRE**

Om Parisar, Arya Nagar, Durg (C.G.) 491 001  
Ph : 0788-2355701, 2355702, Mo.: 8349999518  
E-mail : lsr@lifecarescan.com | website : www.lifecarescan.com

Shivnath Complex, Beside Chouhan Estate, Bhilai (C.G) 490 023  
Ph : 0788-4910002, 4910003, Mo.: 9109176001  
E-mail : isdbhilai@gmail.com | website : www.lifecarescan.com

**Free Blood Sample Collection From Home, 24x7 Service**



**NAME : MRS. RUKHMANI SAHU**

**TEST REPORT**

**AGE : 32 YEARS**

**SEX : F**

**TARGATED IMAGING FOR FETAL ANOMALIES (TIFFA)**

Cerebellum	N
Cisterna Magna	N
Lateral Ventricle	N
Spine	N
Orb 1	N
Orb 2	N
Heart 4- Chamber	N
LVOT	N
RVOT	N
Stomach	N
Nasal bone	N
LIPS	N
Kidney	N
Bladder	N
Limbs	N
Cord	2 arteries

**Estimated Foetal Weight Is 295 Gms +/- 43 Gms.**

GA (LMP) - 20 wks + 02 days

EDD (LMP) - 28.04.2024

GA (AUA) - 20 wks + 01 days

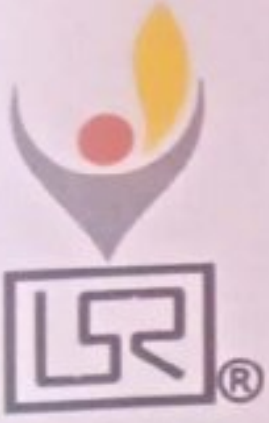EDD (AUA) - 29.04.2024

**Bilateral Uterine Arteries Are Showing Normal Wave Form And Doppler Indices.  
(Right uterine artery PI- 1.1, Left uterine artery PI- 0.8). Mean uterine PI- 0.95**

**P.T.O.**







**Life  
Care**

**SCAN & RESEARCH CENTRE  
DIAGNOSTIC CENTRE**

■ Om Parisar, Arya Nagar, Durg (C.G.) 491 001  
Ph : 0788-2355701, 2355702, Mo.: 8349999518  
E-mail : lsr@lifecarescan.com | website : www.lifecarescan.com



■ Shivnath Complex, Beside Chouhan Estate, Bhilai (C.G) 490 023  
Ph : 0788-4910002, 4910003, Mo.: 9109176001  
E-mail : isdbhilai@gmail.com | website : www.lifecarescan.com

**Free Blood Sample Collection From Home, 24x7 Service**

### TEST REPORT

NAME : MRS. RUKHMANI SAHU

AGE : 32 YEARS

SEX : F

#### IMPRESSION:-

- Single Live Intrauterine Pregnancy **Cephalic** Presentation Is Seen At The Time Of Examination Of **20 weeks + 01 days.**

**Advice: - Quadruple marker test correlation.**

(All measurement including foetal weight is subject to statistical variation. Fetal echo is not done.)

Note: - I Declare that while conducting USG, i have neither detected nor disclosed the sex of her fetus to any body in any manner.

Not all anomalies can be detected on sonography. Detection of anomalies is dependent on fetal position, gestational age. Maternal abdominal obesity and other technical parameters. Fetal limb anomalies not always detectable due to position. Follow up scanning and second opinion are always advisable. For detection of cardiac anomaly foetal echography is necessary. Ear anomalies cannot be detected.

Thanks for the reference,  
With regards,

**Dr. Girish Verma**  
M.D., D.M.R.D.  
Consultant Radiologist

**Dr. Suraj Kabra**  
MBBS, D.N.B.  
Consultant Radiologist

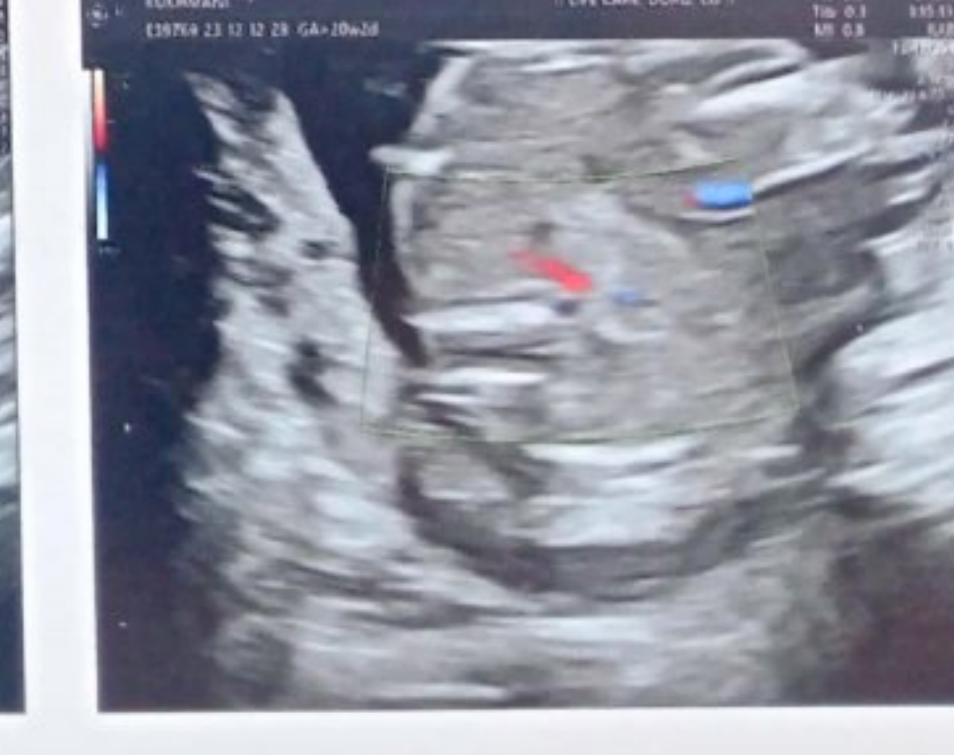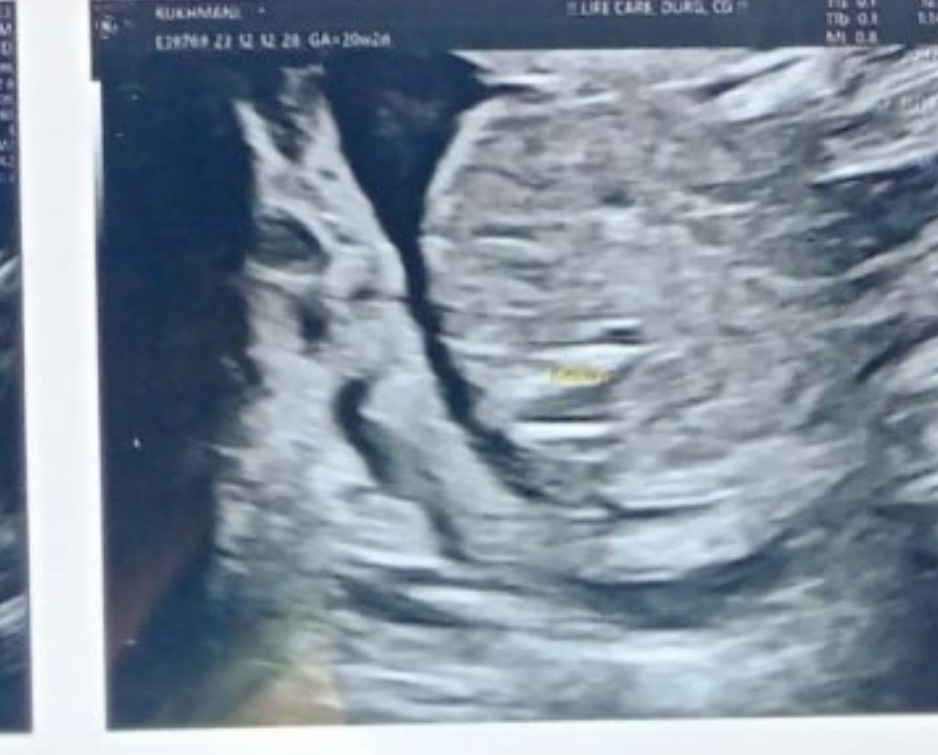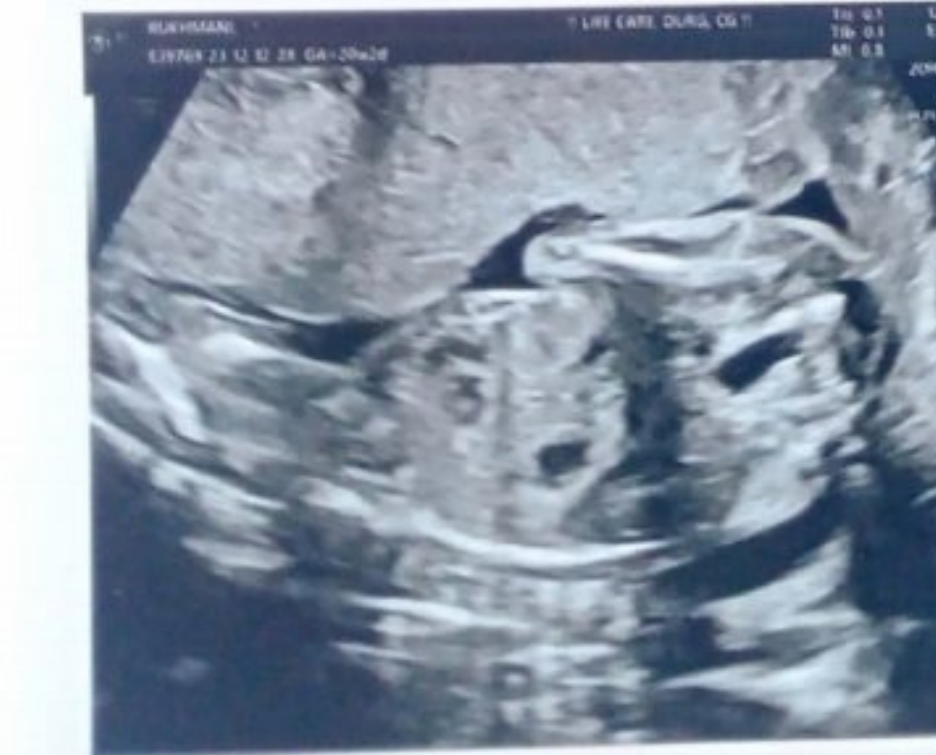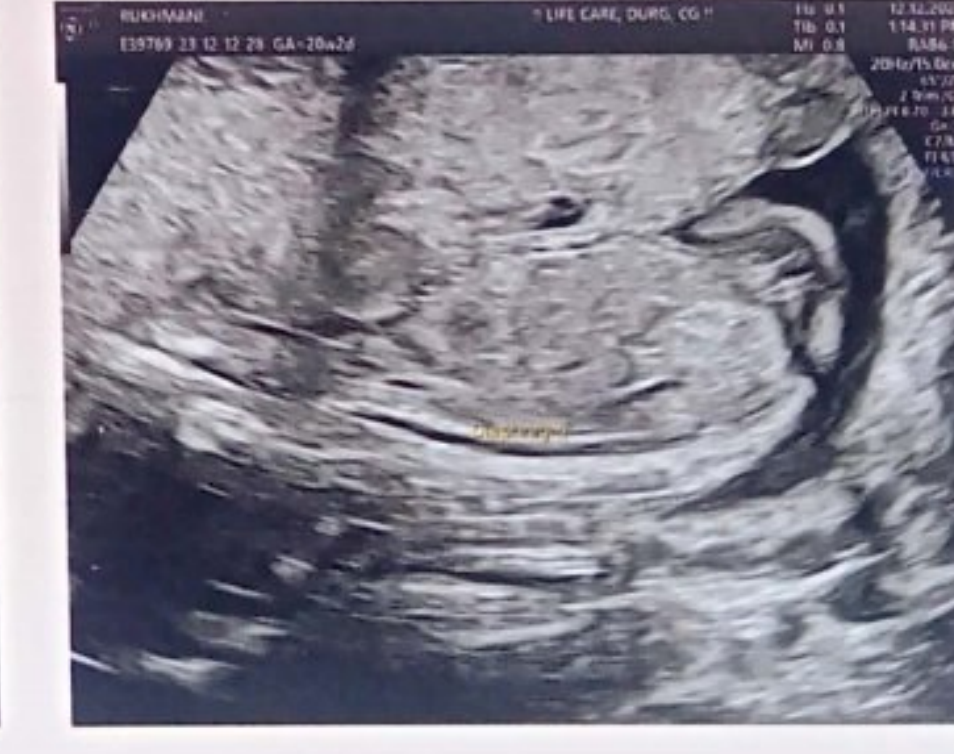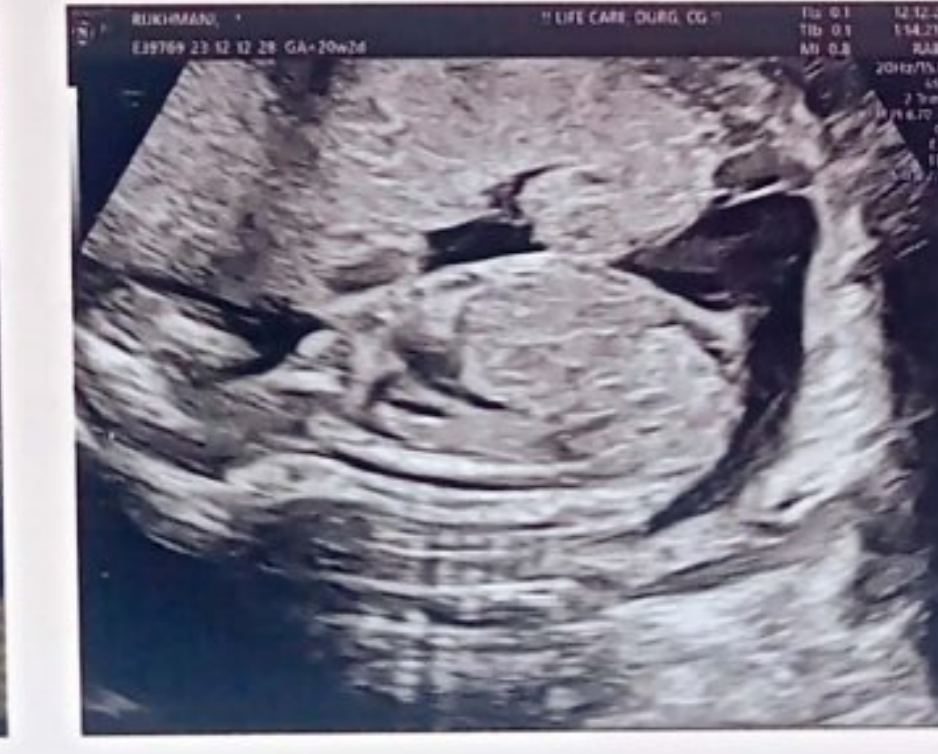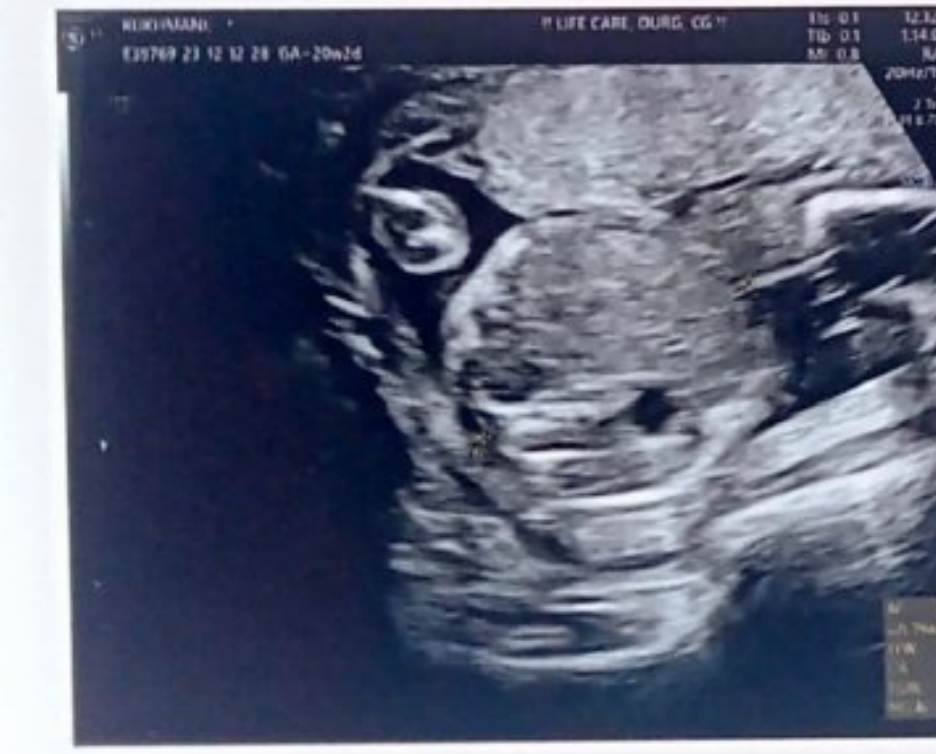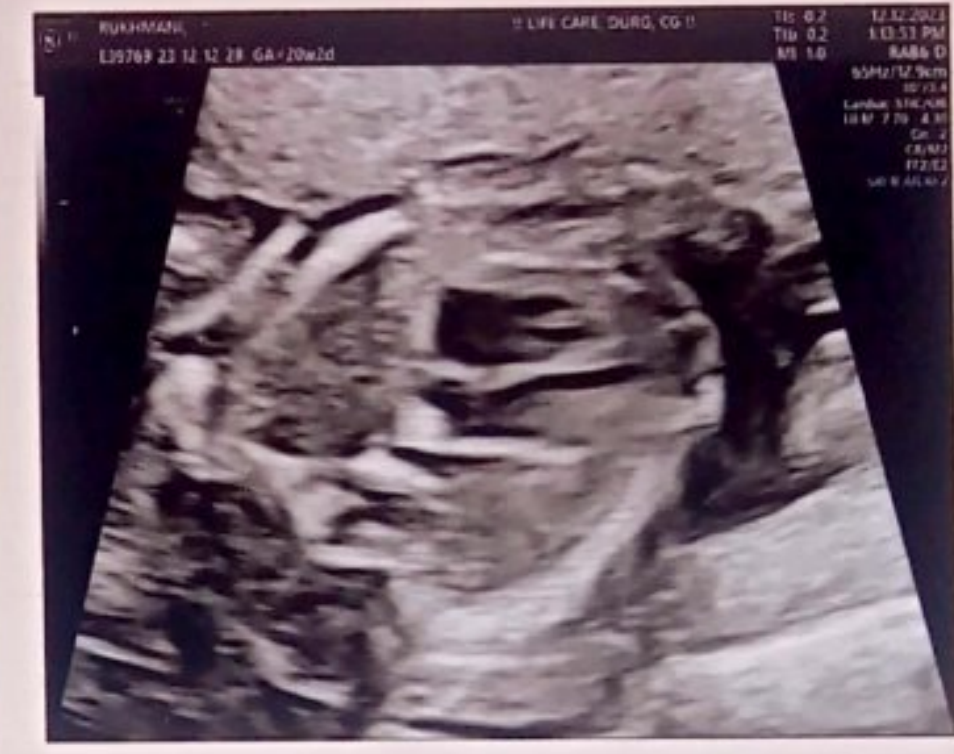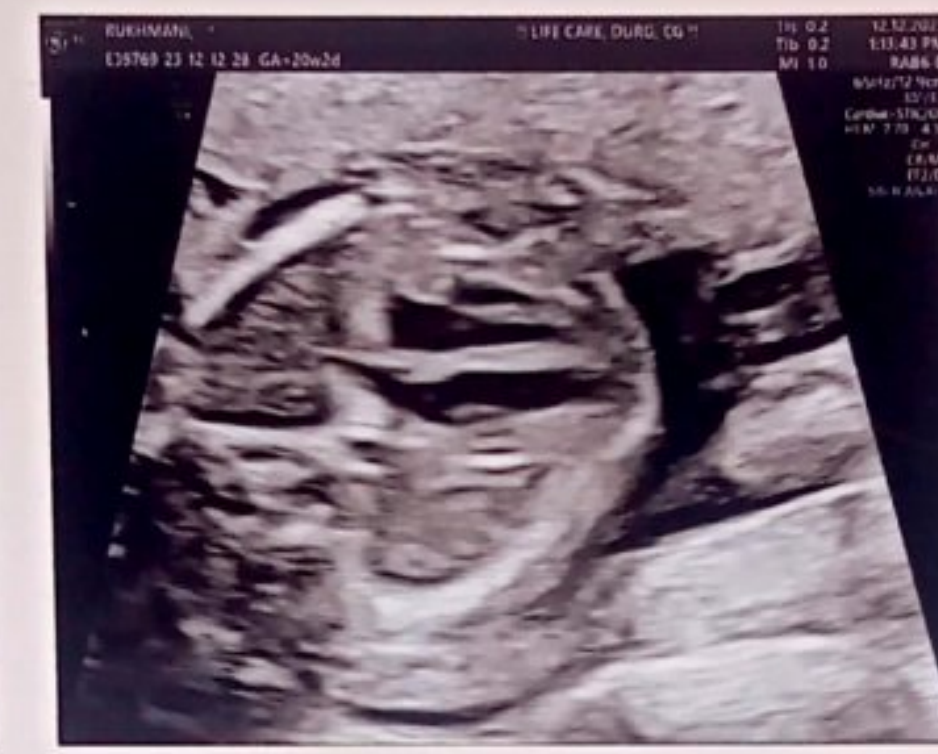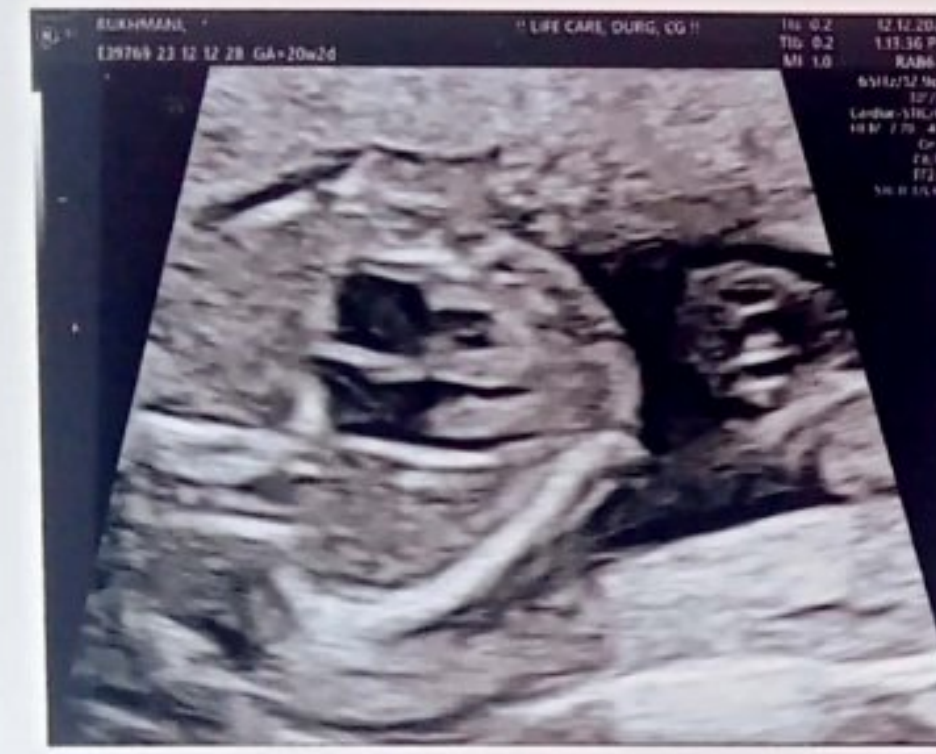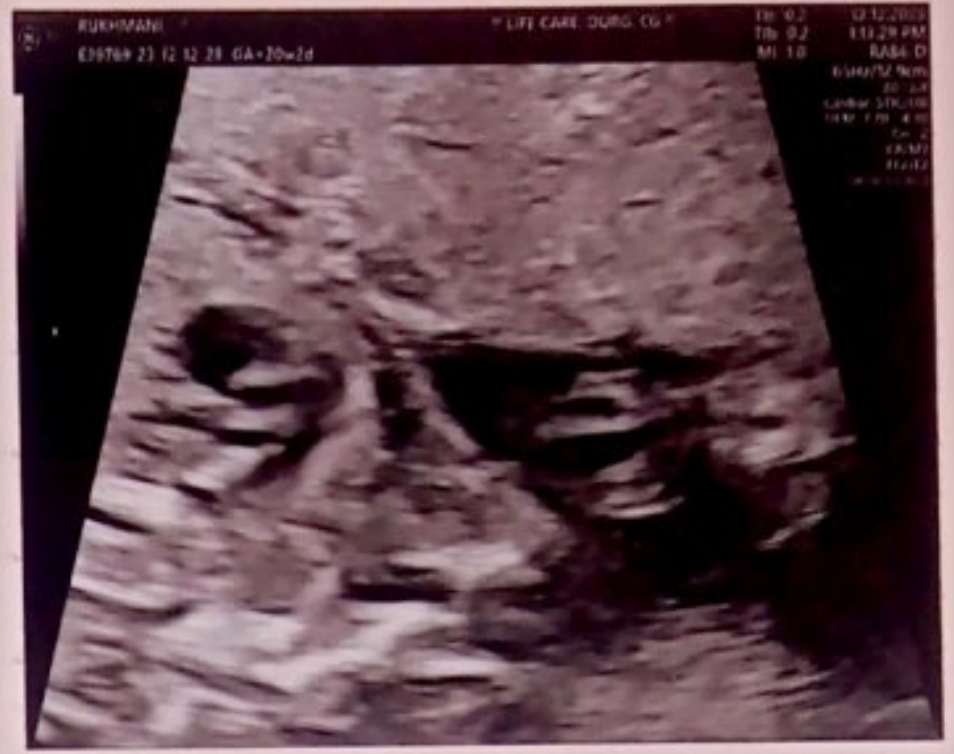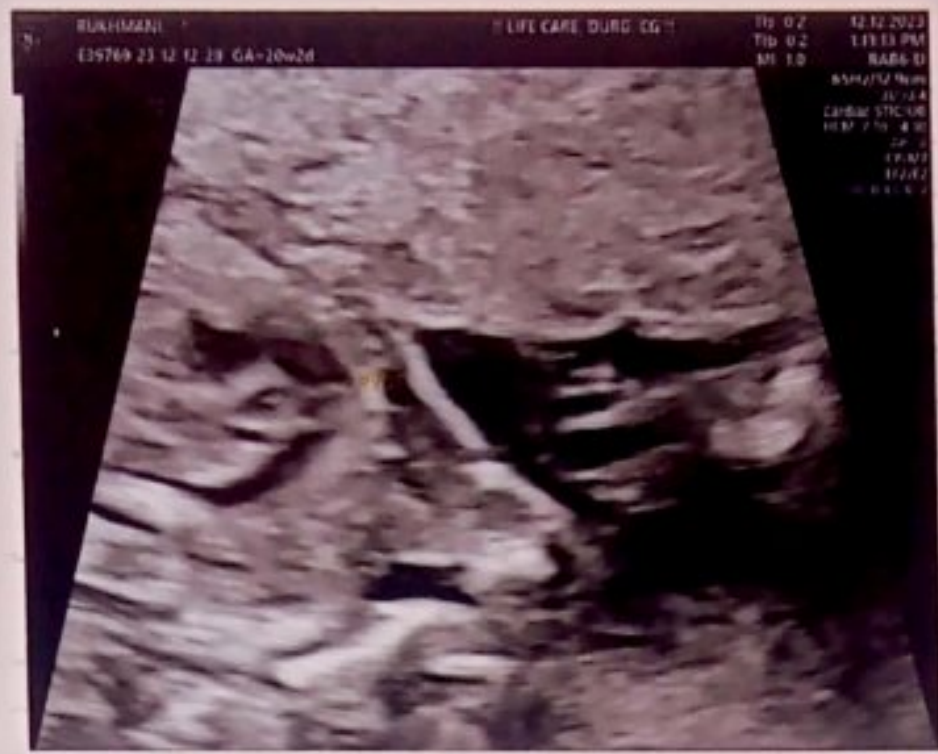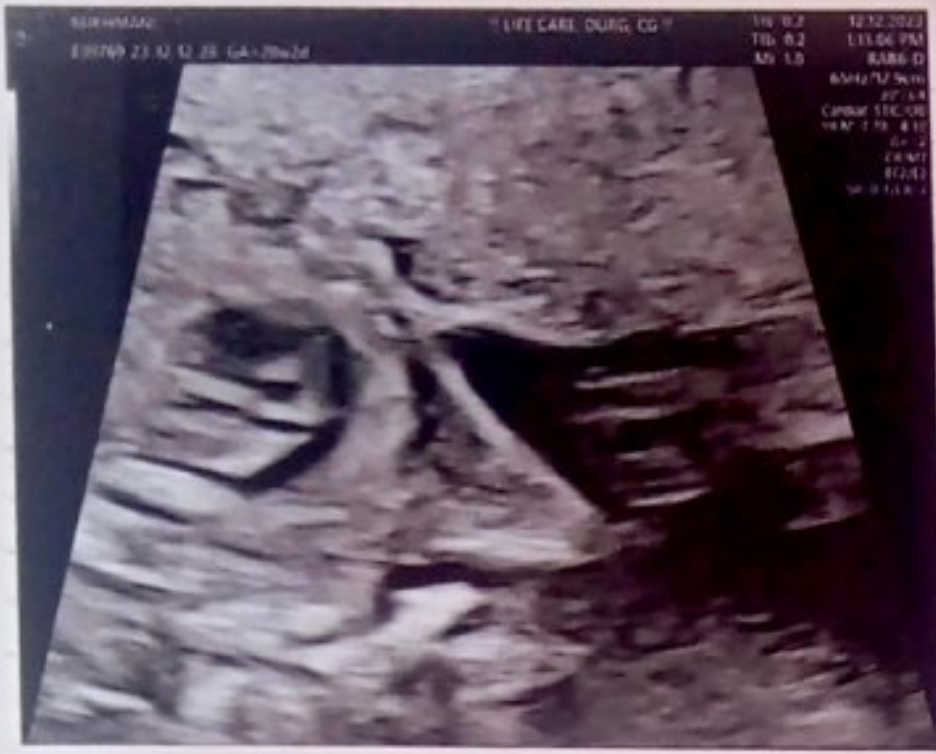**Dr. Abhishek Das**  
MBBS., MD.  
Consultant Radiologist

**Dr. Sonal**  
MBBS, MD  
Consultant Radiologist

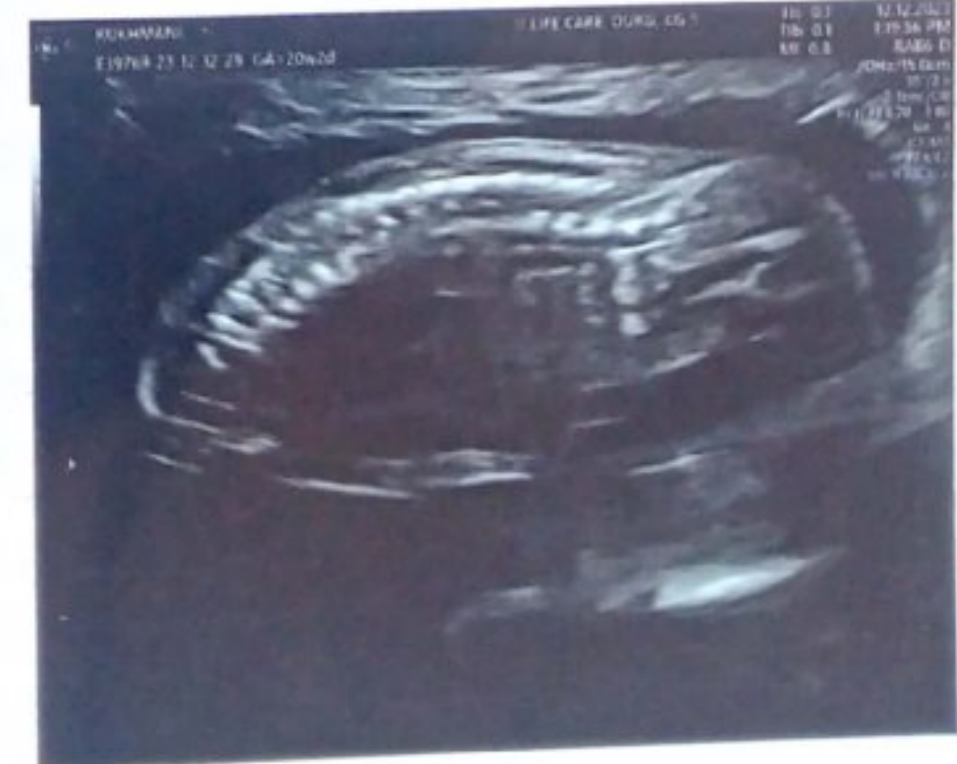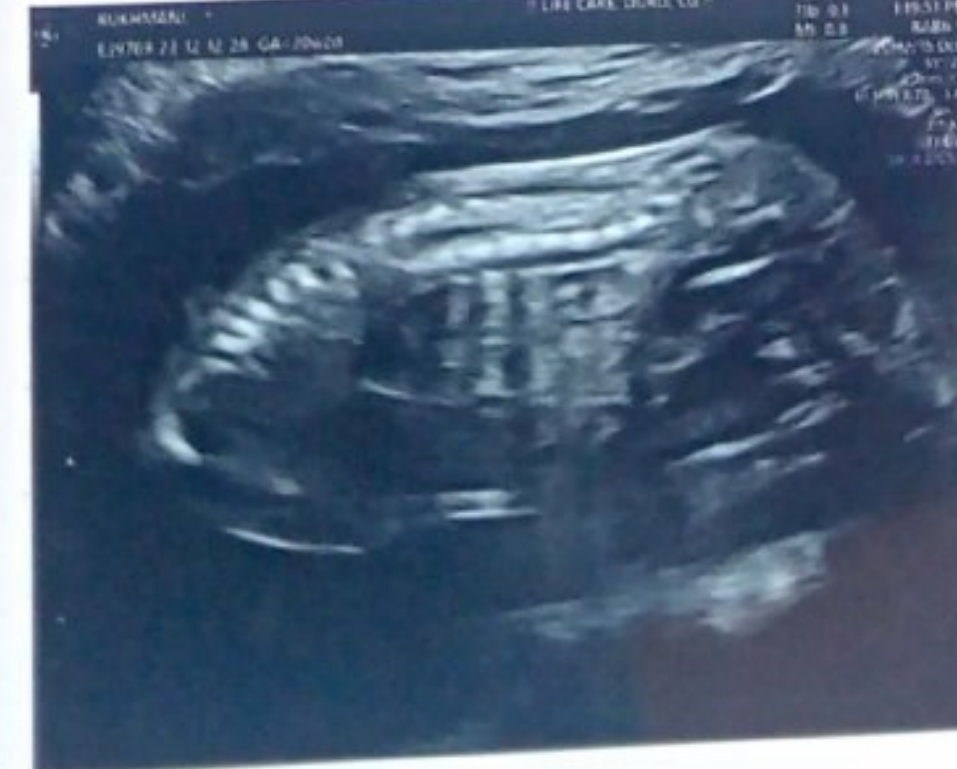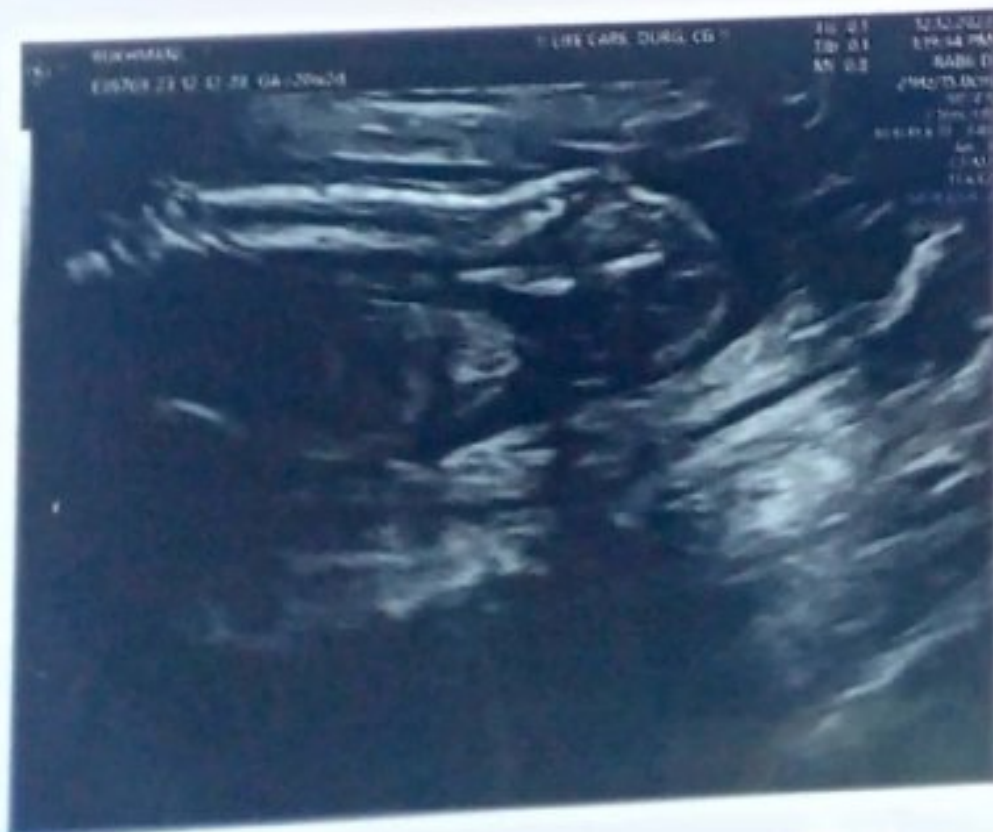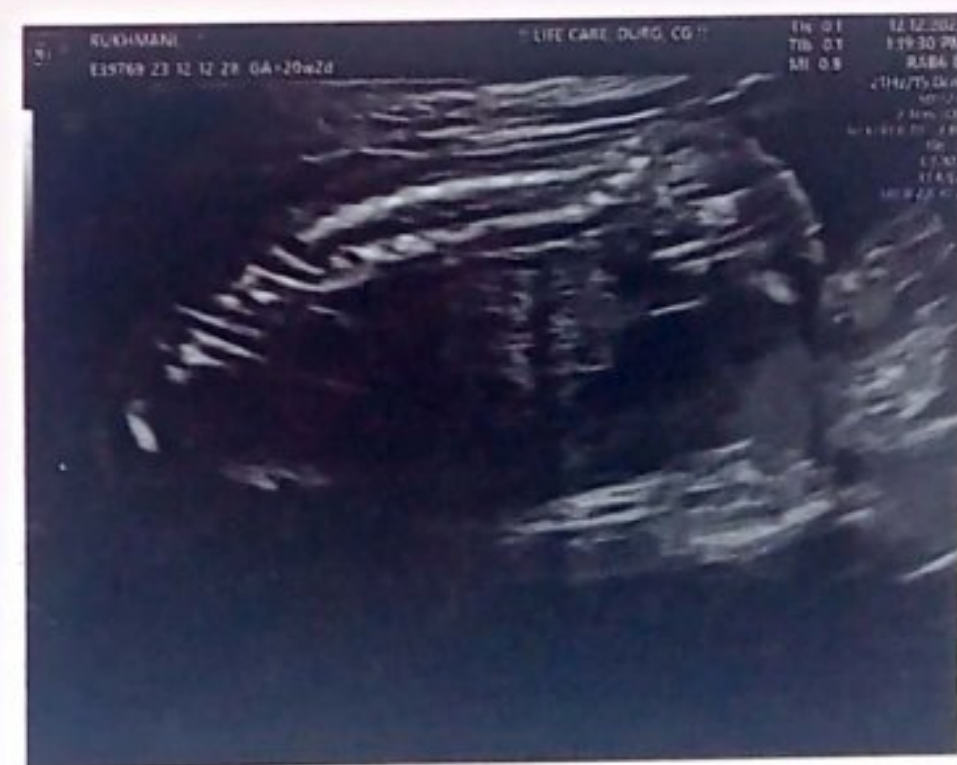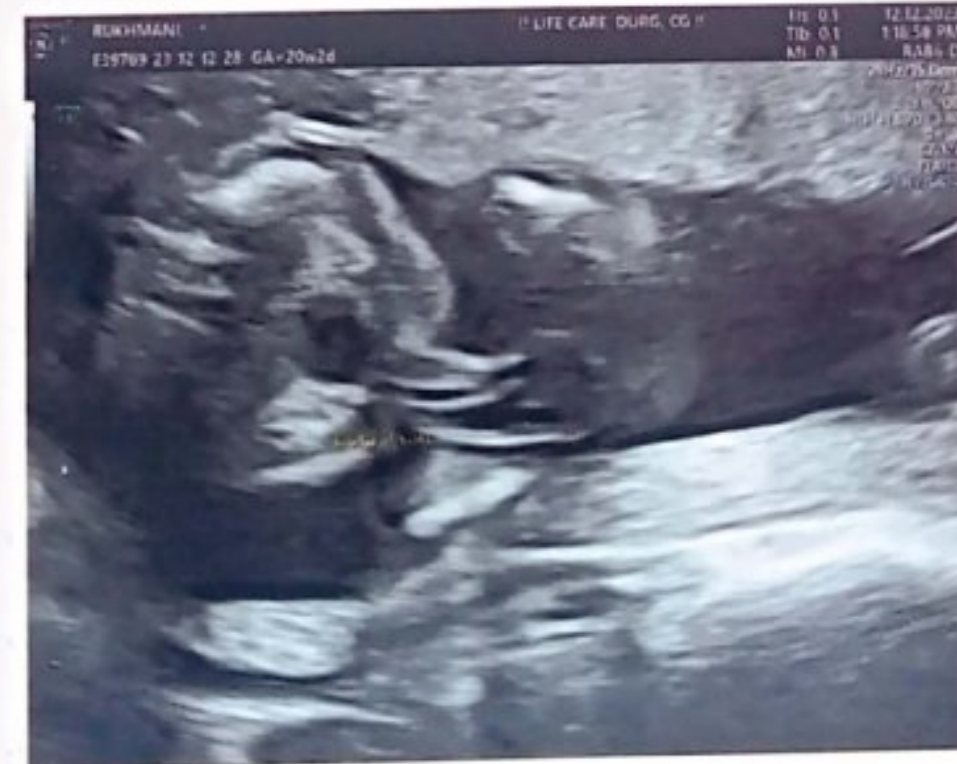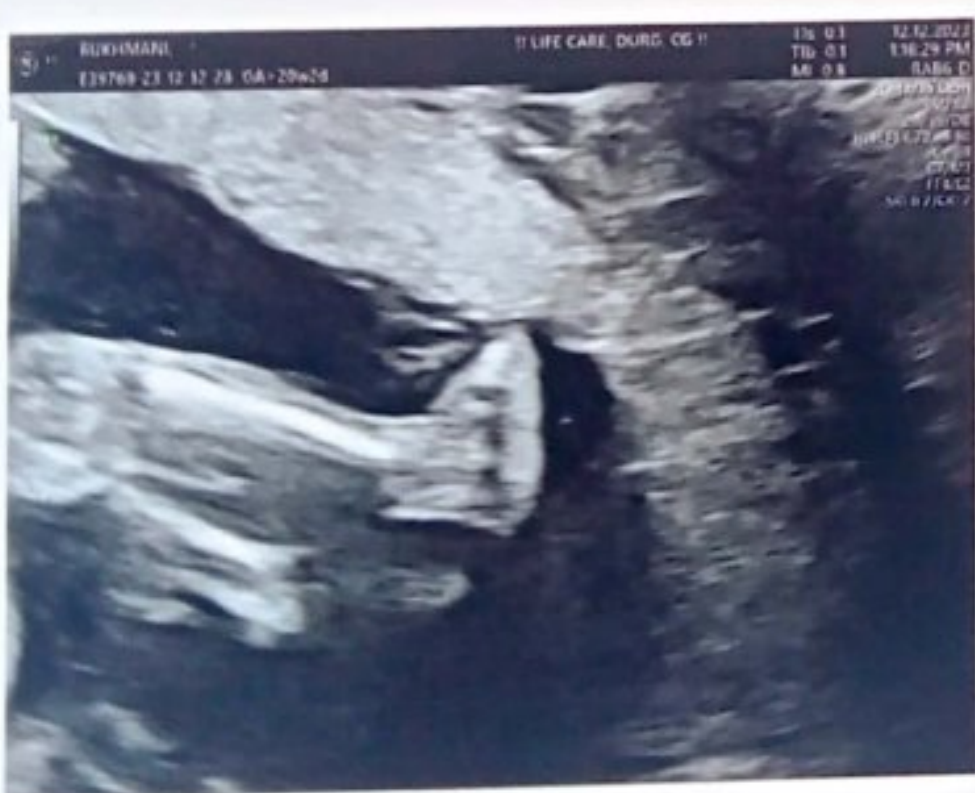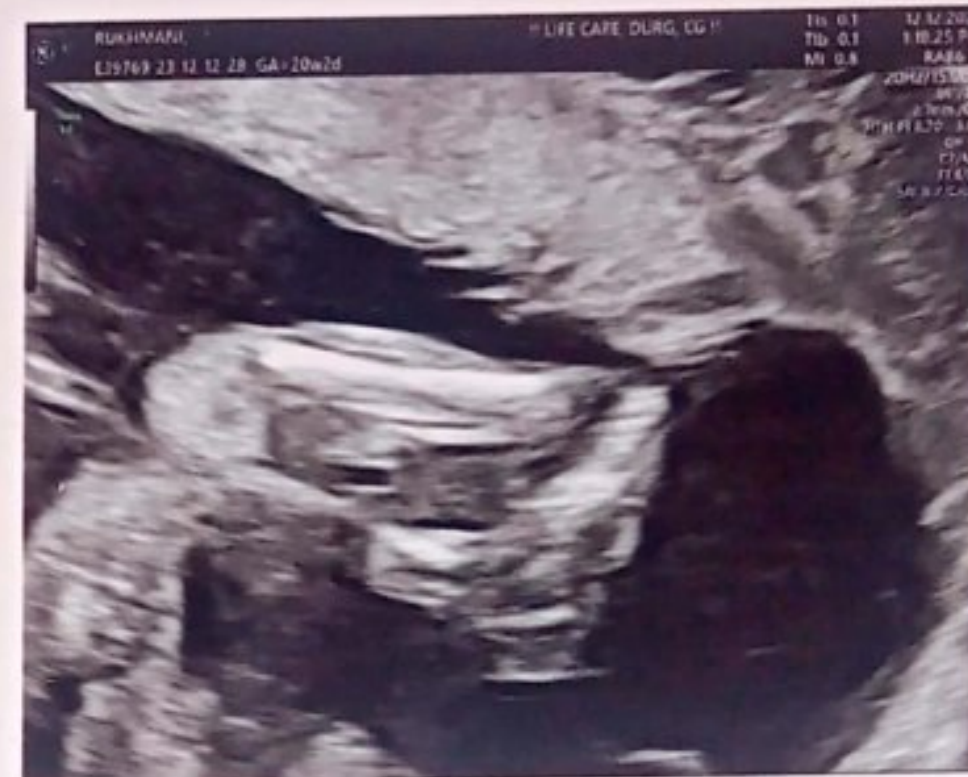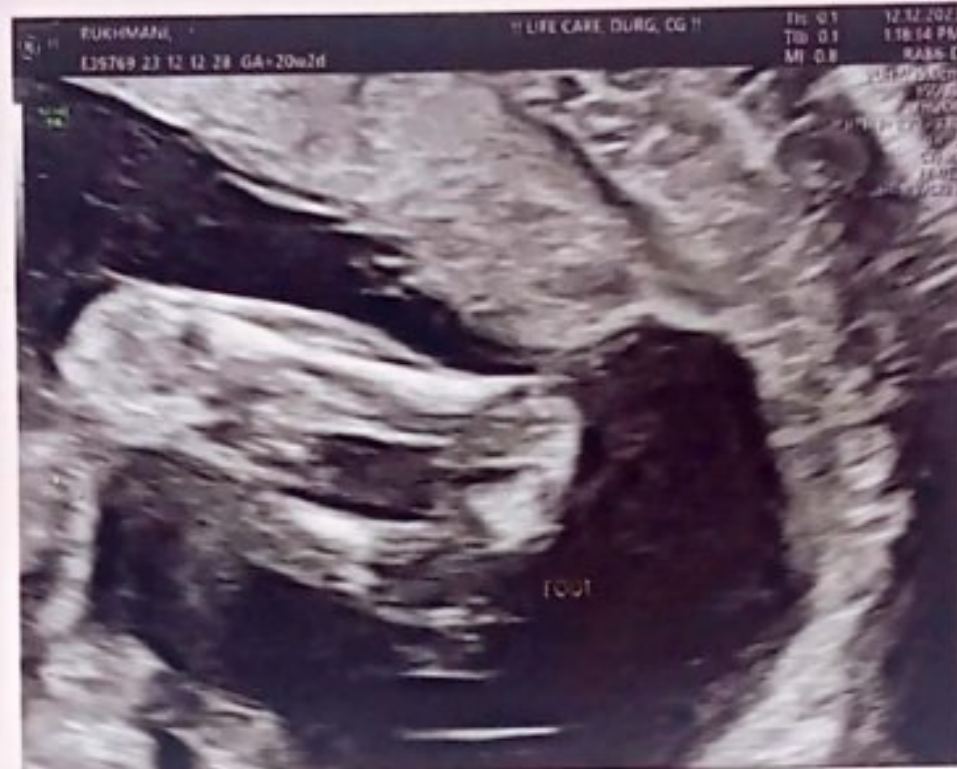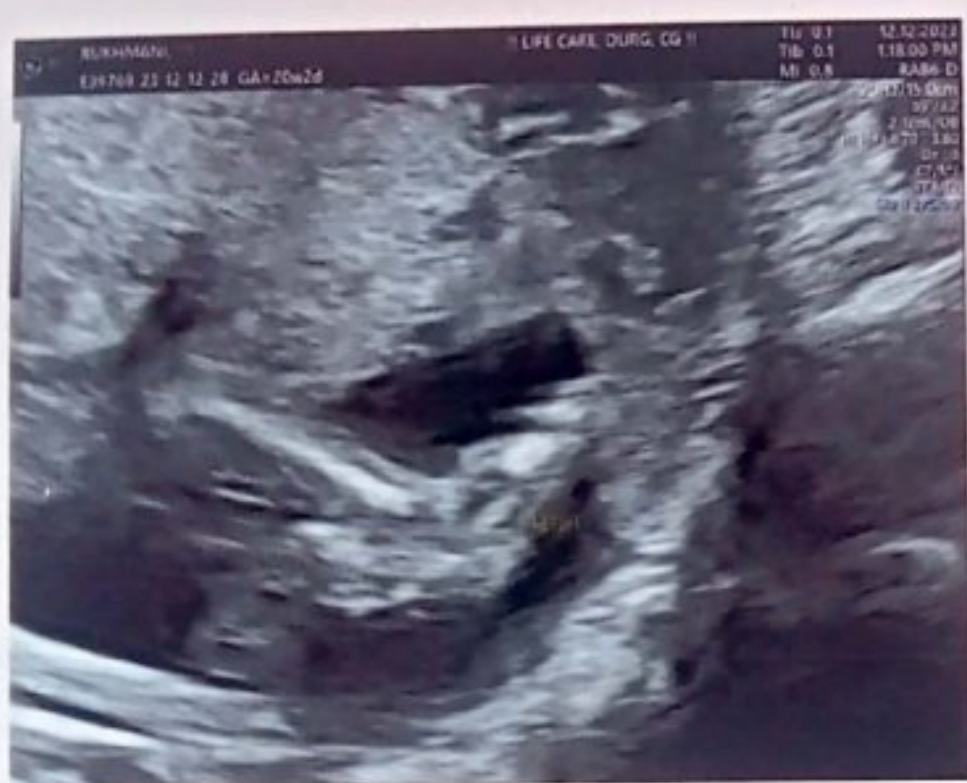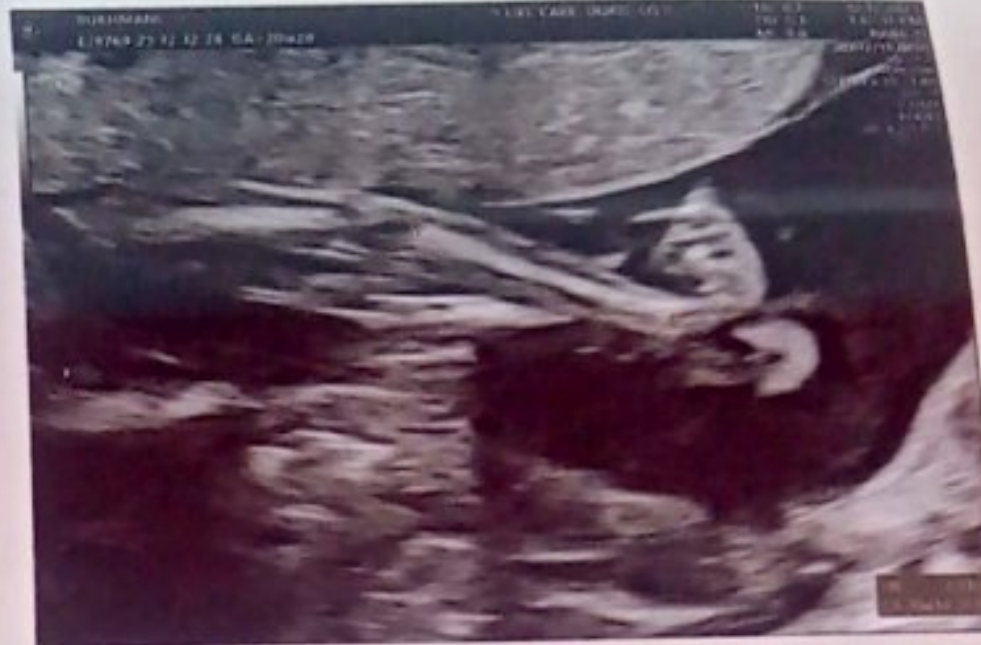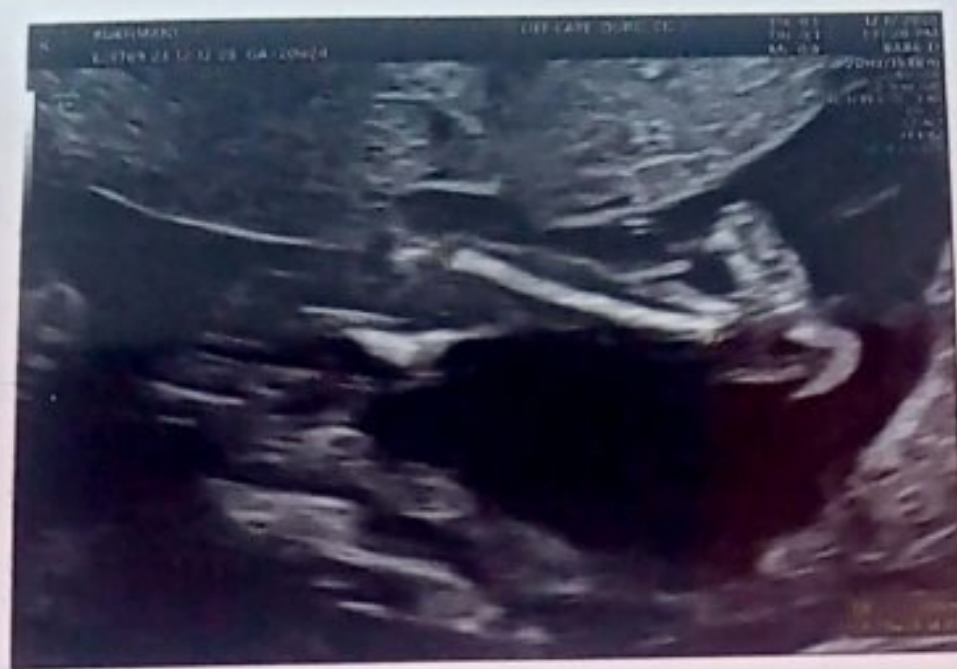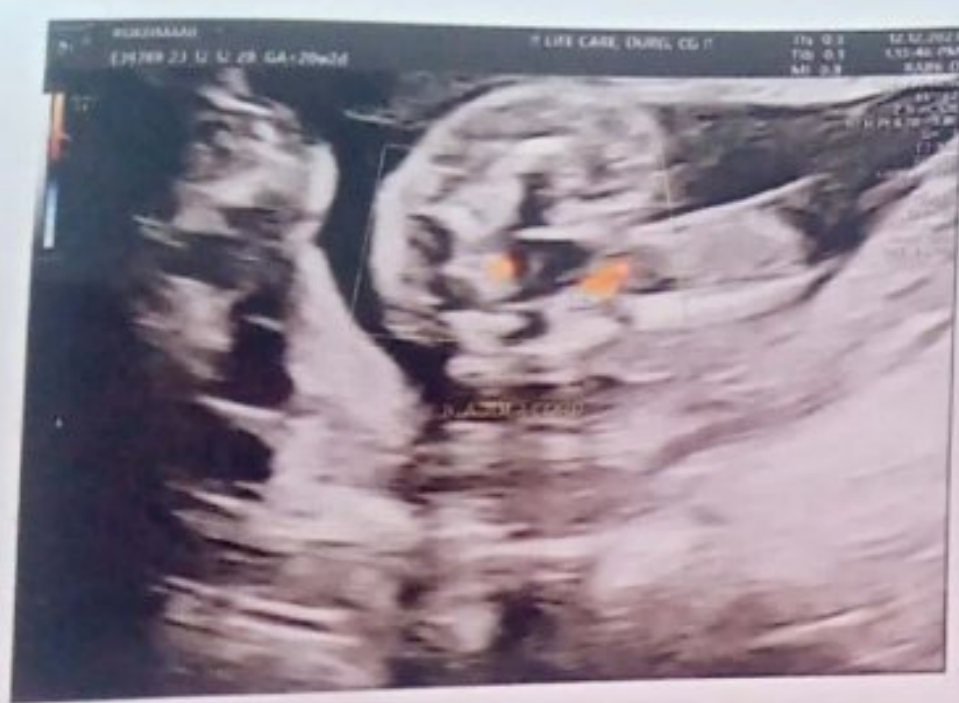These reports are for assisting doctors, physicians in their treatment and not for medico legal purpose and should be related clinically.



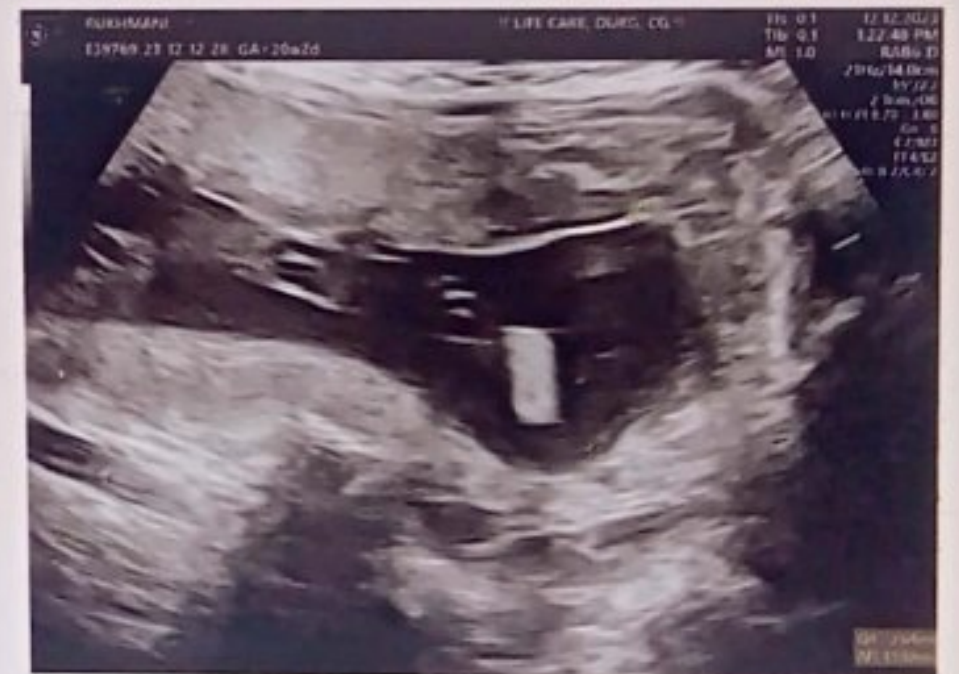
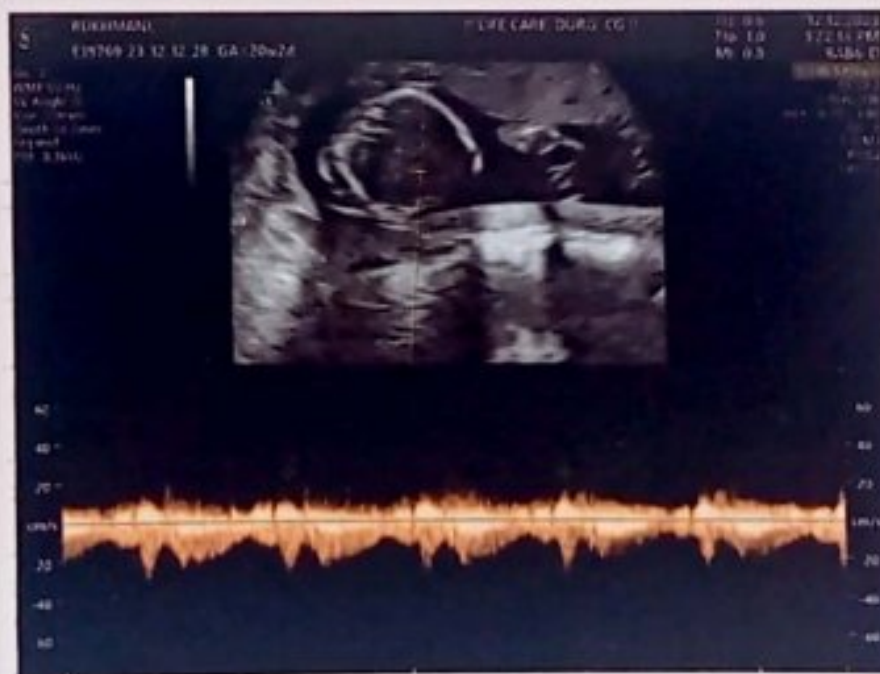
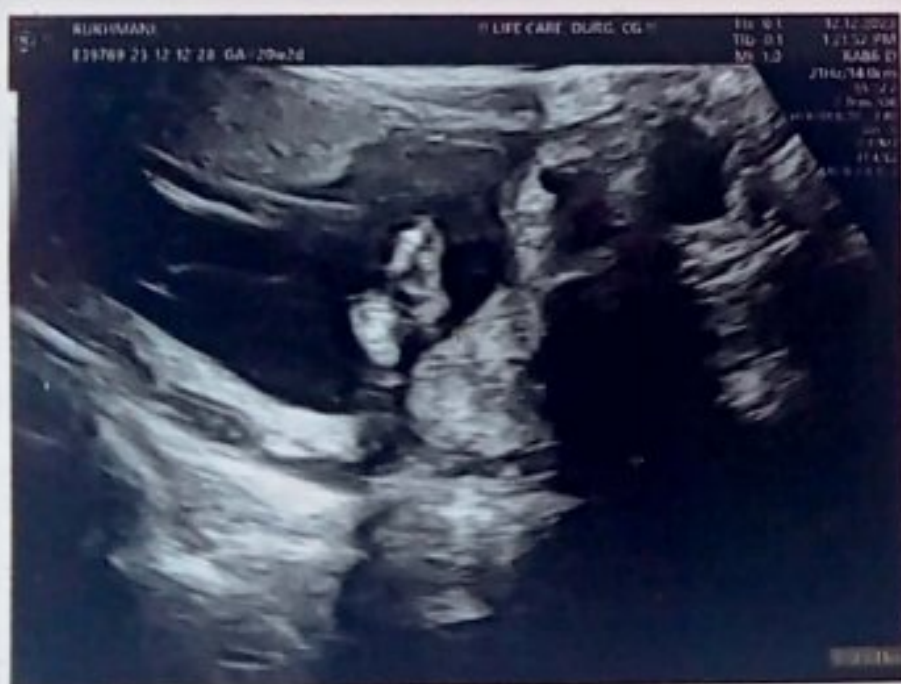
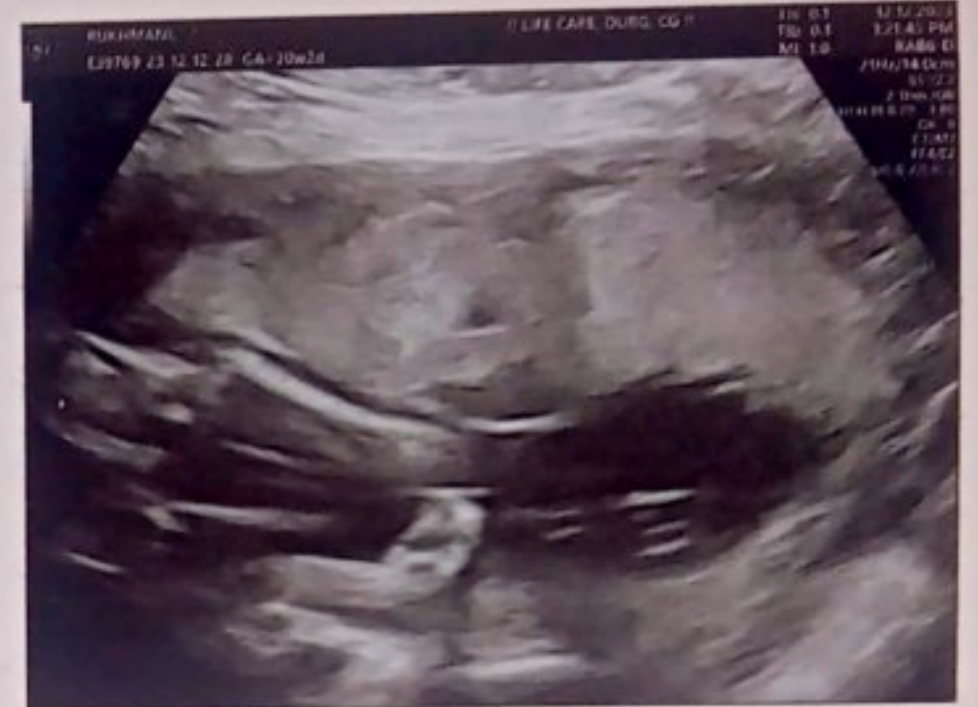
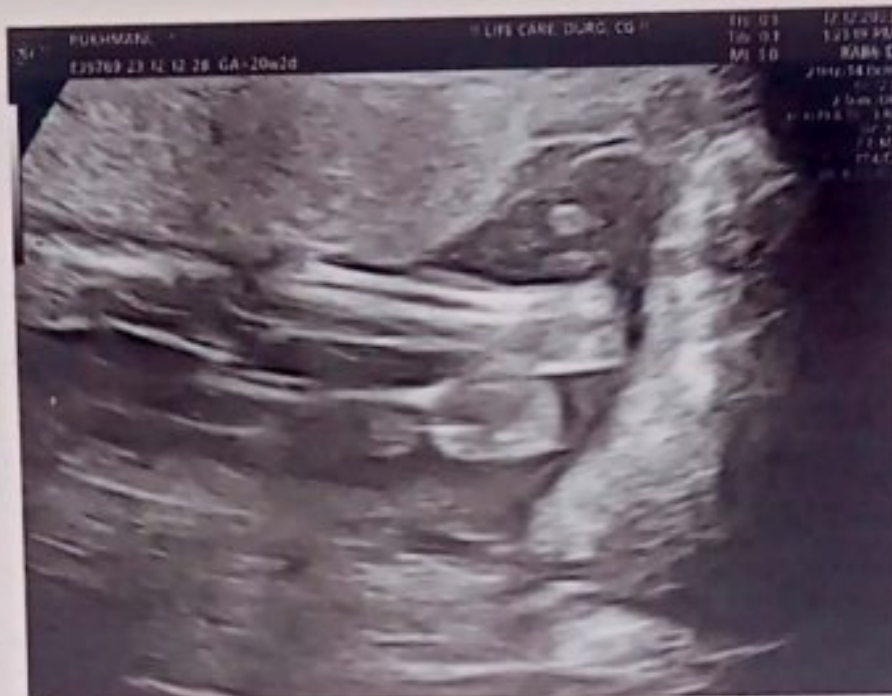
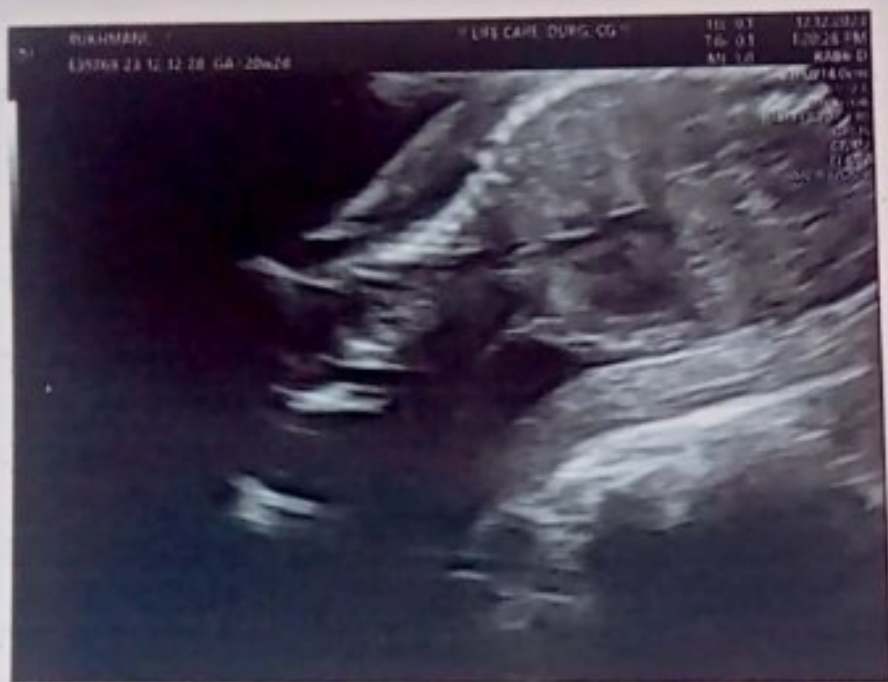
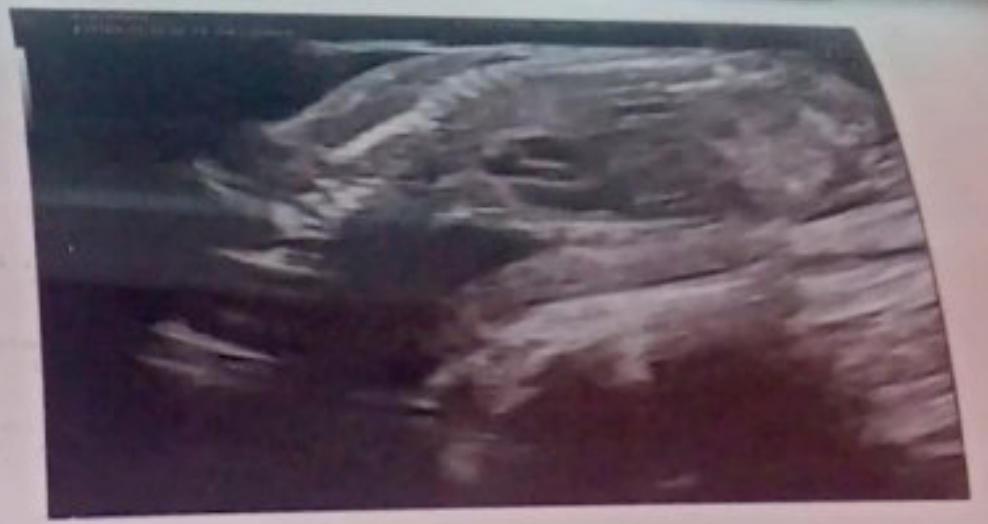
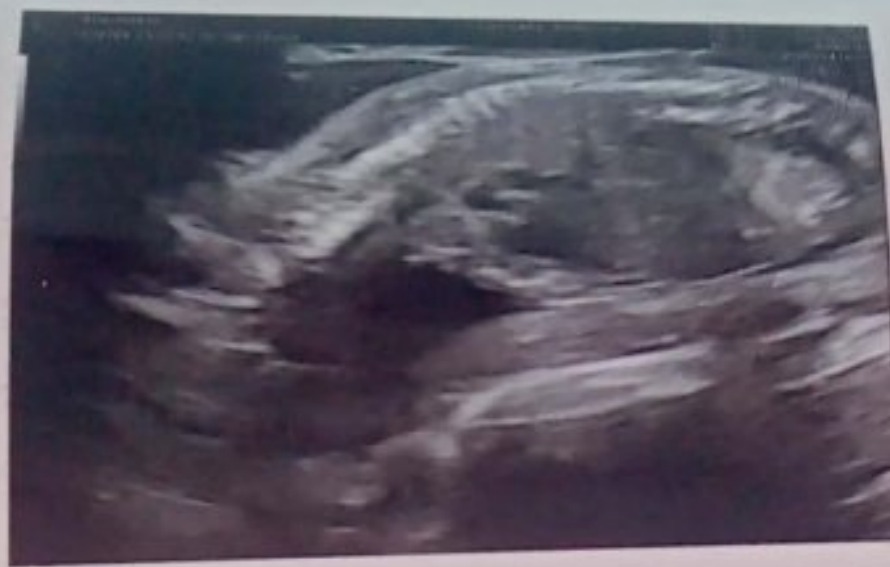
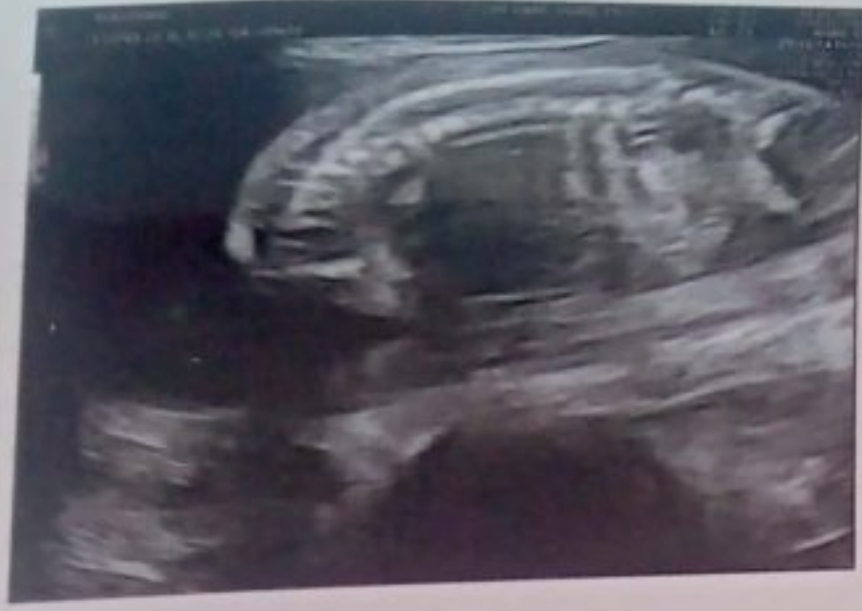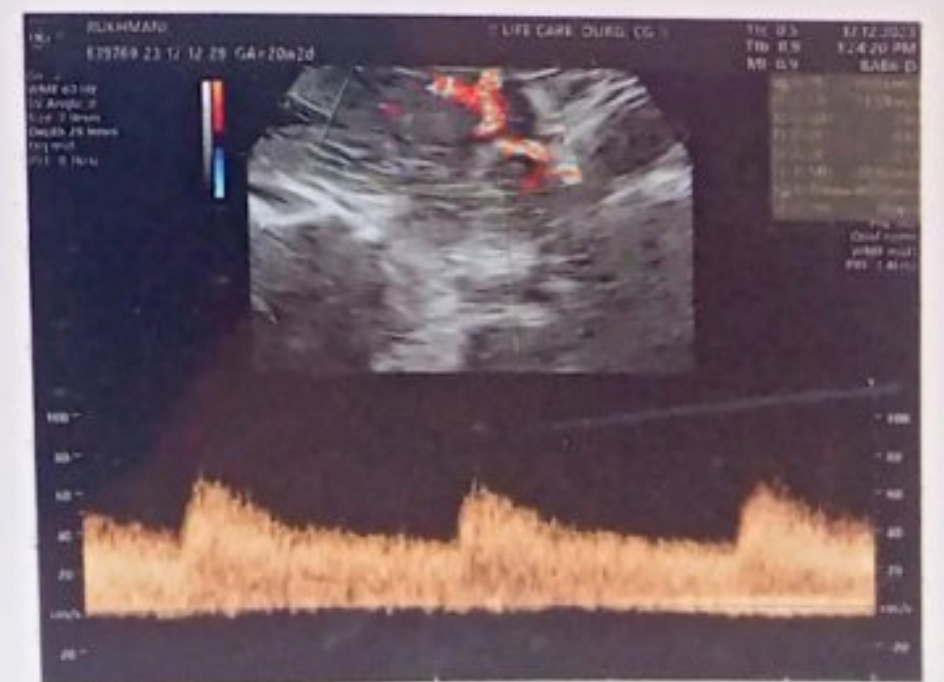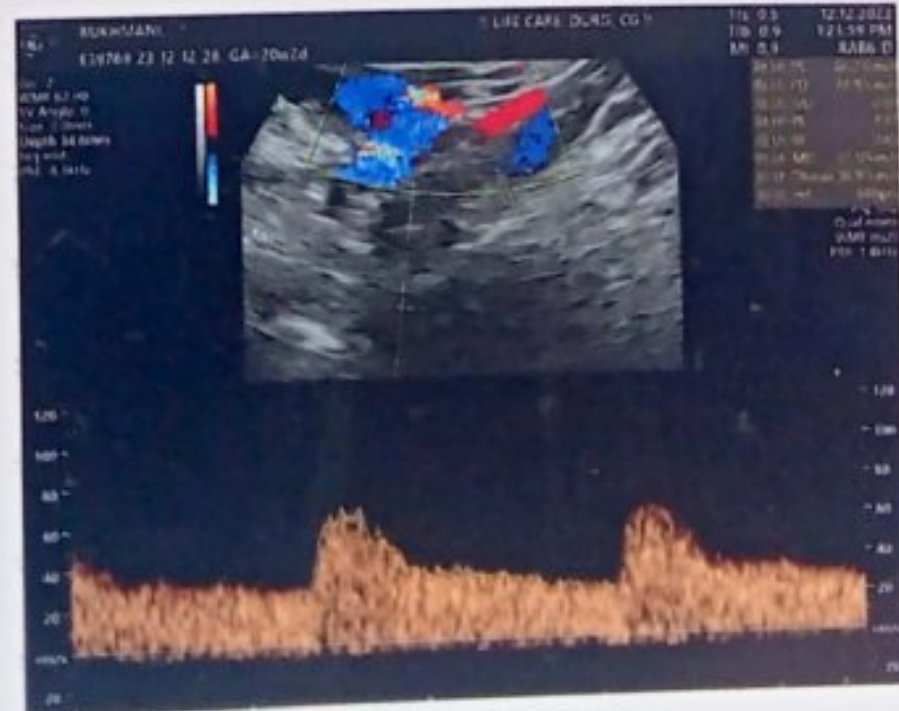




9 LIFE CARE DURC, CG 1

RUHMANN, RUSIMANN  
 12/12/2023 12:13:28 PM  
 12/12/2023 12:13:28 PM  
 12/12/2023 12:13:28 PM

Parameter	Value	Unit	Reference
IMV	23.07	cm/s	17.7%
TRV	10.06	cm	10e3d
AC (Head)	30.73	cm	10e3d
HC (Head)	30.43	cm	10e3d
FL (Femur)	7.07	cm	10e3d
HL (Humerus)	7.08	cm	10e3d
PL (Pulmonary)	2.51	cm	10e3d
AL (Abdominal)	2.74	cm	10e3d
ML (Muscle)	2.86	cm	10e3d
SL (Spine)	1.53	cm	10e3d
CL (Cervical)	1.95	cm	10e3d





12/12/23

① Mrs. Rukhmani Sahu

Age - 32 y/f

Quadruple Monkey

DOB - 16/08/1991

LMP - 23/07/2023

Height - "5" feet

Weight - 68 kg