



Dr. Ulhas L. Mahajan MBBS, DCH, DMRD

MMC Reg. No. 87181

Consultant Radiologist

MAHAJAN

DIAGNOSTIC AND IMAGING CENTRE

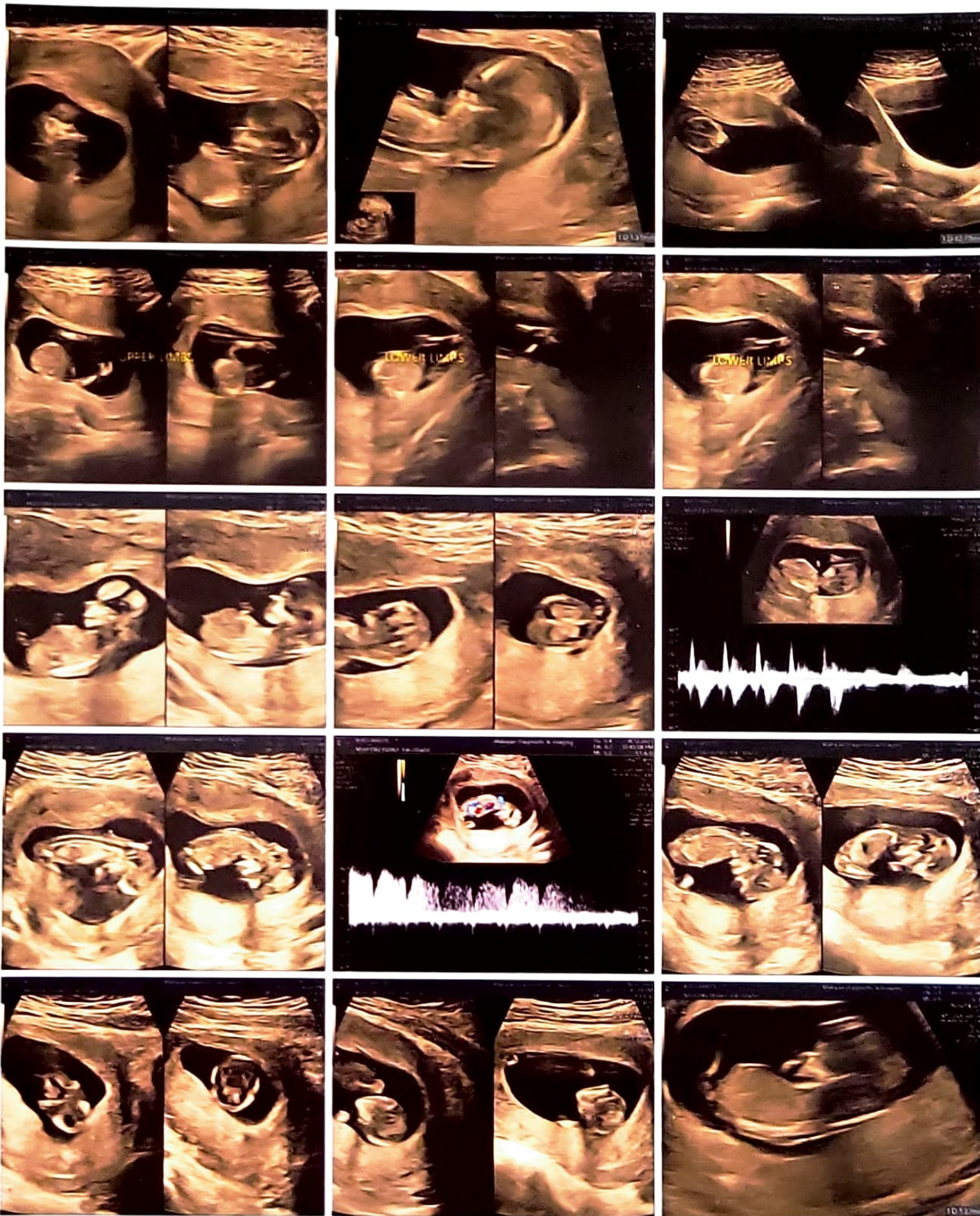
X-ray - 4D Sonography - Color Doppler

Main Road, Khaparkheda, Dist. Nagpur | Ph : (Clinic) 93072 87554

Timings : 10 am - 6 pm & (By appointment only 7 pm - 8 pm) | Sunday by appointment & Monday Closed

Name: KIRTI BHUTE

Date: 16-Dec-2023



Pt.Name -- KIRTI BHUTE	R.NO.- MDICOB2312063
ADVISED BY DR SAMIKSHA TANDULKAR	Date. 16-12-2023

OBSTETRIC ULTRASONOGRAPHY

(Using Ge voluson E8 BT 20 Color Doppler With Convex And Linear Probes))

LMP= 18-09-2023 GA by LMP- 12 wks 5 days EDD BY LMP -24-06-2024

- ❖ *Bulky gravid Uterus seen with single intrauterine gestational sac noted,*
- ❖ *-Foetal poles well seen with foetal CRL =63mm,*
- ❖ *-Foetal movement & cardiac activity well appreciated sonically (fhr-161/M)*
- ❖ *-Placenta –Appears Developing Posteriorly*
- ❖ *Nuchal Translucency appears within normal limits- NT- 1.5MM*
- ❖ *Fetal nasal bone seen*
- ❖ *Ductous venosus waveforms appears within normal limits*
- ❖ *-Internal os appears closed.cervical length -3.5CM*
- ❖ *– No sonic evidence of any obvious abnormal intra-uterine collection*
- ❖ **-MGA by USG= 12 wks 6 days (+/-2wk approx)**
- ❖ **EDD BY USG = 24-06-2024 (+/- 15 day's approx)**
- ❖ **IMPRESSION:-,**
- **Single Live Intrauterine Pregnancy Of Mean Gestational Age-12 wks 6Day (+/-2wk approx)**

*Clinical correlation & follow-up for level II (anomaly) scan at 18 -20 wks suggested**- (I Dr Ulhas Mahajan declare that while conducting sonography I have neither detected nor disclosed the sex of fetus to anybody in any manner)*
Dr Ulhas Mahajan