

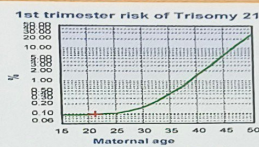
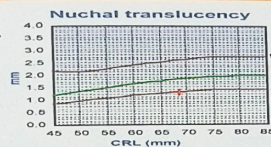
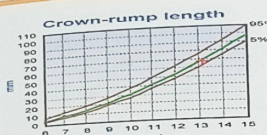


Dr. Supriya Maheshwari
ULTRASOUND & MAMMOGRAPHY CENTER

Dr. Supriya Maheshwari
M.D. Radiodiagnosis Reg. No.: 11111

Vessels	S/D	RI	PI	PI Percentile	Remarks
Right Uterine Artery	3.4	0.7	1.42	31.9%	No early Diastolic notch seen
Left Uterine Artery	4.1	0.76	1.62	54.4%	No early Diastolic notch seen
Mean Uterine Artery			1.52	44%	
Ductus venosus	3.4	0.71	1.23		PSV=41 Normal waveform Pattern

Impression :- Single live Intrauterine gestation corresponding to a gestational age of 13 Wks 1 day Gestational age assigned as per biometry (CRL)



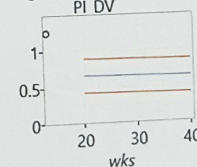
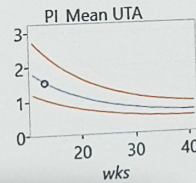
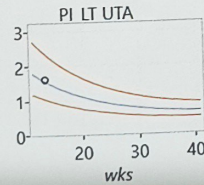
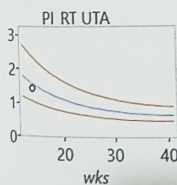
Please note that all anomalies can not be detected all the times due to various technical and circumstantial reasons like gestation period, fetal position, quantity of liquor etc. The present study can not completely confirm presence or absence of any or all the congenital anomalies in the fetus which may be detected on post natal period. Growth parameters mentioned herein are based on International Data and may vary from Indian standards. Date of delivery (at 40 weeks) is calculated as per the present sonographic growth of fetus and may not correspond with period of gestation by L.M.P. or by actual date of delivery. As with any other diagnostic modality, the present study should be correlated with clinical features for proper management. Except in cases of Fetal Demise or Missed Abortion, sonography at 20-22 weeks should always be advised for better fetal evaluation and also for base line study for future reference.

Declaration of Doctor/Person conducting ultrasonography/image scanning

I, DR SONAM VERMA declare that while conducting sonography on MS ISHA PATEL, I have neither detected nor disclosed the sex of the fetus to anybody in any manner

DR SUPRIYA MAHESHWARI
MD, RADIOLOGY
CONSULTANT RADIOLOGIST
Reg No : 11111

DR SONAM VERMA
FETAL MEDICINE SPECIALIST MD,
RADIOLOGY
CONSULTANT RADIOLOGIST
Reg No : 18797



E1/21, Gate No. 09, Arera Colony, Bhopal, 462016 (M.P.)
TIMING : 10.30 am - 07.30 pm
(Saturday Evening & Sunday Closed)

0755-4276589
0755-2476589
+91 9826057204



Dr. Supriya Maheshwari
ULTRASOUND & MAMMOGRAPHY CENTER

Dr. Supriya Maheshwari
M.D. Radiodiagnosis Reg. No: 11111

Patient Name: **MRS. SHASHA PATEL**
Patient Id: **12765**
Ref Phy: **DR. NEERA GOYAL**

Date: **16/12/2023**
Age/Sex: **21 Years / FEMALE**
Contact No:

Examination : Obstetric USG of First Trimester Scan Report (Level -1)

Dating	LMP	GA		EDD
By LMP	LMP: 17/09/2023	Weeks	Days	
By USG		12	6	23/06/2024
		13	1	21/06/2024
AGREED DATING IS (BASED ON Biometry)				

Single live intrauterine gestation

OBSTETRIC USG STUDY

Fetus : Single
Fetal Movement : Adequate
FCA : 166/ bpm
Liquor : Normal
Placenta : RT LATERAL

Biometry (Headlock)

CRL	68.3 mm	13weeks 1 days
CERVIX	36.6 mm in length with closed os & canal.	

Aneuploidy markers:

Nuchal Translucency	1.3 mm	Normal	19% + - + - +
Both Nasal Bones	2.1 mm	Normal	
Umbilical cord	3 vessels		
Tricuspid flow	NO TR		
Ductus venosus	Normal continues forward flows.		

Fetal anatomy :

Head :	shape & size normal , Neck: normal , Spine: normal, Choroid plexus , Cerebral peduncles ,intracraniallucency , AD normal.
Face:	Orbits, lenses, PMT, mandible gap sign normal.
Thorax:	Lung parenchyma , CT ratio , diaphragm normal.
Abdomen :	Normal ant. Abdominal wall & cord insertion , stomach , bowel loops, Kidneys , UB are normal.
Extremities:	Both upper & lower limbs are normal. Hands , feet seen.
Fetal spine :	Normal.



E1/21, Gate No. 09, Arera Colony, Bhopal, 462016 (M.P.)
TIMING : 10.30 am - 07.30 pm
(Saturday Evening & Sunday Closed)

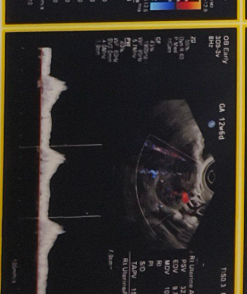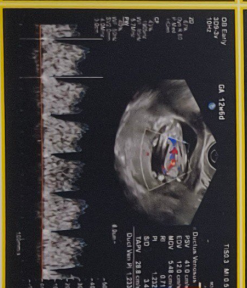
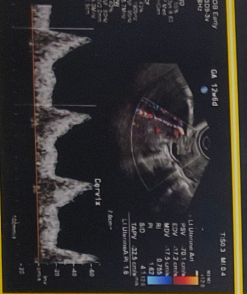

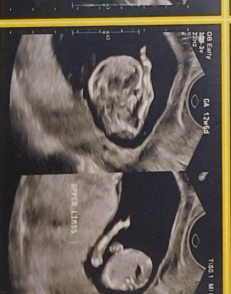
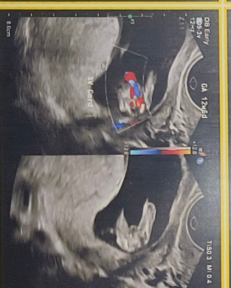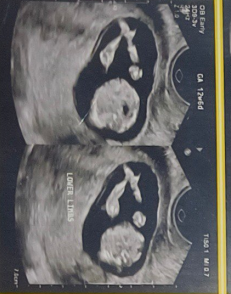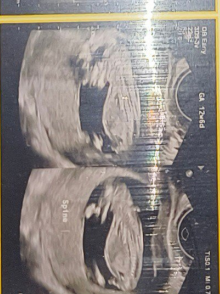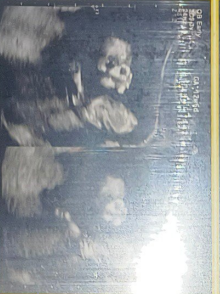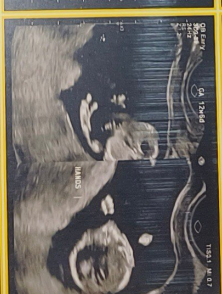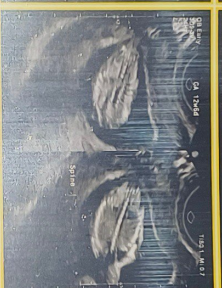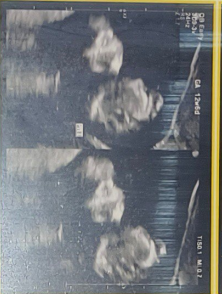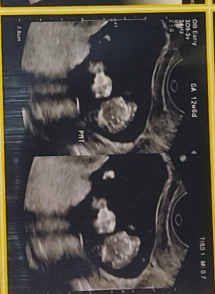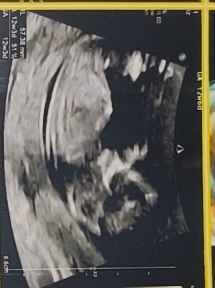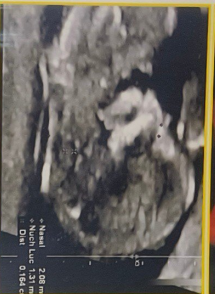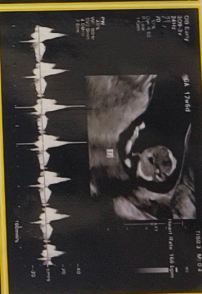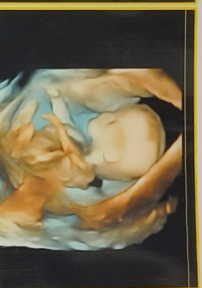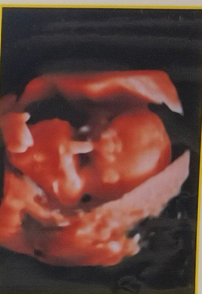0755-42
0755-24
+91 9821

Name : ISHA PATEL 21Y/F

DR SUPRIYA MAHESHWARI ULTRASOUND CENTRE

16 Dec 2023 Study : Free Form



DR SUPRIYA MAHESHWARI ULTRASOUND CENTRE

Name : ISHA PATEL 21Y/F

16 Dec 2023 Study : Free F

