



भारतीय विशिष्ट पहचान प्राधिकरण UNIQUE IDENTIFICATION AUTHORITY OF INDIA

पत्ता: D/O: सलीम मनियार, क्रांति नगर,
खाडगाव रोड, लातूर, लातूर, लातूर,
महाराष्ट्र, 413512

Address: D/O: Salim Maniyar,
Kranti Nager, Khadgav Road,
Latur, Latur, Latur, Latur,
Maharashtra, 413512



1947
1800 180 1947



help@uidai.gov.in

WWW

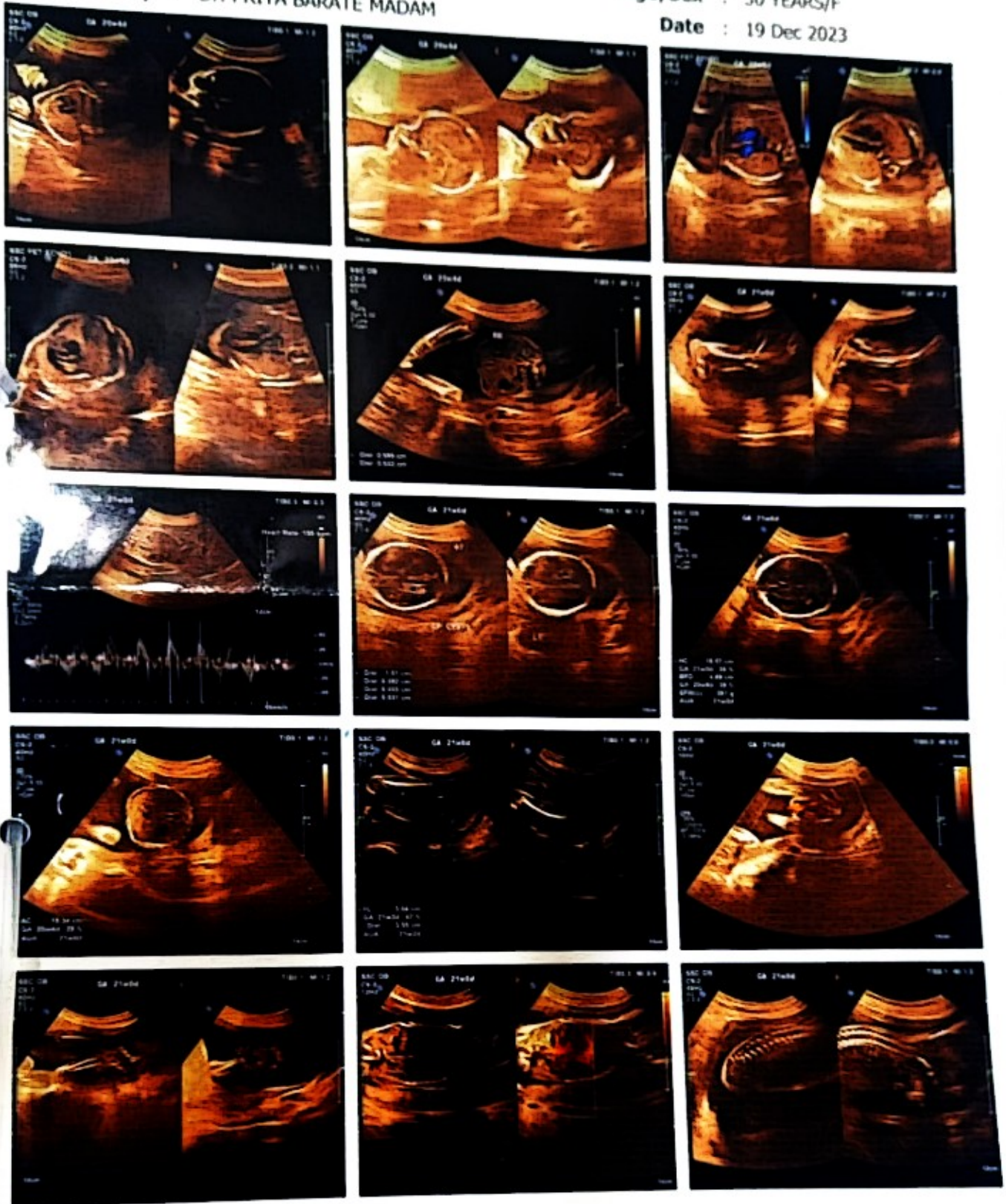www.uidai.gov.in



P.O. Box No.1947,
Bengaluru-560 001

Name : MRS. MADJABIN SALIM TAMBOLI
Ref By : Dr. PRIYA BARATE MADAM

Age/Sex : 30 YEARS/F
Date : 19 Dec 2023





Bilateral choroid cysts are seen measuring 10 x 3 mm on right side and 5 x 5 mm on left side.

Fetal bilateral renal pelvis are mildly prominent. Right renal pelvis AP diameter = 5.9 mm and left renal pelvis Ap diameter = 5.3 mm.

Uterine artery screening Doppler : Mean PI - 1.2 (Normal).

IMPRESSION:

- ❑ Single live intrauterine fetus of average 21 weeks 0 days gestation (expected gestational age by CRL USG done outside is 20weeks and 4days).
- ❑ Bilateral choroid cysts.
- ❑ Mildly prominent fetal bilateral renal pelvis.
- ❑ Moderate polyhydramnios.

Suggest : correlate with marker test and follow up for interval growth and evolving anomalies.

P.N. All measurements including estimated fetal weight, are subject to statistical variations. Not all anomalies can be detected on sonography. I Dr Sarita Pate declare that while performing sonography on Mrs. MALJABIN SALIM TAMBOLI. I Have neither detected nor disclosed the sex of the fetus to anybody in any manner.

Thanks for referral.

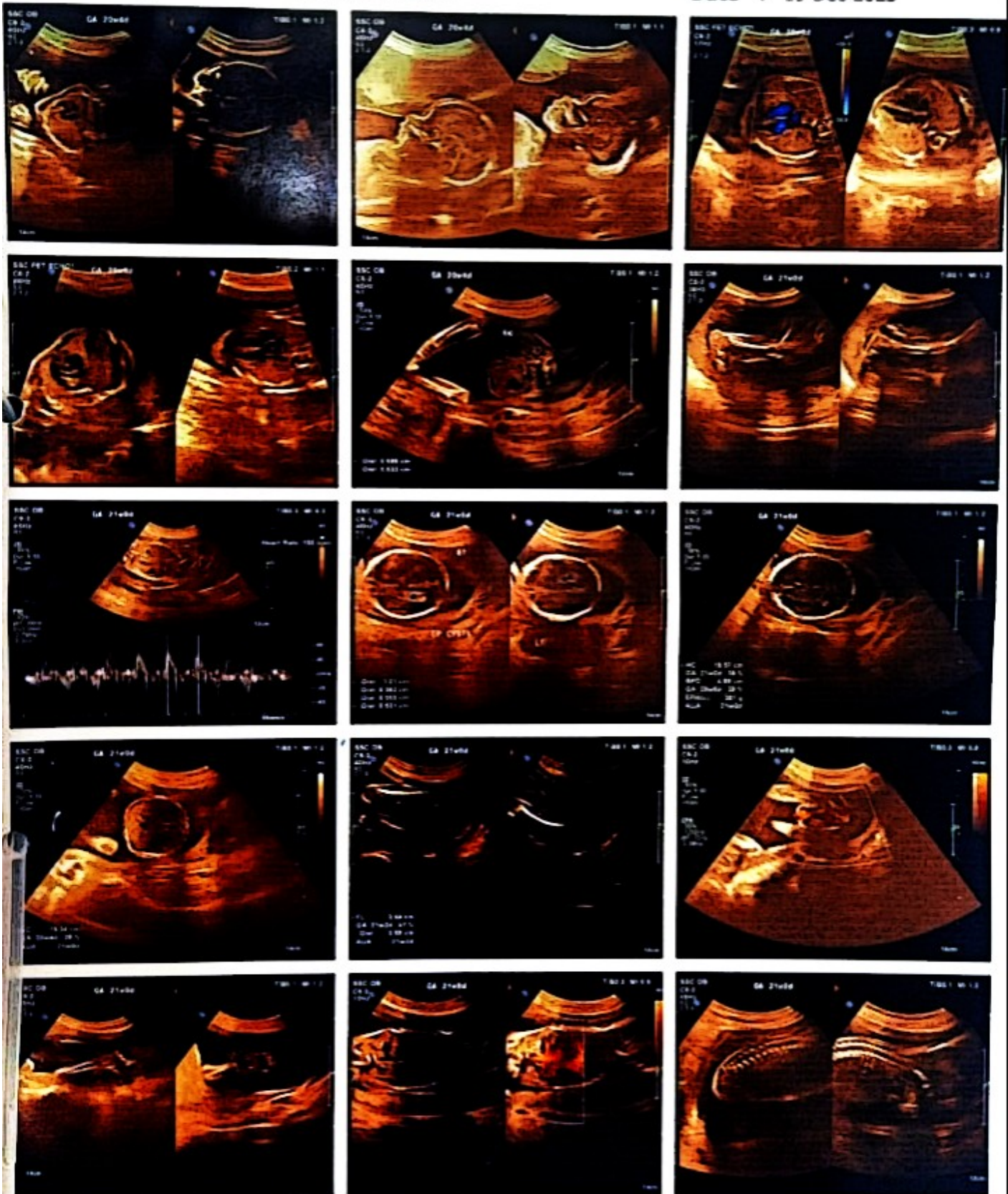
Dr. Sarita S. Pate(Sontakke)
M.B.B.S.,D.M.R.E

Name : MRS. MAIJABIN SALIM TAMBOLI

Age/Sex : 30 YEARS/F

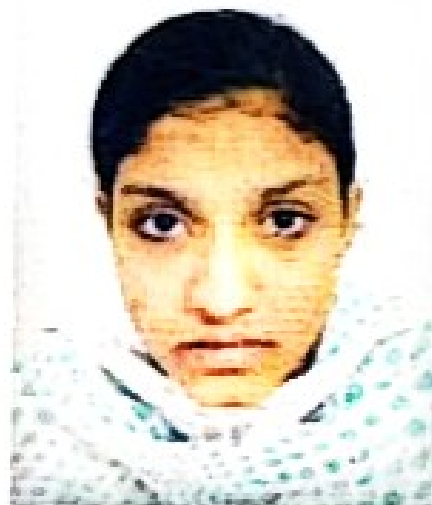Ref By : Dr. PRIYA BARATE MADAM

Date : 19 Dec 2023





भारत सरकार
GOVERNMENT OF INDIA



महेजबीन बेगम सलीम मनियार
Mahejabin Begam Salim Maniyar

जन्म वर्ष / Year of Birth : 1994
महिला / Female



8614 6670 2747

आधार — आम आदमी का अधिकार



सारा सोनोग्राफी सेंटर



डॉ. सरीता पाटे-मोनदक्के

MBBS, DMRE

सातवाडी रुग्ण

Reg No. 2007/19/3503

Name : MRS. MAIJABIN SALIM TAMBOLI
Ref by: Dr. PRIYA BARATE MADAM

Age/Sex: 30 YEARS/F
Date: 19 Dec 2023

ANOMALY SCAN

Single fetus is seen in uterus in changing position.

Cardiac pulsations are well seen (FHR= 155 b/min).

Liquor is More (AFI = 19.8 cm).

Placenta is fundal and anterior, distal edge of placenta is 10.8cm from internal Os.

Cervical length is 3.0 cms. Os is closed.

Targeted Scan reveals :

Lateral Ventricles	5.7,5.7mms	Cord insertion	Normal
Cerebellum	19.5mms	3 Vessels cord seen	Normal
Cisterna magna	6.4mms		
Nuchal fold	2.59mms	Urinary Bladder =	Normal
Facial Structures	Normal	Diaphragm =	Normal
Spine	Normal	Bowel =	Normal
Upper extremities	Normal	Stomach =	Normal
Lower extremities	Normal	Four chambers =	Normal
No obvious mediastinal shift seen at present.		Out flows =	Normal

Foetal biometry :

BPD	4.88cm		20weeks	6days		
HC	18.57cm		21weeks	0days		
AC	15.34cm		20weeks	4days		
FL	3.54cm		21weeks	2days		
LMP	25/07/2023	GA (LMP)	21 weeks	0 days	EDD (LMP)	30/04/2024
AUA	21weeks	0days	EDD (AUA) according to CRL USG done outside is 03/05/2024			
EFW	381gm (+ 56gms)(61 percentile).					

Contd.....

1 | Page