

P. + name - Neha Anand Sable
19/f

H - 139 cm

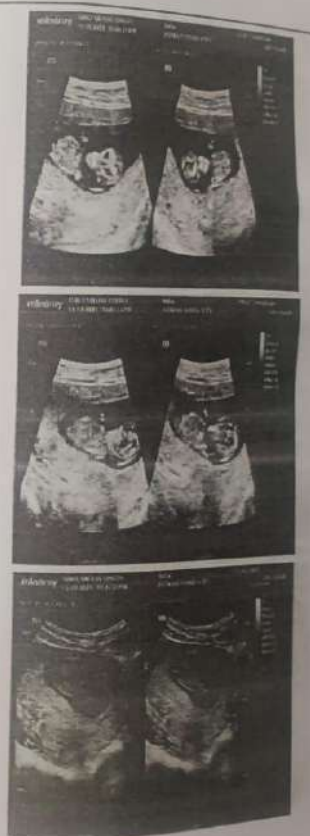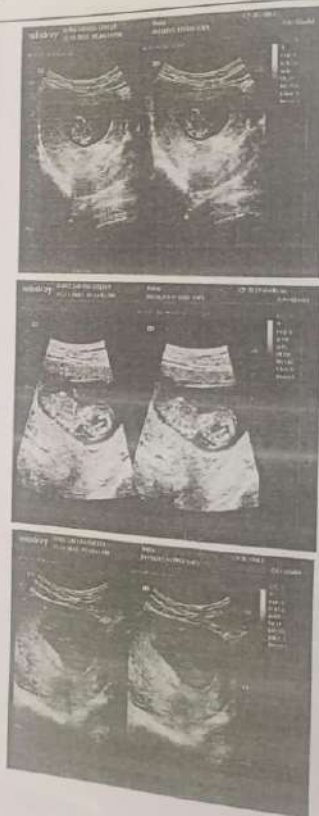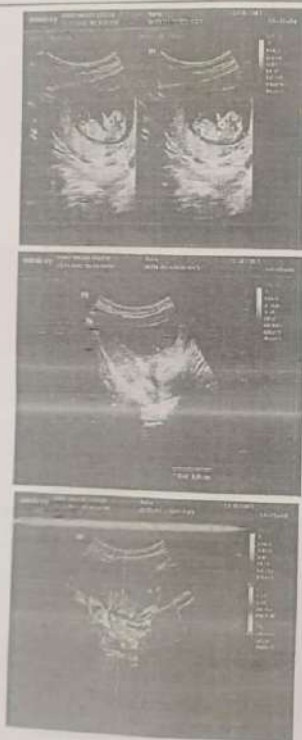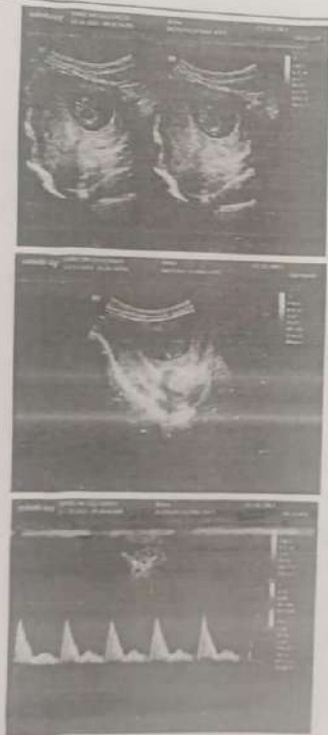W - 46 kg.

Date of Birth 28/05/2005

Patient ID: 2023120201
Name: Mrs. Neha
Sex: F

Date: 15-Dec-2023
Study: OBSTETRIC
Ref By: Dr. Bhagyashri Ahirrao Madam

Dr. Nilesh Ahirrao



SHREE SAI SONOGRAPHY CENTRE

DEVGAON (RANGARI) TQ. KANNAD DIST. AURANGABAD

DEVGAON (RANGARI)

Phone No: 9822316328

Patient ID: 2023120201

Name: Mrs. Neha

Sex: F

Date: 15-Dec-2023

Study: OBSTETRIC

Ref By: Dr. Bhagyashri Ahirrao Madam

EARLY PREGNANCY

E/o single live intrauterine pregnancy

Internal OS is closed cervix length is 31 mm

No c/o sac separation

Chorionic tissue well identified.

Fetal head, body & limbs well seen.

NT - 2.3 mm

C.R.L. 41 mm 11 wks 0 day

Activity in CRL ++ FHR 160 /min

No adnexal mass

No POD collection

EDD BY USG 05/07/2024

EDD BY LMP 28/06/2024


OPINION - 11 wks 00 day live intrauterine pregnancy with Raised NT --2 mm with moderate skin oedema all over head and neck at this gestationADV--2ND opinion and double marker tests....

Adv. Detail anomaly scan at 18 wks

Note:- All anomalies are not detected due to liquor, foetal presentation, maternal abdominal thickness and various limitation at the time of scanning.

I (DR. Nilesh Ahirrao) neither detected the sex of the foetus at the time of scanning nor disclosed the same to anybody in any manner.

Reported By


Dr. Nilesh Kanhaiyalal Ahirrao
Shree Sai Sonography Center, Devgaon (R.)
Reg. No. 2002/03/904