

1/2/24

Ms. Aditi Jain

Age - 24 Y / F

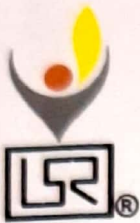Double Marker

DOB - 29/07/1999

LMP - 04/11/2024

Height - 5'4"

Weight - 62.0 Kg



**Life
Care**

SCAN & RESEARCH CENTRE

DIAGNOSTIC CENTRE

■ Om Parisar, Arya Nagar, Durg (C.G.) 491 001
Ph : 0788-2355701, 2355702, Mo: 8349999518
E-mail : lsr@lifecarescan.com | website : www.lifecarescan.com

■ Shivanth Complex, Beside Chouhan Estate, Bhalai (C.G.) 490 023
Ph : 0788-4910002, 4910003, Mo: 9109176001
E-mail : isdbhalai@gmail.com | website : www.lifecarescan.com

Free Blood Sample Collection From Home, 24x7 Service



TEST REPORT

Reg. No : 010224/247

NAME: MRS. ADITI JAIN

AGE: 24 YEARS

Date: 01.02.2024

SEX : F

REF. BY.: DR. MANASI GULATI

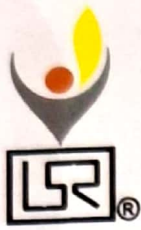DGO, GYN.

TYPED BY - PK

Ultrasonography of gravid uterus (Early anomaly/NT scan)

- ❖ Single live intrauterine fetus with changing lie & unstable presentation is seen at the time of examination.
- ❖ CRL measures 5.20 cm corresponds to 11 weeks 6 days.
- ❖ Foetal cardiac activity is noted. Foetal heart rate 160 b/min.
- ❖ Nuchal translucency-1.7 mm.
- ❖ Intra-cranial translucency- 2.4 mm.
- ❖ Nasal bone (2.2 mm), Tricuspid flow: within normal limits.
- ❖ Ductus venosus flow is normal.
- ❖ Placenta: Anterior wall, upper and mid uterine segment. Grade-0 maturity.
- ❖ OS closed.
- ❖ Both ovaries appear normal in size and echotexture.
- ❖ Cervical length 3.7 cm.
- ❖ Urinary bladder shows normal uniform wall thickness with smooth inner margin.
- ❖ Umbilical cord shows- Single umbilical artery, however needs conformation in anomaly scan.
- ❖ Right UTA
 - Pulsatility index - 0.95
- ❖ Left UTA
 - Pulsatility index - 1.2
 - Mean PI percentile - 1.0
 - Result - Normal

P.T.O.



**Life
Care**

SCAN & RESEARCH CENTRE

DIAGNOSTIC CENTRE

■ Om Parisar, Arya Nagar, Durg (C.G.) 491 001
Ph : 0788-2355701, 2355702, Mo.: 8349999518
E-mail : lsr@lifecarescan.com | website : www.lifecarescan.com
■ Shrivnath Complex, Beside Chouhan Estate, Bhilai (C.G.) 490 023
Ph : 0788-4910002, 4910003, Mo.: 9109176001
E-mail : lsdbhilai@gmail.com | website : www.lifecarescan.com
Free Blood Sample Collection From Home, 24x7 Service



TEST REPORT

NAME: MRS. ADITI JAIN

AGE: 24 YEARS

SEX : F

IMPRESSION :

- ❖ Single intrauterine gestational sac with single live fetus with heart activity seen at the time of examination with gestational age of 11 weeks 6 days.
- ❖ Expected date of delivery by ultrasound: 16.08.2024 +/- 10 days.
- ❖ Uterine artery screen negative for PIH.
- ❖ Measured nuchal translucency (1.7 mm) is 80th percentile for present CRL.
- ❖ Umbilical cord shows- Single umbilical artery, however needs conformation in anomaly scan.


Suggest:- Follow up TIFFA (level II) scan between 19-21 weeks.

DECLARATION:- I Dr. Suraj kabra: Declare that while conducting USG, I have neither detected nor disclosed the sex of her fetus to any body in any manner.

All measurement including estimated fetal weight are subject to statistical variations.

Thanks for the reference,
With regards,

Dr. Girish Verma
M.D., D.M.R.D.
Consultant Radiologist


Dr. Suraj Kabra
MBBS, D.N.B.
Consultant Radiologist

Dr. Abhishek Das
MBBS., MD.
Consultant Radiologist

Dr. Sonal Goyal
MBBS, MD
Consultant Radiologist

These reports are for assisting doctors, physicians in their treatment and not for medico legal purpose and should be related clinically.