



MAA Fetal Medicine Center

Patient name	Mrs. DEVISRI SRINIVAS YADAV	Age/Sex	27 Years / Female
Patient ID	111835	Visit no	1
Referred by	Dr. Mounika Sadanand hospital	Visit date	06/02/2024
LMP date	05/11/2023, LMP EDD: 11/08/2024[13W 2D] C-EDD: 16/08/2024[12W 4D]		

OB - First Trimester Scan Report

Real time B-mode ultrasonography of gravid uterus done.

Route: Transabdominal

Single intrauterine gestation

Maternal

Cervix measured 3.50 cm in length.

Right Uterine	0.72	●—+— (1%)
Left Uterine	0.95	●—+— (4%)
Mean PI	0.835	●—+— (3%)

Fetus

Survey

Placenta - anterior, lower segment

placenta covering the os

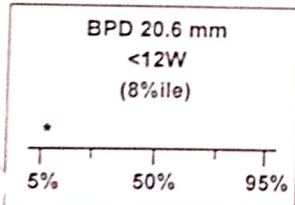
Liquor - Normal

Fetal activity present

Cardiac activity present

Fetal heart rate - 151 bpm

Biometry(Mediscan)



CRL - 62.1 mm(12W 4D)

Aneuploidy Markers

Nasal Bone : Present

Nuchal translucency : 1.67 mm Normal.

Ductus venosus : Normal flow.

Tricuspid regurgitation : Absent.

Fetal Anatomy

Skull / Brain appears normal

Intracranial structures appears normal

Choroid plexuses seen.

Neck seen.

Spine seen.

- NT SCANS • TIFFA • FETAL ECHO • GROWTH & DOPPLER SCANS
- MULTIPLE PREGNANCY • GENETIC COUNSELING & SCREENING • CERVICAL ASSESSMENT
- FOLLICULAR STUDY • ULTRASOUND PELVIS AVAILABLE

7-1-621/10/G2, Sai Manor, S R Nagar, Circle 34, Next to Umesh Chandra Statue, Hyderabad-500 038, Telangana

☎ 7569056789

🌐 www.maafetalmedicine.com

✉ drpriya@maafetalmedicine.com

Page # 1 06/02/24 11:40 AM
like a Mother