

Mrs. Sheela Kumari

2015)

Ht- 5' 1
wt- 66 kg

Guadalupe Marquez

Dr. BITHOU Joseph (Duo)




भारत सरकार
Government of India

भारतीय विशिष्ट पहचान प्राधिकरण
Unique Identification Authority of India

नमस्कार क्रम/ Enrolment No.: 0515/28150/03887

श्रीमती शीला कुमारी चौहान
Sheela Kumari Chouhan
D/O Churnidai Chouhan
Jankariya P.O. Ke Post
P.O. Mohalla ward no. 08
Bansi
Nerhangabad Madhya Pradesh - 461111
9844479832

Signature and



आपका आधार क्रमांक / Your Aadhaar No :

8982 1150 4434

VID : 9104 0344 2903 9745

मेरा आधार, मेरी पहचान



भारत सरकार
Government of India



श्रीमती शीला कुमारी चौहान
Sheela Kumari Chouhan
जन्म तिथि/DOB: 18/05/1990
लिंग/ GENDER: FEMALE

Barcode Code : 98 00 20 11

8982 1150 4434

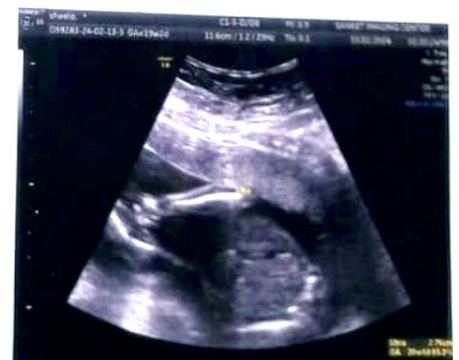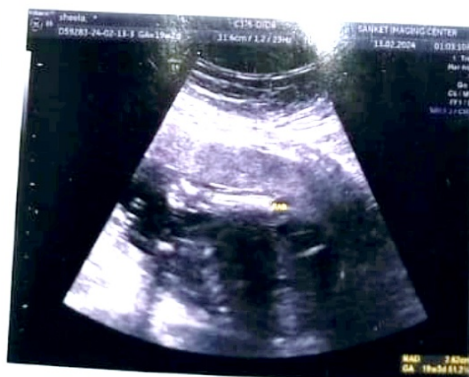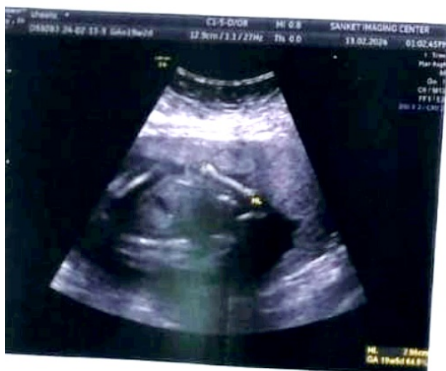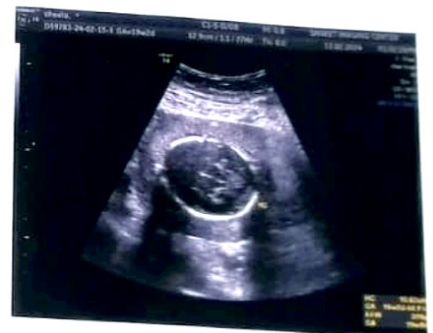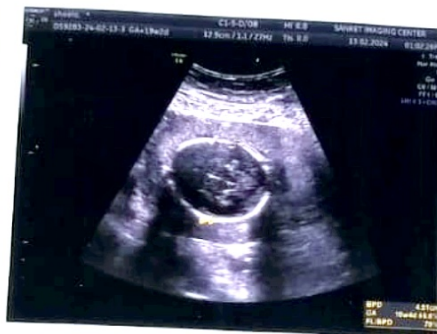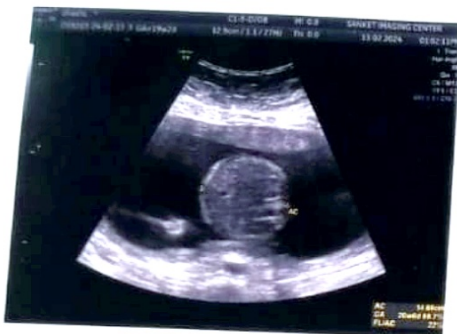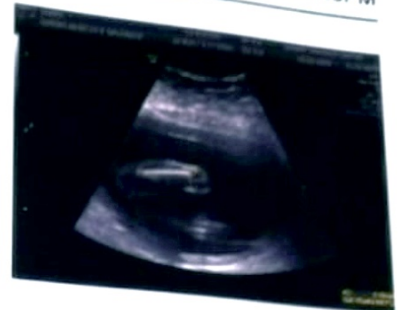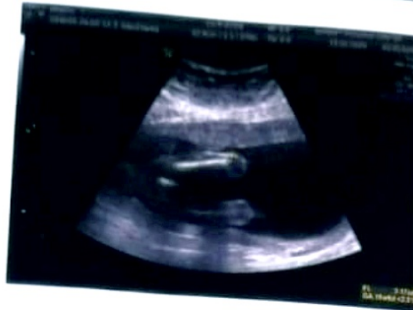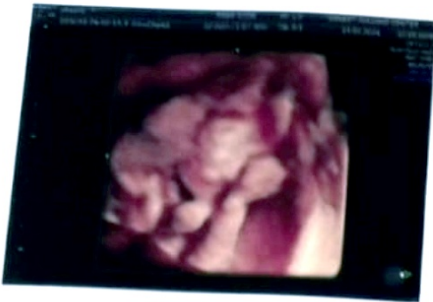VID : 9104 0344 2903 9745

मेरा आधार, मेरी पहचान

ID: D59283-24-02-13-3

sheela

Exam Date 13 02 2024 12 55 49PM



SANKET

IMAGING CENTER

(A Unit of Advitiya Imaging And Medical Systems Pvt. Ltd.)

<FACILITIES>

1.5 TESLA DIGITAL MRI
HIGH SPEED MDCT

ANGIOGRAPHY
ULTRASONOGRAPHY

COLOR DOPPLER
DIGITAL X-RAY

P.T. NAME	MRS. SHEELA KUMARI	AGE	28 Y/FEMALE
REF. DOCTOR	DR. BINDU JOSEPH	DATE	13/02/2024

OBSTETRIC ULTRASOUND-TARGET SCAN

LMP: 01/10/2023

GA BY LMP: 19weeks and 2days

A single live intrauterine foetus with cephalic presentation at the time of scan.

Foetal Parameter:

	Cms	Corresponding to	Weeks	Days
BPD	4.5	Corresponding to	19	4
HC	16.6	Corresponding to	19	2
AC	14.6	Corresponding to	20	0
FL	3.1	Corresponding to	19	6
Tibia	2.6	Corresponding to	19	3
Fibula	2.7	Corresponding to	19	4
Humerus	2.9	Corresponding to	19	5
Radius	2.5	Corresponding to	19	3
Ulna	2.7	Corresponding to	20	1
Gestational age as per USG			19	5
Effective fetal weight by USG	319 gram \pm 15 gram			
EDD as per USG	04/07/2024			

Foetal cardiac activity: is regular. Foetal heart rate is 137 beats/min.

Foetal body and limb movements are observed.

Placenta: is on anterior uterine wall well away from internal OS shows grade- I maturation. Well away from internal os.

Liquor: is adequate in amount for the gestational age. AFI 12 cm

Internal os: Closed. Cervical length 3.5 cm

Umbilical cord: 3 vessels cord is seen. Placental insertion is central. No cord around the neck is seen.

SANKET IMAGING CENTER

(A Unit of Advitiya Imaging And Medical Systems Pvt. Ltd.)

1.5 TESLA DIGITAL MRI
HIGH SPEED MDCT

<FACILITIES>

ANGIOGRAPHY
ULTRASONOGRAPHY

COLOR DOPPLER
DIGITAL X-RAY

Head: Appears normal in size and shape. Both lateral ventricles appear normal in size. Midline echoes appear normal. Cisterna Magna. No SOL is seen.

Spine: Full length of the vertebral column is visualized and appears normal. No evidence of spina bifida seen.

Neck: No cystic lesion is visible around the fetal neck. Nuchal thickness is normal.

Face: Fetal face was visualized in profile and coronal scans. Intraorbital distance is normal. Eyeballs, nose and lips appear normal. Nasal bone was well visualized.

Thorax: Normal cardiac situs & position. Four chambers view and out flow tract view appear normal. Both lungs were visualized. No evidence of pleural or pericardial effusion. No SOL seen in thorax.

Abdomen: Abdominal circumference is normal. Anterior abdominal wall appears normal. Liver & GB appear normal. Fetal stomach and bowel loops appear normal. No evidence of ascites seen.

KUB: Both kidneys appear normal in size. No evidence of pelvicalyceal dilatation. Urinary bladder appears normal in size.

Limbs: All the four limbs are seen. The long bones appear normal for the period of gestation. Both the hands and feet appeared normal.

Impression: Intrauterine single live fetus of 19 weeks and 5days duration with cephalic presentation. No gross foetal anomaly seen.

I, *Dr. sumit kumar verma* declare that while conducting USG on *Mrs. sheela*, I have neither declared nor disclosed the sex of her fetus to anybody in any manner

DR SUMIT KUMAR VERMA, MBBS, MD

Consultant Radiologist.

REG. NO. MP-6510

Add : Narayan Nagar, ITI Road, Warehouse Ke Samne, Ward No. 17, Narmadapuram - 461001 Ph. : 07574796266