DESHMUKH
RADIOLOGY
LABORATORY

Dr. UMESH DESHMUKH
M.D., D.M.R.D.
Dr. ROHAN DESHMUKH
M.B.B.S., D.M.R.E.

Dr. SUNIL DESHMUKH
M.D.

X-RAY AND ADVANCED ULTRASOUND CLINIC

Name: - MRS. RUBINA ASLAMUDDIN KHAN

22 Feb 2024

Ref By: - DR. MRS. SHEETAL POTODE MD (OBGY)

NUCHAL TRANSLUCENCY SCAN (NT)

LMP – 20 Nov 2023, MA- 13 Wks 3 Days EDD- 26 Aug 2024

Real time ultrasound done with 3 to 5 MHz. convex probe reveals

A single well-defined gestational sac with single fetus.

CRL – 7.18 cm = 13 Wks 3 Days. **USG EDD – 26 Aug 2024**

Normal fetal cardiac activity appreciated. FHR – 152 bpm. No tricuspid regurgitation seen.

Normal Nasal bone (2.7 mm) & Nuchal translucency seen. NT measures 1.66 mm.

Ductus venosus shows normal waveform.

Both upper and lower limbs are well visualized with normal ossification of cranial bones.

Choroid plexuses filling the lateral ventricles are seen with intact inter-hemispheric fissure and normal appearing stomach bubble.

Normal 'parallel' inflow and 'V shaped' outflow from fetal heart could be demonstrated.

Mean Uterine artery PI is 1.52 (at 46th percentile) - normal.

Amount of liquor is adequate.

Placenta is forming anteriorly.

The cervical canal is normal in length (3.19 cms). Internal os is closed.

IMPRESSION: - **Single live intrauterine pregnancy of 13 Wks 3 Days.**
No significant abnormality detected.

I, Dr. Rohan Umesh Deshmukh declare that while conducting USG of above patient, I have neither detected nor disclosed sex of her fetus to anybody by any manner.

Dr. Rohan U. Deshmukh
Consultant Radiologist
FMR ID: 213064

IRWIN CHOWK, AMRAVATI. Ph. 0721 - 2663131, 2663785

DESHMUKH RADIOLOGY LABORATORY

22 Feb 2024

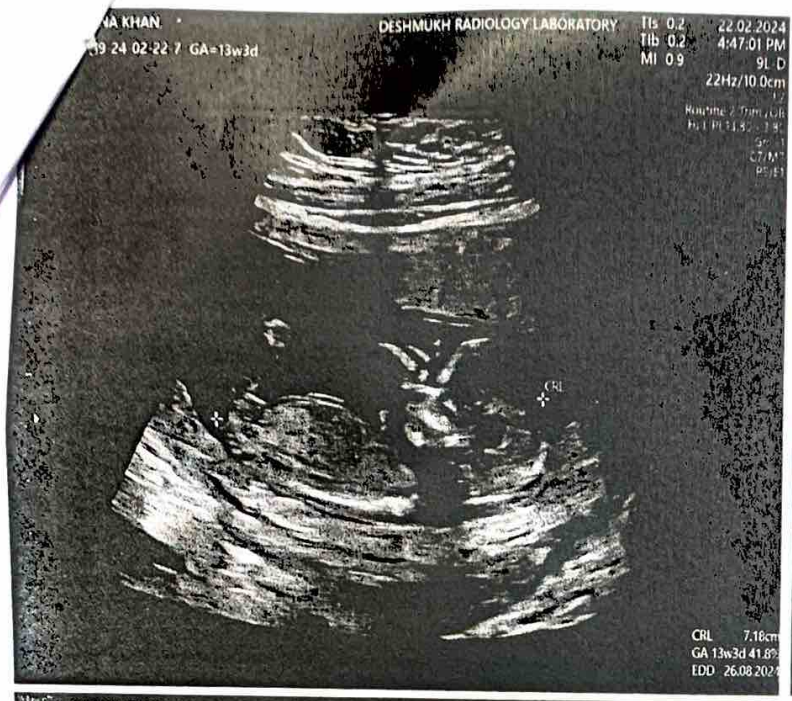

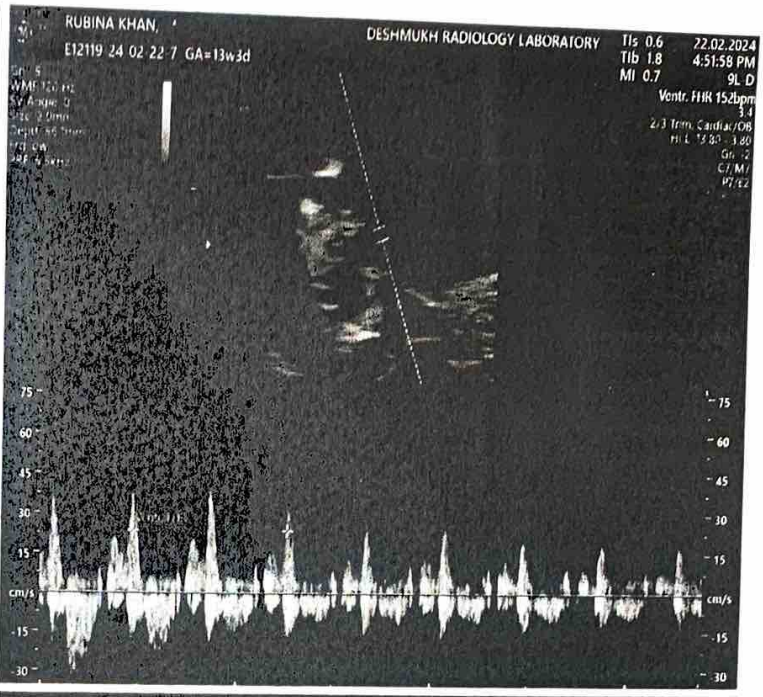

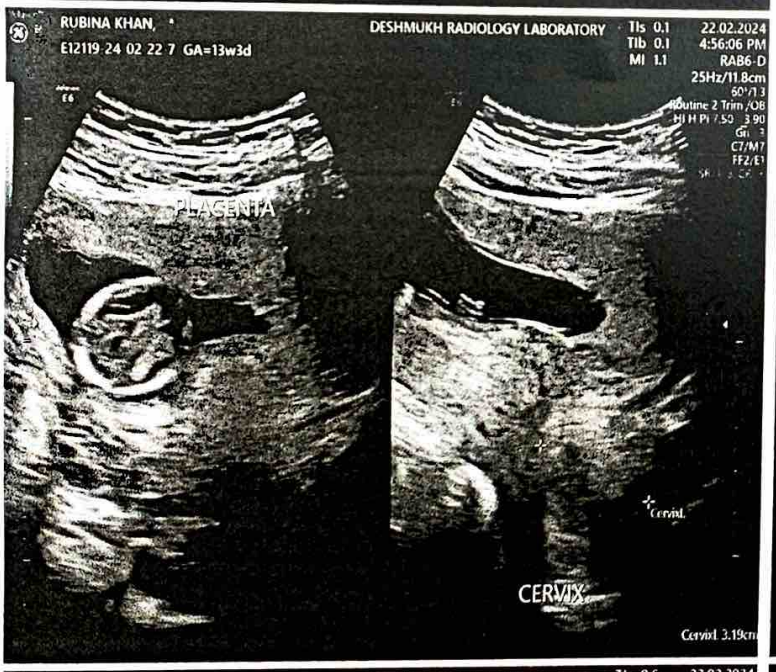

DESHMUKH RADIOLOGY LABORATORY

Date of Exam: 27.02.2024 Page 1 / 11
Exam Type:

Patient: RUBINA KHAN Sex: Female
Patient ID: E12119-24-02-22-7

LMP	20.11.2023	GA(LMP)	13w3d	EDD(LMP)	26.08.2024	G	Ab
DOC		GA(AUA)	13w3d	EDD(AUA)	26.08.2024	P	Ec

EFW (Hadlock)	Value	Range	Age	Range	GP	Williams
AC/BPD/FL/HC						N/A

2D Measurements	AUA EFW	Value	m1	m2	m3	Meth.	GP	Age
CRL (Hadlock)	✓	7.18 cm	7.18			avg.	41.8%	13w3d
NT		1.61 mm	1.61			avg.		
NBL (Sonek)		2.68 mm	2.68			avg.	12.2%	

2D Measurements	Value	m1	m2	m3	m4	m5	m6	Meth.
Uterus								
Cervix Length	3.19 cm	3.19						avg.

Doppler Measurements	Value	m1	m2	m3	m4	m5	m6	Meth.
Ductus Venosus								
S	36.28 cm/s	-36.28						max
TAmax	-24.88 cm/s	-24.88						max
a	-6.75 cm/s	-6.75						max
D	-26.45 cm/s	-26.45						max

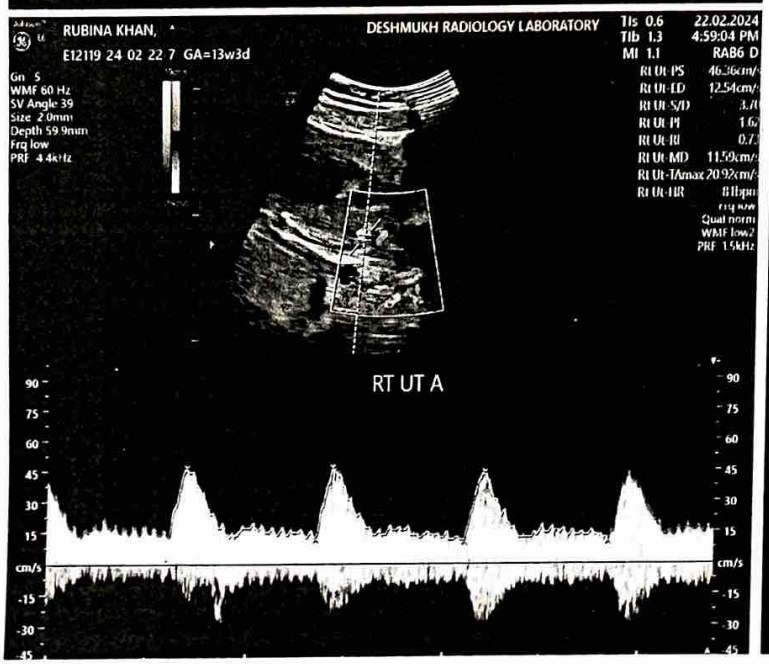

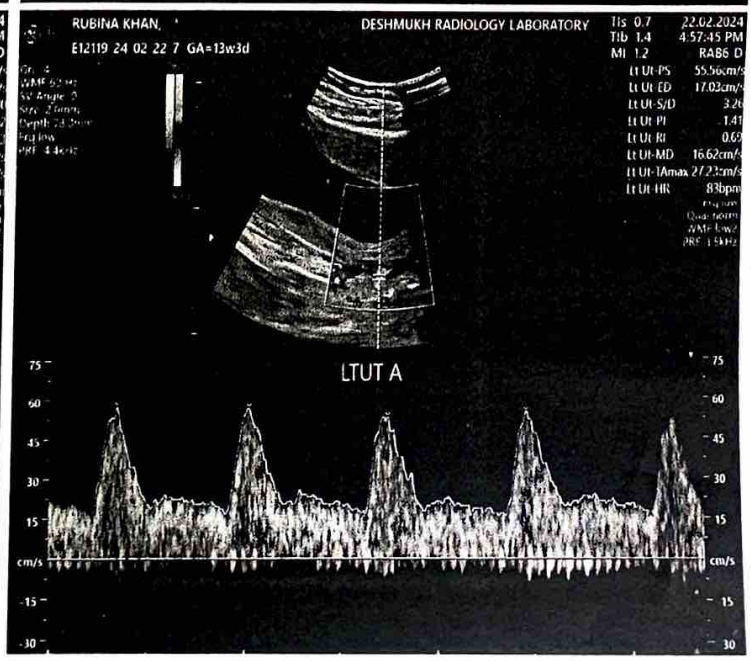

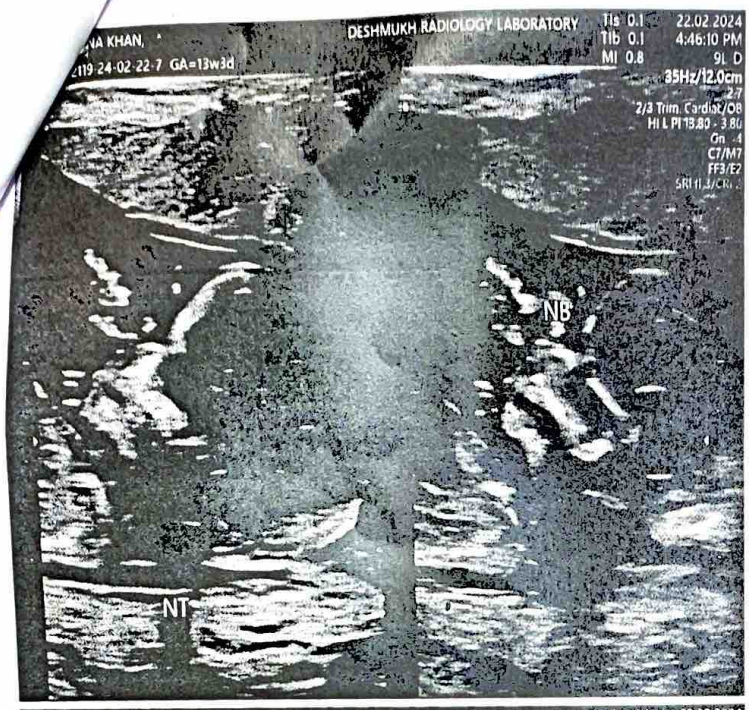
DESHMUKH RADIOLOGY LABORATORY
22.02.2024
4:46:10 PM
NB
NT

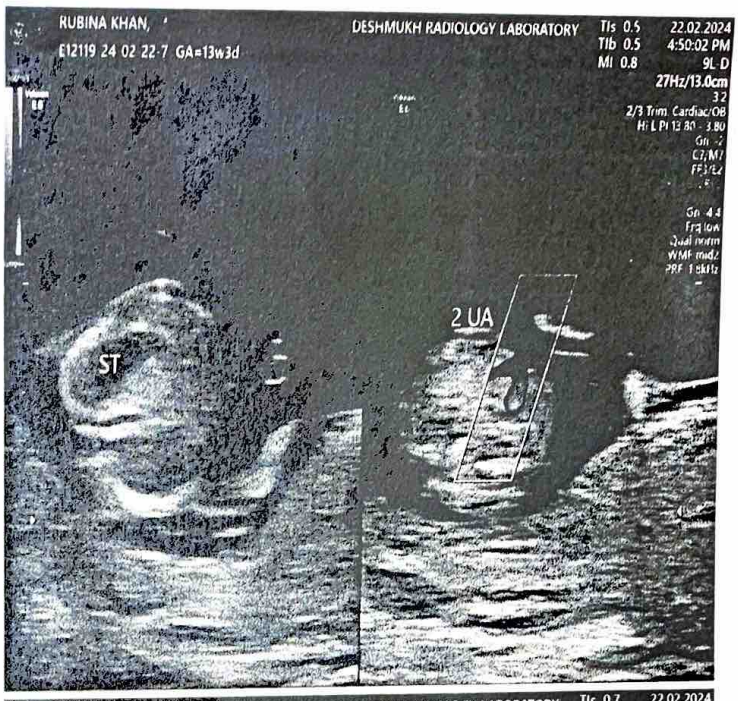
RUBINA KHAN,
E12119 24 02 22 7 GA=13w3d
DESHMUKH RADIOLOGY LABORATORY
22.02.2024
4:50:02 PM
ST
2 UA

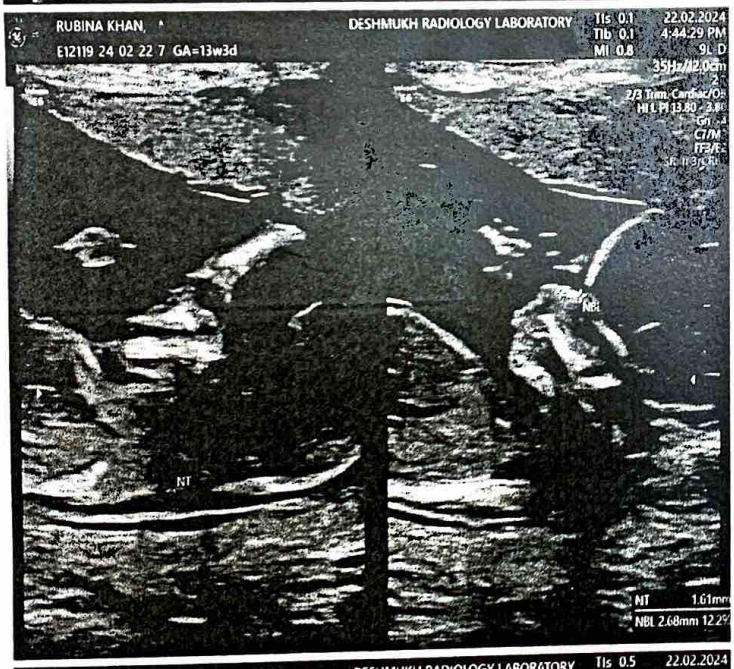
RUBINA KHAN,
E12119 24 02 22 7 GA=13w3d
DESHMUKH RADIOLOGY LABORATORY
22.02.2024
4:44:29 PM
NT
NT 1.61mm
NBL 2.68mm

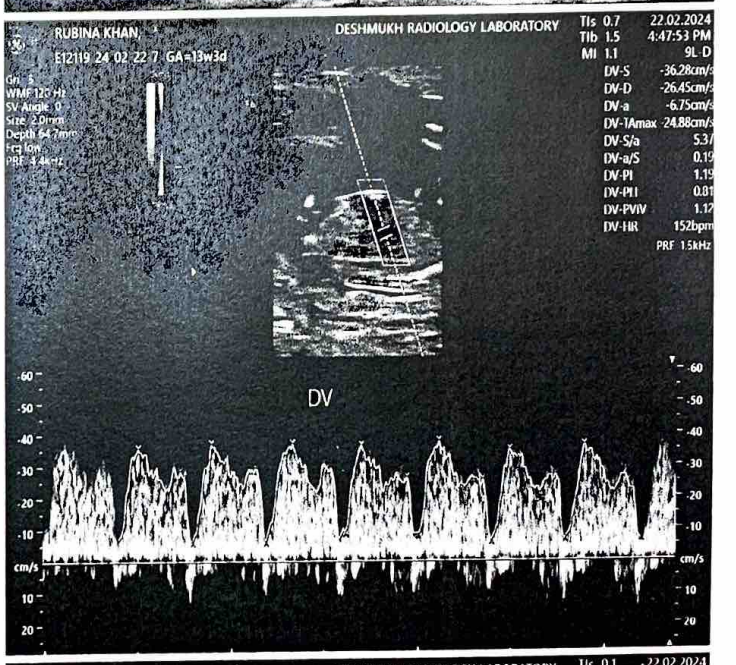
RUBINA KHAN,
E12119 24 02 22 7 GA=13w3d
DESHMUKH RADIOLOGY LABORATORY
22.02.2024
4:47:53 PM
DV

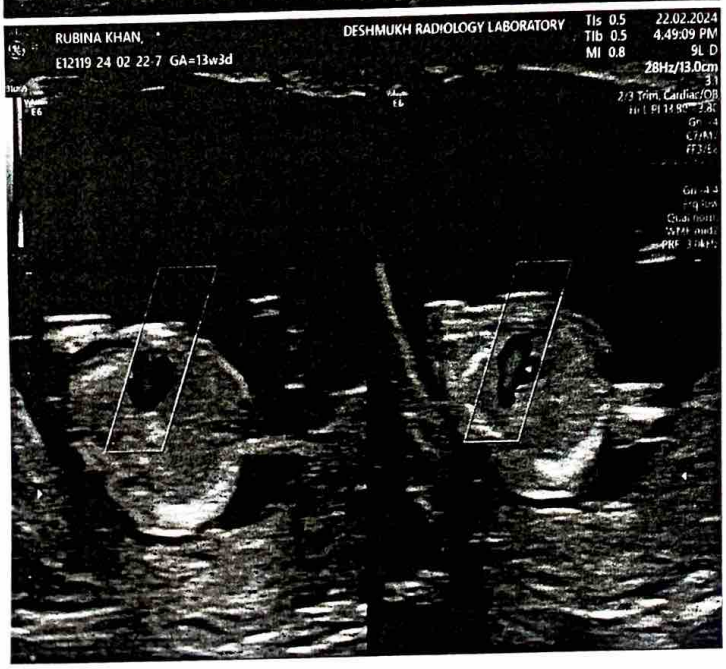
RUBINA KHAN,
E12119 24 02 22 7 GA=13w3d
DESHMUKH RADIOLOGY LABORATORY
22.02.2024
4:49:09 PM

RUBINA KHAN,
E12119 24 02 22 7 GA=13w3d
DESHMUKH RADIOLOGY LABORATORY
22.02.2024
4:51:00 PM
PMT
CRANIUM
4LIMBS

Risk for preeclampsia

Report date	22-02-2024
Examination date	22-02-2024
Gestational age	13^{+2} weeks

Maternal characteristics

Age in years	31.5
Height in cm	157
Weight in kg	54.8
Racial origin	South Asian
Smoking during pregnancy	No
Family history of preeclampsia	No
Method of conception	Spontaneous
Singleton or twins	Singleton

Medical history

Chronic hypertension	No
Diabetes type I	No
Diabetes type II	No
Systemic lupus erytheromatosus	No
Anti-phospholipid syndrome	No

Obstetric history

Parity	Parous
Preeclampsia	No
Date of delivery	04-02-2022
Gestational age at delivery	38^{+2} weeks
Inter-pregnancy interval	1.8 year

Biophysical measurements

Mean arterial pressure	77 mmHg (0.941 MoM)
Uterine artery PI	1.5 (0.956 MoM)
Measurement date	22-02-2024

Preeclampsia risk from history only

< 37 weeks: 1 in 500

Preeclampsia risk from history plus MAP, UTPI

< 37 weeks: 1 in 1667 (low risk)

Recommendation

The risk of preeclampsia was assessed by a combination of maternal characteristics and medical history with measurements of blood pressure and blood flow to the uterus.

On the basis of this assessment the patient has been classified as being at low risk for developing PE before 37 weeks. Nevertheless, it is recommended that the risk is reassessed at 20 and 36 weeks.