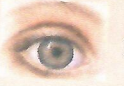



॥ श्रीकृष्ण ॥
॥ ॐ नमो भगवते वासुदेवाय ॥
॥ श्री श्रीराधागोपीनाथ रोगचिकित्सा मंदिर ॥

डोळ्यांच्या मोतीबिंदू इ. ची शस्त्रक्रिया
सोय
उपलब्ध



बोरकर मल्टिस्पेशालिटी हॉस्पिटल

डॉ. अतुल अनिल बोरकर

M.B.B.S. (जनरल ऑफ्टिशियनर)

D.O.M.S. (नेत्ररोग तज्ञ)

C.P.O.S. (तिरळेपनावत बाळनेत्र रोग तज्ञ)

● Ex. Ophthalmic Surgeon

Civil Hospital. Wardha

● Ex. Register

Mahatme Eye Bank & Eye Hospital, Nagpur

● Ex. Fellow in Paediatric Ophthalmology & Strabismology

Anuradha Eye Hospital, Sangli (M.S.)

Regd. No. 2001020975



रजि.नं. 943 (N.M.C.)

डॉ. गायत्री अतुल बोरकर

M.B.B.S., D.G.O. (स्त्री व प्रसूती रोग तज्ञ)

Ex. Consulting Gynaecologist

Daga Hospital, Nagpur

Matruseva Sangh, Mahal, Nagpur

Ex. Gynaecologist

Civil Hospital, Bhandara

Reg. No. 2001020810

बोरकर हॉस्पिटल, 31 शिवांगी ले-आऊट, इंगोले चौक, मुडेच्या शाळेजवळ, हुडकेश्वर रोड, नागपूर, मो. 09923817745

उपलब्ध सुविधा

स्त्री रोग:-

- नॉर्मल डिलीव्हरी
- सिझेरियन शस्त्रक्रिया
- गर्भाशयाची शस्त्रक्रिया

नेत्र रोग:-

- बिनटाक्याची, बिना सुंथणीची मोतीबिंदू शस्त्रक्रिया (Phaco)
- व कृत्रिम लेन्स प्रत्यारोपण
- काचबिंदू उपचार व शस्त्रक्रिया
- तिरळेपणा शस्त्रक्रिया

इतर :-

- जनरल सर्जरी
- अस्थिरोग उपचार व शस्त्रक्रिया
- उच्चरक्तदाब
- मधुमेह
- हृदयरोग
- दमा
- टि.बी. उपचार
- एक्स-रे
- रक्त तपासणी
- लसीकरण
- सोनोग्राफी

॥ श्रीहरिः शरणम् ॥

दिनांक :

Minkalwar
30/F Nagpur 10/2/24
(1 मिनारी नागपूर)

Wt - 69.70 Kg

height - 147 cm

Dt of Birth - 23/08/1994

L.M.P - 6/10/23

G.P.L.M

IS - FLSH & 8yr 1/2

Normal Conception

NO NO DM/HT/BA in Pw

Adv

Totally molar

Manewada Cement Road, Nagpur-27. Ph. : 0712-2755407, 9894302044

DR. SNEHAL VAIDYA JIBHAKATE
MBBS, MD, Radio Diagnosis
Consultant Radiologist
E: dr.snehal.vaidya@gmail.com
Regd. No. : 2010/04/1044

DR. SACHIN JIBHAKATE
MBBS, MD, Medicine (Mumbai), IDCCM (Mumbai)
Physician, Cardiologist & Diabetologist, Intensivist
E : sachin230580@hotmail.com
M : +91 9834362044
Regd. No. : 2004/02/687

NAME: MRS. MINAKSHI NAGPURE
REF BY: DR. G. BORKAR

DATED: 13 January 2024
AGE/SEX: 29Y/F

OBSTETRIC SONOGRAPHY REPORT

LMP: 06/10/2023

GEST AGE: 14WKS 1DAYS

EDD: 12/07/2024

- Uterine cavity shows Single live intrauterine gestation.
- The CRL measures 6.71cm and corresponds to the gestational age of 13wks 0days.
- **Fetal cardiac activity** is appreciated (162bpm). Yolk sac is seen.
- Normal blood flow in ductus venosus and tricuspid valve seen.
- **Nasal bone** is visualized. **Nuchal translucency** is normal in size (0.15cm).
- Intracranial translucency appears normal.
- Calvarium is seen in present scan.
- Placenta is developing globally. No retro chorionic hematoma/collection.
- **Cervix** measures 2.9cm and is normal in length.
- On Doppler study, **mean PI of uterine artery** is 1 and is normal for gestation.

To rule out foetal anomalies, scan at 18-22 wks is advisable.

OPINION:


SINGLE LIVE INTRAUTERINE FOETUS WITH SONIC MATURITY OF 13 -14 WKS.
SONIC EDD - 20/07/2024

CRL	NT	PERCENTILE
6.71	0.15	16

(Ref - FMF calculator)

All measurements including estimated foetal weight, are subject to statistical variations.
Not all anomalies can be detected on sonography. Much of them depends on fetal position at the time of sonography.
I have neither detected nor disclosed sex of fetus to anybody in any manner.

Thanks for referral!!!


DR. SNEHAL VAIDYA JIBHAKATE
MBBS, MD, BCFRG
(2010/04/1044)

FACILITIES:

Whole Body Multistatic CT Scan, Whole Body Digital X-Ray, All Procedures, Digital Mammography, 3D-4D Ultra Sonography, Color Doppler, 2D ECHO/TMT/ECG/PFT/EMG, Pathology, 2nd Opinion

**Mahanagar Diagnostic & Research Centre, SURAJ BHAVAN, 5 Welekar Layout Near Tukdoji Square,
Manewada Cement Road, Nagpur-27. Ph. : 0712-2753467, 9834362044**