



# SAMYAK ULTRASONOGRAPHY CLINIC

Shop No. 5, 3-B, Ground Floor, Govind Garden, Near Kerala Stores, Raisen Road, Bhopal  
PHONE +918889759269, +917389183820, 0755-4256444

PATIENT'S Name- MRS.APARNA PATHAK	Age- 31/F
Referred By-DR.RAJNI SUKHEJA(D.G.O)	Date-16/03/2024

## LEVEL II FETAL SCAN

The real time, B mode, gray scale sonography of the gravid uterus was performed.  
There is a single, live, intruterine gestation.

### MATERNAL :

Cervix measured 3cms in lenght .  
Internal os is closed  
No fluid is seen in the cervical canal.

### BIOMETRY :

L.M.P. :01/11/2023  
Gestational Age : 19 wks 3 days  
E.D.D. :07/08/2024

	FOETUS 1	
	Meas. in mms	Age Wks/Dys
BPD	44 mm	19 wks 2 days
HC	167 mm	19 wks 3 days
AC	129 mm	18 wks 4 days
FL	31 mm	19 wks 6 days
HUMERUS	29 mm	19 wks 4 days
FIBULA	Normal	
TIBIA	Normal	
RADIUS	Normal	
ULNA	Normal	
EFW	277 gms	
AVG AGE	19Wks 3 days	
FHR	138b/m	

### SURVEY

Presentation- Cephalic

Placenta -Posterior grade-2

Liquor -Adequate

Umbilical Cord - 3 vessel Cord seen.

Fetal Activity present

Cardiac activity present

THIS REPORT IS AN OPINION NOT THE FINAL DIAGNOSIS IT SHOULD BE CORRELATED CLINICALLY WITH HISTORY AND EXAMINATION OF THE PATIENT. IN CASE OF ANY DISCREPANCY A REVIEW CAN BE ASKED. NOT VALID FOR MEDICOLEGAL PURPOSES.

## ANEUPLOIDY MARKERS

Nasal Bone seen.

Nuchal Fold :4.2mm

## FOETAL ANATOMY :

### **HEAD**

Midline falx seen.

Both lateral ventricles appeared normal.

Posterior fossa appeared normal.

Both lateral ventricles is measures 5.2mm

Cisterna magna is measures 5mm.

The cerebellum is normal

Corpus Callosum is seen.

### NECK

Fetal neck appeared normal

### SPINE

Entire spine is visualised in longitudinal and transverse axis.  
The vertebrae and spinal canal appear normal.

### FACE :

Foetal face seen in coronal and profile views.  
Both orbits, nose and mouth appear normal.

### THORAX :

The heart appears in mid position.  
Normal cardiac situs.  
The four chamber view is normal.  
The out flow tract appeared normal.  
Both lungs seen.  
No evidence of pleural or percardial effusion.  
No evidence of SOL in the thorax.

### ABDOMEN :

Abdominal situs appeared normal.  
Stomach, both kidneys and bladder are normal.  
The portal vein is normal.  
No evidence of ascites. No abdominal wall defect.

### EXTREMITIES :

All fetal long bones visualized and appear normal for the period of gestation



# SAMYAK ULTRASONOGRAPHY CLINIC

Shop No. 5, 3-B, Ground Floor, Govind Garden, Near Kerala Stores, Raisen Road, Bhopal  
PHONE +918889759269, +917389183820, 0755-4256444

## FOETAL DOPPLER

**BILATERAL MATERNAL UTERINE ARTERIES PI IS NORMAL**

Right Ut Art PI- 0.33 , Left Ut Art PI-0.88

Average Uterine PI -0.60

## IMPRESSION :

- THERE IS SINGLE, LIVE, INTRAUTERINE GESTATION OF 19 WKS 3 DAYS
- NO FOETAL ANOMALIES ARE SEEN.
- U/S E.D.D-07/08/2024
- This report does not include 2D fetal echo (Foetal echo cardiography is advised for detailed fetal cardiac evaluation)

  
**DR ROOPVARSHA JAIN**  
CONSULTANT RADIOLOGIST  
REG.NO.10148

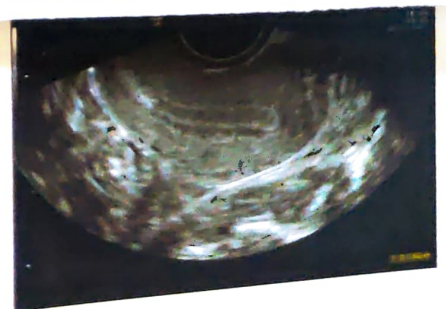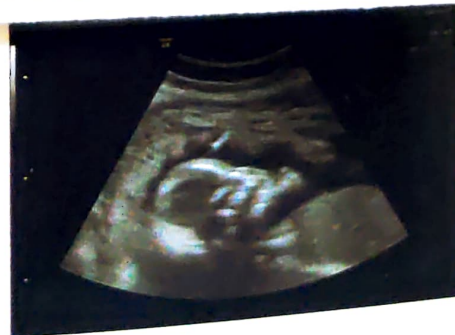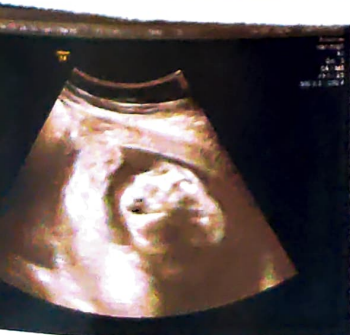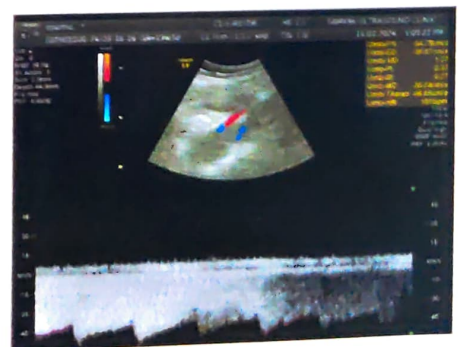
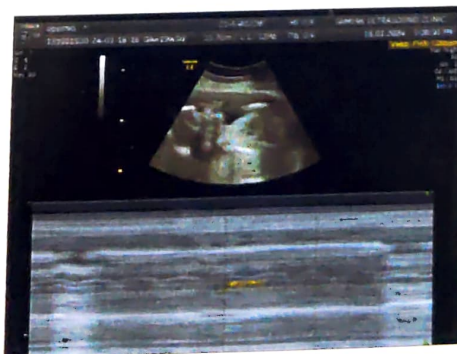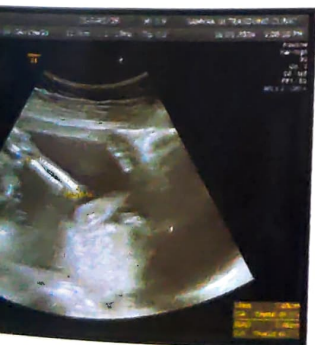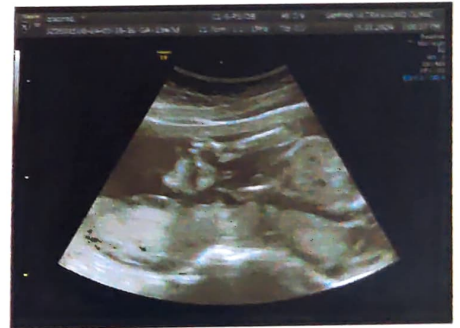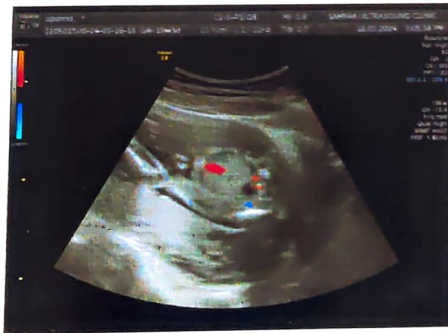
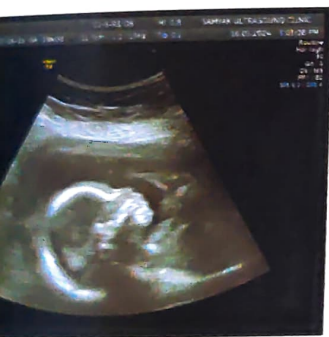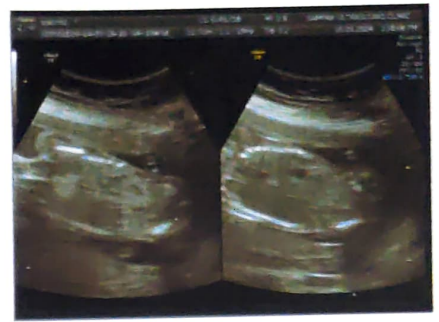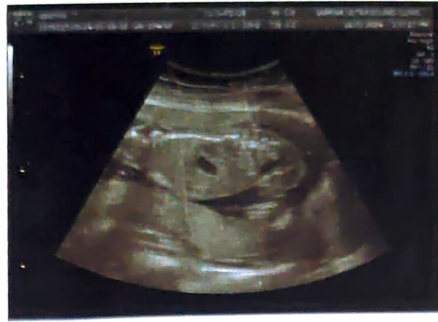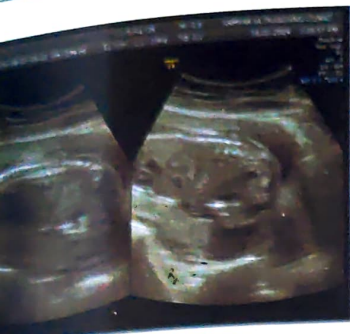*While conducting ultrasonography on mrs, APARNA PATHAK have neither detected nor disclosed that sex of her fetus to anybody in any manner.*

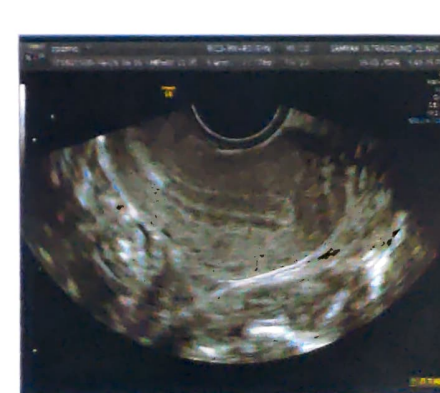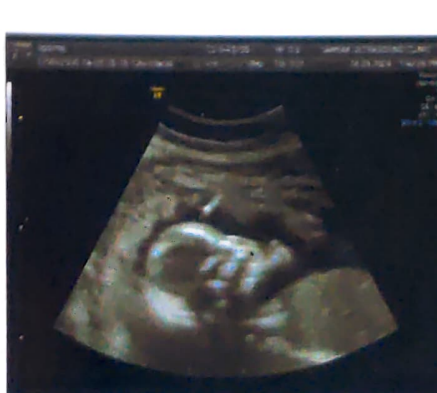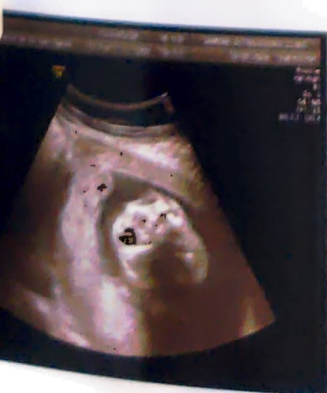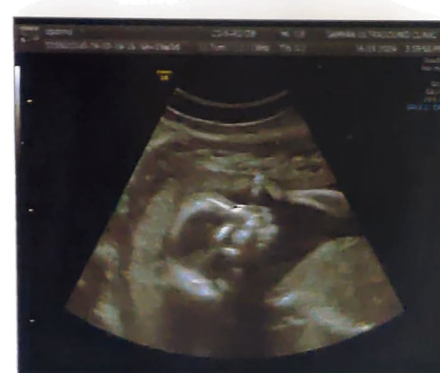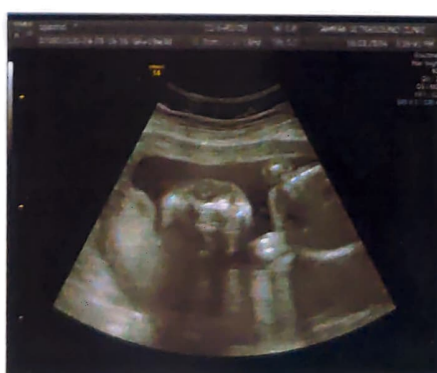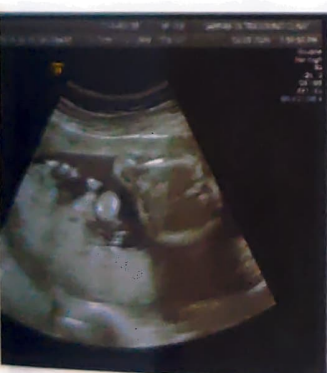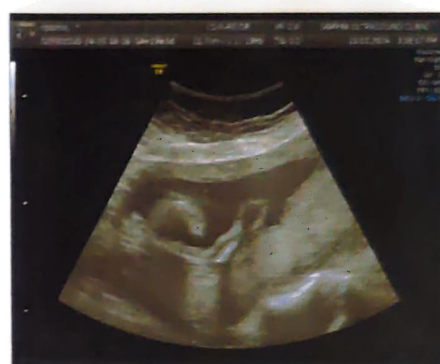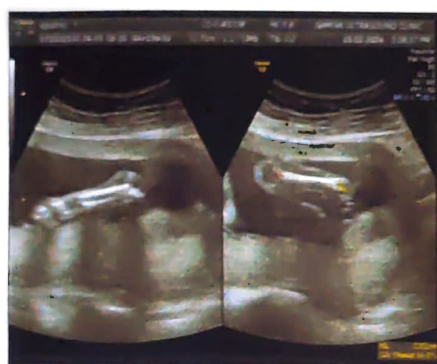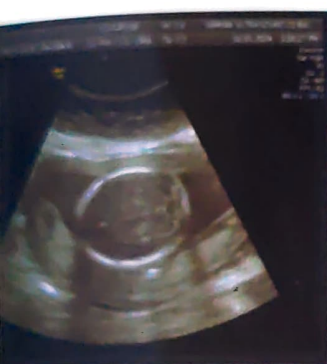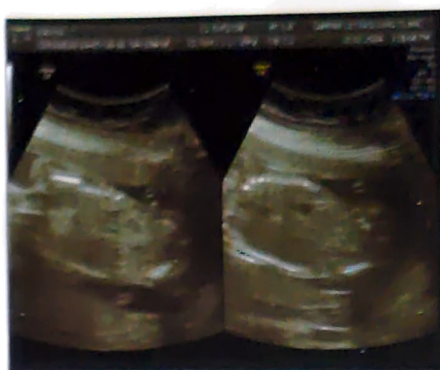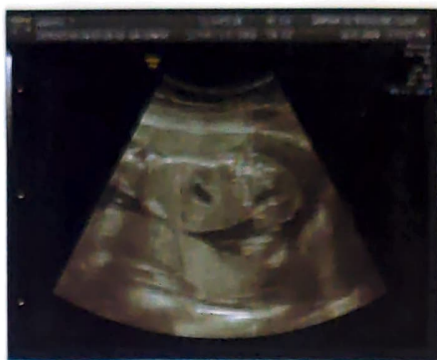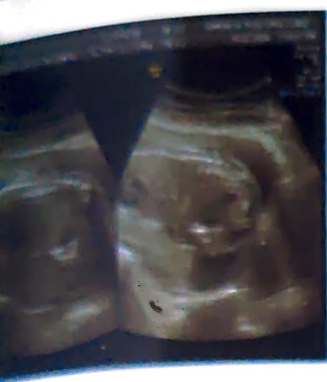  
**DR ROOPVARSHA JAIN**  
CONSULTANT RADIOLOGIST REG.NO.10148

## **Please note the limitations of Obstetric Ultrasound Scanning**

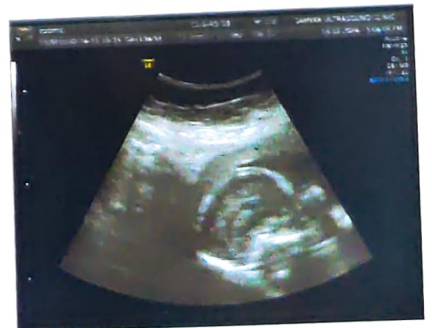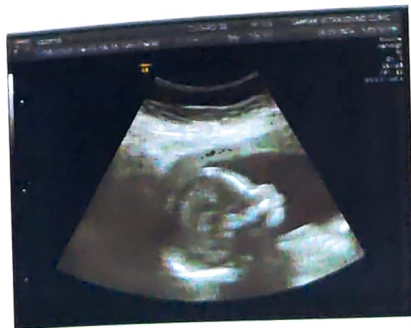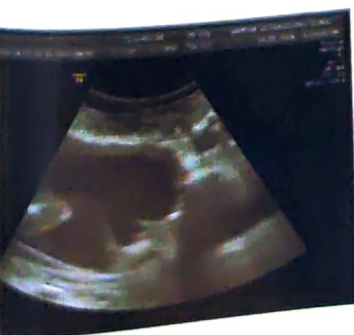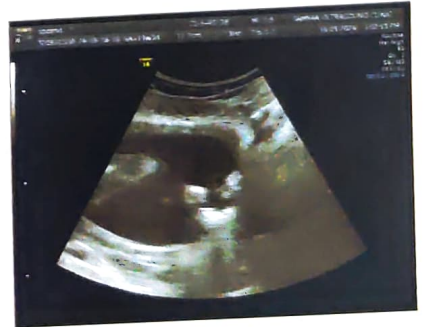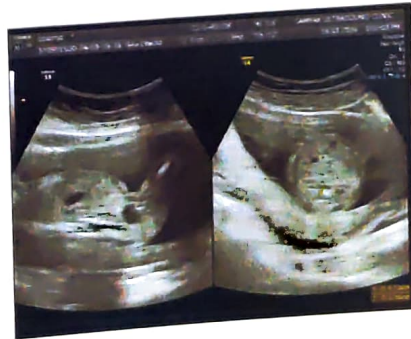
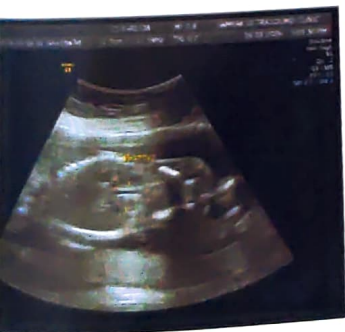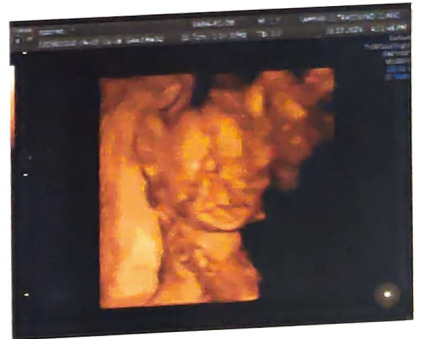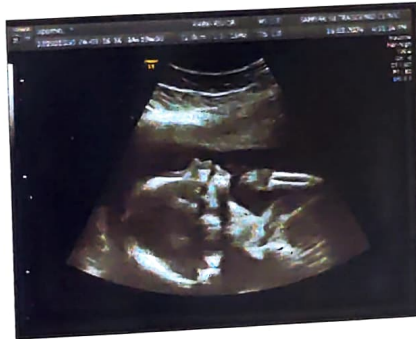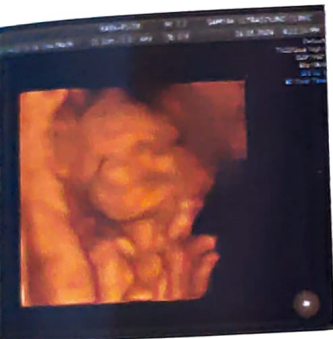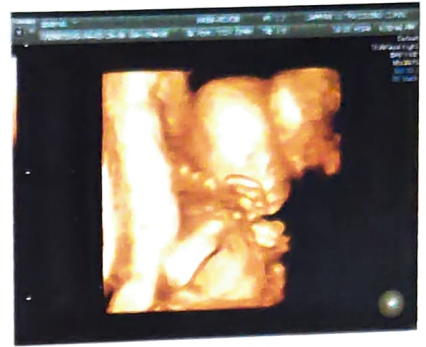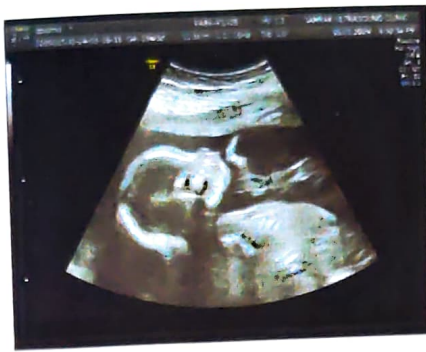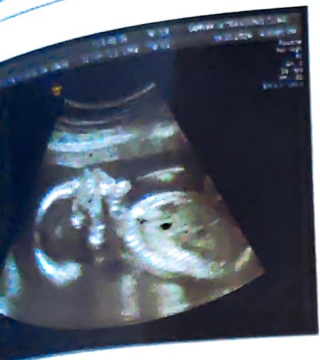- Scanning of the foetal anatomy can be affected by various factors like maternal abdominal wall thickness & tissue echogenicity, scars, fetal lie, amniotic fluid volume, fetal gestation and other factors.
- Therefore all the anomalies may not be necessarily be detected.
- A "Normal" scan of the fetus does not mean that the fetus will be normal at birth as the fetus is developing all the time.
- This report does not include 2D foetal echo.













# ROSHAN HOSPITAL

(Since - 1998)

Regd. No. : NH/5407/July-2017



7-A-B, GOVIND GARDEN, RAISEN ROAD, BHOPAL (M - 9522118688)

☐ DOUBLE / ☐ TRIPPLE / ☒ QUADRIPLER MARKER TESTS

PATIENT UHID NO.	:	RMH-23005830	
NAME OF PATIENT	:	Aparna. Pathak	
AGE OF PATIENT	:	31 yrs - F	
WEIGHT (PATIENT)	:	60.5 kg	Height.....Inch/cm
DATE OF BIRTH (PATIENT)	:	20/11/1992	
DATE OF MARRIAGE (PATIENT)	:	30/01/2023	
HUSBAND NAME	:	Dheeraj Pathak	Age : 38 y M
FULL ADDRESS & MOBILE NUMBER	:	H.No 3-2 MP-Nagar Zone-2 Bhopal (1) Mo : 9369063006 (2) Mo : .....	
LMP	:	11/11/23	
EDD	:	8/8/24	
FAMILY HISTORY	:	Mother - CA	
OBSTETRIC HISTORY	:	Prim	
NUMBER OF LIVE CHILDREN	:	Male : ..... Female : ..... Abortions : .....	
IF ANY	:	None	
PERSONAL HISTORY	:	None	

## date Checked & Verified by

Name : .....

Relation : .....

Signature : .....

Date : .....

Name of Referring Doctor

Dr. (Mrs) Rajni Sukheja

(M.B.B.S., Dip. G.O.)

Reg. No. MP-9068

Mobile : 9522118688