



DAFFODILS

iv Fertility, Foetal Care and Day-Care Institute of Laparo-Scopy

tender loving care....

DR. JAGRUTI B. MURKEY

DNB (Obs & Gyn), DGO, FCPS, DFP, MBBS (Mumbai)

2 yrs Fellowship in Fetal Medicine (Mediscan Chennai)

Ex. Consultant in Mediscan (Chennai)

Certified for NT Scan by FMF, London, UK

Mrs. ANJUM PARVEEN SHADAB NAIM / D21761 / 21/03/2024 / Visit No 1

Fetal Anatomy

Head: normal, Neck: normal, Spine: normal, Face: normal, Thorax: normal, Heart: normal, Abdomen: normal, KUB: normal, Extremities: normal

Head :Both lateral ventricles seen. Intracranial translucency appeared normal.

Face :Orbits and Premaxillary triangle seen

Heart :Heart - Two inflows and outflows imaged in colour.

Impression

INTRAUTERINE GESTATION CORRESPONDING TO A GESTATIONAL AGE OF 13 WEEKS 4 DAYS

GESTATIONAL AGE ASSIGNED AS PER LMP

PLACENTA - ANTERIOR

LIQUOR - NORMAL

MATERNAL -RIGHT UTERINE ARTERY DOPPLER SHOWS HIGH RESISTANCE TO FLOW

- (PI >95 %tile) S/O INCREASED RISK OF FETAL GROWTH RESTRICTION AND / OR PRETERM PRE ECLAMPSIA.

SUGGESTED

1. COMBINED FIRST TRIMESTER SCREENING FOR DOWNS SYNDROME.(Blood test cut off CRL 84mm)

2. KINDLY CONSIDER STARTING LOW DOSE ASPIRIN IN VIEW OF INCREASED UTERINE ARTERY PI.
(150 mg as per new ASPRE trial)

3. DETAILED ANOMALY SCAN AT 20 WEEKS.

(Please bring referral letter.)

Note - Nuchal translucency NT was measured as per FMF (Fetal Medicine Foundation U.K.) Guidelines.

DECLARATION - I declare that while conducting ultrasonography / image scanning, I have neither detected nor disclosed the sex of the fetus to anybody in any manner. All congenital anomalies and genetic conditions may not be detected on ultrasonography due to limitations like fetal position, amount of liquor, previous scars, Small VSDs, late appearance of few anomalies and structures that are not part of routine imaging protocol. Detailed fetal echo not included in this scan.

DR JAGRUTI MURKEY DNB DGO MBBS
CONSULTANT FETAL MEDICINE SPECIALIST

DR. JAGRUTI BHUSHAN MURKEY
DNB (OBS & GYN), DGO, MBBS
FETAL MEDICINE SPECIALIST
REG. NO. 2007 / 06 / 2480
DAFFODILS, Mudholkar Peth, Amravati (M.S.)



DAFFODILS

Daryav Fertility, Foetal Care and Day-Care Institute of Laparo-Scopy

DR. JAGRUTI B. MURKEY

DNB (Obs & Gyn), DGO, FCPS, DFP, MBBS (Mumbai)

2 yrs Fellowship in Fetal Medicine (Mediscan Chennai)

Ex. Consultant in Mediscan (Chennai)

Certified for NT Scan by FMF, London, UK

tender loving care....

Patient name	Mrs. ANJUM PARVEEN SHADAB NAIM	Age/Sex	25 Years / Female
Patient ID	D21761	Visit No	1
Referred by	Dr. KARUNA MURKEY	Visit Date	21/03/2024
LMP Date	17/12/2023 LMP EDD: 22/09/2024[13W 4D]		

OB - First Trimester Scan Report

Indication(s)

FIRST TRIMESTER NUCHAL TRANSLUCENCY AND ANOMALY SCAN

Real time B-mode ultrasonography of gravid uterus done.

Route: Transabdominal

Single intrauterine gestation

Maternal

Cervix measured 3.00 cms in length.

Right uterine PI : 2.6.

Left uterine PI : 1.2.

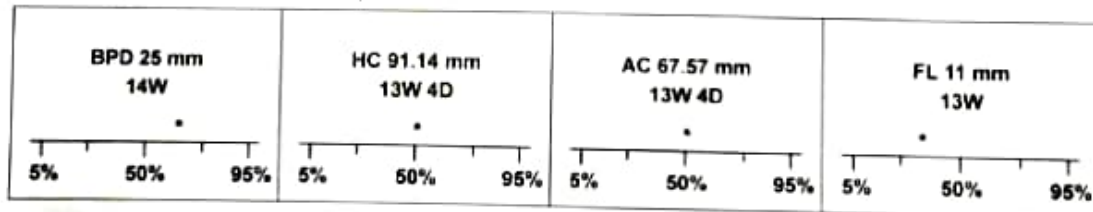
Mean PI : 1.90 (72%ile)

Fetus

Survey

Placenta : Anterior
Liquor : Normal
Umbilical cord : Two arteries and one vein
Fetal activity : Fetal activity present
Cardiac activity : Cardiac activity present
Fetal heart rate - 142 bpm

Biometry(Mediscan,Hadlock)



CRL - 78 mm(13W 5D)

Aneuploidy Markers

Nasal Bone : seen

Nuchal translucency : 1.7 mm Normal.

Ductus venosus : normal flow.

Tricuspid regurgitation : No evidence of tricuspid regurgitation.