

नागरेचा हॉस्पिटल

लक्ष्मीनारायण भंडिरामाणे, अनुजा हॉटेलजवळ, एकोरी वार्ड, चंद्रपूर M. 7741067314

डॉ. रूपेश के. सोनडवले

एम.बी.बी.एस., एम.एस. (सर्जन)
सेमिनोस्कोपी अँड जनरल सर्जन
रजि. नं. एमएससी २०१००४१०९३



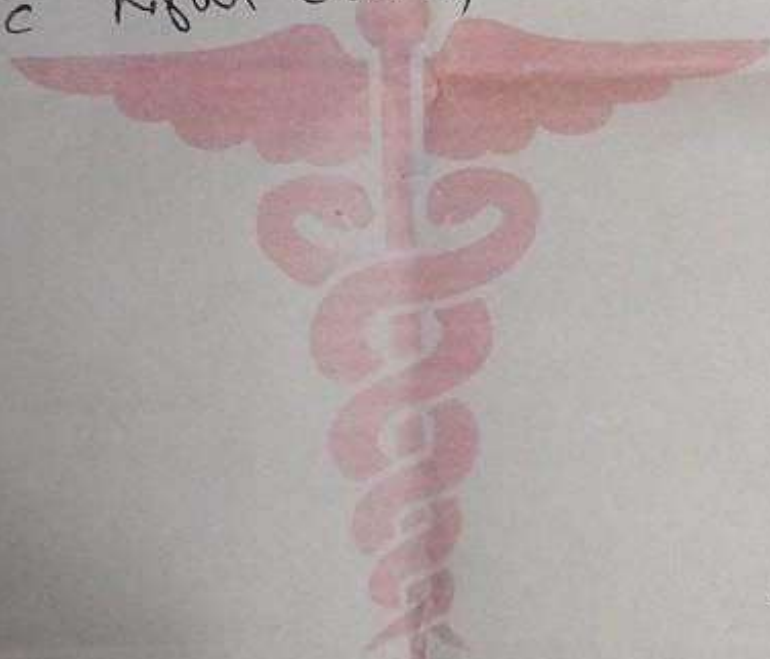
डॉ. रितेश के. सोनडवले

एम.बी.बी.एस., एम.एस.
प्रसूती व स्त्रियां तज्ञ
रजि. नं. २०१३/०६/२३५०

Jayashri Tendekar.

दिनांक: 12/4/2024

Histopathology of Uterus & Cervix
& Right ovary



12



SACHIN

Radio Diagnostic Center

Dr. Sachin A. Viswambhar
Consultant Radiologist
MBBS, DMF
Reg. No.: 20120510
TNMC & BYL'S Nair Hospital, Mumbai

Name: Mrs. Jayashri Tandra
Referred by : Self

Age/Sex: 38Yrs/Female
Date: 06/04/2024

USG PELVIS (TVS)

Uterus: Anteverted in position normal in size, shape and echotexture. Uterus measured 13.9 cms x 9.1 cms x 9.4 (630 cc) Bulky. Myometrium appear mildly heterogeneous.

A large intramural fibroid is noted measuring 8.5 cm x 7.6 cm x 8.7 cm (299 cc) involving right Postero-lateral myometrium. The fibroid is seen displacing and encroaching the endometrium.

Endometrium: Endometrial thickness measured 7.3 mm normal. No obvious evidence of any focal lesion within. Cu-T is noted in lower uterine segment.

Cervix: appear normal in size and echotexture. No focal lesion seen.


Ovaries: Left ovary measured 2.6 cm x 2.3 cm x 1.1 cm approximately 5.1 cc & Right ovary not visualised however right adnexa is clear. No evidence of focal lesion in both ovaries. Multiple small follicles are noted in both ovaries.

Adnexa: Bilateral adnexa are clear. No obvious lesion is noted.

Free Fluid: Minimal free fluid is noted in pouch of Douglas.

Impression:

- > A large Uterine Fibroid as described above.
- > Cu-T seen in lower uterine segment.


Dr SACHIN A. VISHWAMBHAR
Consultant Radiologist
MBBS, DMRD
Reg No: 2012051018

Address : Tadoba Road, Tukum, Chandrapur, Infront of Mohurle Hospital, Mob.: 70204 90042