



First Trimester Screening Report

Tamanna Bagwan

Date of birth: 13 June 1996
Referring doctor: Dr. Kokare

Examination date: 01 April 2024
Patient id: 1067

History

Ethnic origin: South Asian (Indian, Pakistani, Bangladeshi).
Parity: 1; Spontaneous deliveries between 16-30 weeks: 0; 31-36 weeks: 0; Deliveries at or after 37 weeks: 1.
Maternal weight: 60.0 kg; Height: 157.5 cm.
Smoking in this pregnancy: no; Diabetes Mellitus: no; Chronic hypertension: no; Systemic lupus erythematosus: no; Antiphosph syndrome: no; PE in a previous pregnancy: no; Previous small baby: no.
Conception: spontaneous;
last period: 28 December 2023

EDD by dates: 03 October

First Trimester Ultrasound

US system: Voluson E 10 (BT 20). View: good.
Gestational age: 13 weeks + 4 days from dates

EDD by scan: 03 October

Findings	alive fetus	
Fetal heart activity	visualised	
FHR	160 bpm	
Crown-rump length (CRL)	78.5 mm	
Nuchal translucency (NT)	1.62 mm	
Biparietal diameter (BPD)	26.2 mm	
Head circumference (HC)	91.4 mm	
Abdominal circumference (AC)	72.4 mm	
Femur length (FL)	12.7 mm	
Intracranial translucency	present, 2.5 mm	
Ductus Venosus PI	0.88	
Placenta	appears normal	
Amniotic fluid	normal	

Chromosomal markers:

Nasal bone: present; Tricuspid Doppler: normal.

Fetal anatomy:

Skull/brain: appears normal; Spine: appears normal; Heart: four chambers three vessels seen; Abdomen: appears normal; Stomach: visible; Bladder / Kidneys: visible; Hands: both visible; Feet: both visible.

Comments: BS:BSOB ratio- 0.44.

Uterine artery mean PI:	1.805	equivalent to 1.190 MoM
Mean Arterial Pressure:	83.333 mmHg	equivalent to 1.0010 MoM
Endocervical length:	34.0 mm	

Risk calculation

Patient counselled and consent given.

FMF Operator: Sonal Phadtare, FMF Id: 198408

Condition	Background risk	Adjusted risk
Trisomy 21	1 in 844	1 in 5324



There is single viable intrauterine pregnancy corresponding to dates. The nuchal translucency measurements, nasal bone and fetal heart rate has reduced the maternal age related risk for chromosomal abnormalities from 1 in 844 to 1 in 5324.

The nasal bone is present. The Tricuspid valve and Ductus venosus Doppler are normal.

I have offered the option of early risk reassessment for aneuploidies (free bHCG, PAPP-A, PLGF and AFP), i.e. first trimester Quadruple marker test. This also assesses the risk for fetal Neural Tube Defects (NTDs), Fetal Growth Restrictions (FGR) and maternal pre-eclampsia (PE).

If the risk for maternal PE is more than 1:100, scientific evidence based on large study (the ASPRE study) from the Fetal medicine Foundation, UK, has shown that, administration of Aspirin 150mg to the mother at bedtime, would reduce the effects of PE for the mother by 50-80%.

The cervix measures 34 mm with no evidence of funneling. The uterine artery Doppler is normal for this gestation.

Index child has global developmental delay. The MRI s/o Pachygyria. Genetic evaluation has not been done. I have explained to the couple that as there is no established genetic diagnosis on the index child, prenatal testing on the ongoing pregnancy cannot be done. The couple has the option of genetic consultation with Clinical Geneticist.

The detection rate for chromosomal abnormalities with various screening tests are as follows-

First trimester NT scan only- 75%

First trimester Combined (NT + maternal blood test)- 80-85%

First trimester Combined test with 1T Quad marker- early screening for aneuploidies + fetal NTDs + FGR + maternal PE- 90% detection rate

Sequential screening (Combined + 2nd trimester Quadruple at 15-19w + Genetic sonogram at 18-20w) - 95%

Maternal blood test for cell free fetal DNA- 99%

Invasive testing (CVS/Amniocentesis), which is the definitive test has a procedure related risk of miscarriage about 1:300

After counselling, the couple decided against invasive testing.

Please note for all the future visits to ANY SCAN CENTRE, it is mandatory by the GOI to produce prior to the scan

1. Photocopy (xerox) of Government approved photo ID card of the prospective mother (Aadhaar card, passport, voter ID, driving licences etc)
2. Referral letter from your Doctor with indication for the scan with her/ his SEAL and SIGNATURE.

Also, please keep extra time to fill GOI mandated "F- Form" before the scan which needs to be submitted online prior to the scan.

Please note:

1. All anomalies cannot be ruled out on ultrasound due to technical limitations, maternal factors like amount of liquor, maternal habitus, previous scar, advanced gestational age etc. and fetal conditions like multiple pregnancies, fetal position, late appearance of few anomalies etc.
2. Absence of fetal anomalies on ultrasound scan does not absolutely rule out the possibility of having one.
3. The opinion reported is based on data generated by the computer, clinical correlation is required for deciding a treatment plan.

I Dr. Sonal Phadtare, declare that while conducting ultrasound/ image scanning on patient Mrs. Tamanna Bagwan, I have neither detected nor disclosed the sex of her fetus to anybody in any manner.

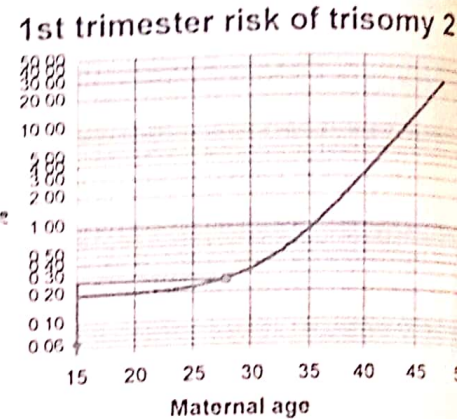
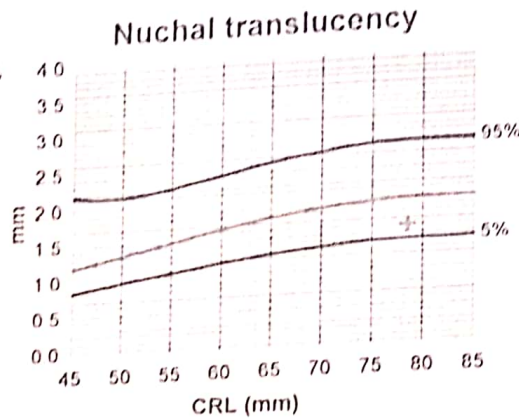
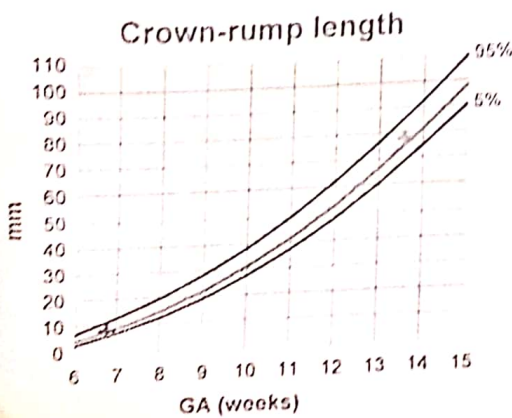
Recommendations Rescan at 18- 20 weeks to assess the fetal anatomy in detail (5th to 15th May)

Trisomy 18 1 in 2200 1 in 8265
Trisomy 13 1 in 6860 <1 in 20000

Preeclampsia before 37 weeks 1 in 366
Fetal growth restriction before 37 weeks 1 in 253
Spontaneous delivery before 34 weeks 1 in 379

The adjusted risk is the risk at the time of screening, calculated on the basis of the background risk and ultrasound factors (fetal nuchal translucency thickness, nasal bone, fetal heart rate).
The background risk for aneuploidies is based on maternal age (27 years). The adjusted risk is the risk at the time of screening, calculated on the basis of the background risk and ultrasound factors (fetal nuchal translucency thickness, nasal bone, fetal heart rate).
Risks for preeclampsia and fetal growth restriction are based on maternal demographic characteristics, medical and obstetric history.
The risk of spontaneous delivery before 34 weeks is based on maternal characteristics including racial origin, blood pressure (MAP) and uterine artery Doppler. The risk of spontaneous delivery before 34 weeks is based on maternal characteristics including racial origin and cervical length.

Biophysical marker medians used to calculate MoMs are corrected as necessary according to several maternal characteristics including racial origin, weight, height, smoking, method of conception and parity.
The estimated risk is calculated by the FMF-2018 software (version 4.4) and is based on findings from extensive research coordinated by the Fetal Medicine Foundation (UK Registered charity 1037116). The risk is only valid if the ultrasound scan was performed by a sonographer who has been accredited by the Fetal Medicine Foundation and has submitted results for regular audit (see www.fetalmedicine.org).



Doppler ultrasound

Uterine artery 2.290
PI left 1.320
PI right 1.805
Mean PI
RI left 0.82
RI right 0.68
Notch no notch



Ductus Venosus

A-wave positive
PIV 0.88

Cervical assessment

Cervix length 34.0 mm
Funnelling no
Comment normal cervical length
'Simple cyst' 56 mm x 39 mm x 48 mm Volume 54.9 cm³

Left ovary

Conclusions

Diagnosis No obvious fetal defects
normal uterine artery Doppler and cervical length

Conclusion routine scan adequate assessment

Recommendations Rescan at 18- 20 weeks to assess the fetal anatomy in detail (5th to 15th May)

Comments

