

डॉ. अकिता विजयवर्गीय

एम. बी. बी. एस., डी. एम. आर. डी
एम. आर. आई. फेलोशिप :
नानावटी हॉस्पिटल, मुंबई
हिंदुजा हॉस्पिटल, मुंबई
पूर्व रेडियोलॉजिस्ट :
फोर्टिस हॉस्पिटल, नोएडा
जी. टी. बी. हॉस्पिटल, दिल्ली
रीजेंसी हॉस्पिटल लिमिटेड, कानपुर
जवाहर लाल नेहरू कैंसर हॉस्पिटल, भोपाल

DR. ANKITA VIJAYVARGIYA

MBBS, DMRD

FMF Certified from
Fetal Medicine Foundation
Reg. No. MP-8932

MRI FELLOWSHIPS :

- NANAVATI HOSPITAL, MUMBAI
- HINDUJA HOSPITAL, MUMBAI

FORMER RADIOLOGIST AT:

- FORTIS HOSPITAL, NOIDA
- G.T.B HOSPITAL, DELHI
- REGENCY HOSPITAL LTD, KANPUR
- JAWAHAR LAL NEHRU CANCER HOSPITAL, BHOPAL

PATIENT'S NAME : MRS. AENTI

AGE/SEX : 32Y/F

REF. BY: DR. POOJA SHRIVASTAVA (MBBS, MS)

DATE : 01.05.2024

OBSTETRIC USG (EARLY ANOMALY SCAN)

LMP: 25.01.2024

GA(LMP):13wk 6d

EDD : 31.10.2024

- Single live fetus seen in the intrauterine cavity in variable presentation.
- Spontaneous fetal movements are seen. Fetal cardiac activity is regular and normal & is 164 beats /min.
- PLACENTA: is grade I, right antero-lateral & not low lying.
- LIQUOR: is adequate for the period of gestation.

Fetal morphology for gestation appears normal.

- Cranial ossification appears normal. Midline falx is seen. Choroid plexuses are seen filling the lateral ventricles. No posterior fossa mass seen. Spine is seen as two lines. Overlying skin appears intact.
- No intrathoracic mass seen. No TR .
- Stomach bubble is seen. Bilateral renal shadows is seen. Anterior abdominal wall appears intact.
- Urinary bladder is seen, appears normal. 3 vessel cord is seen.
- All four limbs with movement are seen. Nasal bone well seen & appears normal. Nuchal translucency measures 1.8 mm (WNL).
- Ductus venosus shows normal flow & spectrum with positive "a" wave (PI ~ 1.06)

FETAL GROWTH PARAMETERS

- | | | | | |
|---------------|---|----|-----|----------------------|
| ▪ CRL 75.5 mm | ~ | 13 | wks | 5 days of gestation. |
|---------------|---|----|-----|----------------------|

- Estimated gestational age is 13 weeks 5 days (+/- 1 week). EDD by USG : 01.11.2024
- Internal os closed. Cervical length is WNL (37.9 mm).
- Baseline screening of both uterine arteries was done with mean PI ~ 1.50 (WNL for gestation).
- Date of last delivery 22.09.2016 .
- Gestation at delivery of last pregnancy 42 weeks 1 days.

IPRESSION:

- Single, live, intrauterine fetus of 13 weeks 5 days +/- 1 week.
- Gross fetal morphology is within normal limits.

Follow up at 19-22 weeks for target scan for detailed fetal anomaly screening.

Declaration : I have neither detected nor disclosed the sex of the fetus to pregnant woman or to anybody. (It must be noted that detailed fetal anatomy may not always be visible due to technical difficulties related to fetal position, amniotic fluid volume, fetal movements, maternal abdominal wall thickness & tissue ecogenicity. Therefore all fetal anomalies may not be detected at every examination. Patient has been counselled about the capabilities & limitations of this examination.)

(DR. ANKITA VIJAYVARGIYA)

First Trimester Screening Report

Urway Aenti

Date of birth : 04 September 1992, Examination date: 01 May 2024

Address: hno. 00, gehukheda kolar
road
Bhopal
INDIA

Referring doctor: DR. (MS) POOJA SHRIVASTAVA

Maternal / Pregnancy Characteristics:

Racial origin: South Asian (Indian, Pakistani, Bangladeshi).

Parity: 1; Deliveries at or after 37 weeks: 1.

Maternal weight: 51.0 kg; Height: 157.5 cm.

Smoking in this pregnancy: no; Diabetes Mellitus: no; Chronic hypertension: no; Systemic lupus erythematosus: dont know; Antiphospholipid syndrome: dont know; Preeclampsia in previous pregnancy: no; Previous small baby: small; Patient's mother had preeclampsia: no.

Method of conception: Spontaneous;

Last period: 25 January 2024




EDD by dates: 31 October 2024

First Trimester Ultrasound:

US machine: logiq f6. Visualisation: good.

Gestational age: 13 weeks + 6 days from dates

EDD by scan: 31 October 2024

Findings	Alive fetus	
Fetal heart activity	visualised	
Fetal heart rate	164 bpm	
Crown-rump length (CRL)	75.5 mm	
Nuchal translucency (NT)	1.8 mm	
Ductus Venosus PI	1.060	
Placenta	high, right antero lateral	
Amniotic fluid	normal	
Cord	3 vessels	

Chromosomal markers:

Nasal bone: present; Tricuspid Doppler: normal.

Fetal anatomy:

Skull/brain: appears normal; Spine: appears normal; Heart: No TR.; Abdominal wall: appears normal; Stomach: visible; Bladder / Kidneys: visible; Hands: both visible; Feet: both visible.

Uterine artery PI:	1.50	equivalent to 0.970 MoM
Mean Arterial Pressure:	77.7 mmHg	equivalent to 0.960 MoM
Endocervical length:	37.9 mm	

Risks / Counselling:

Patient counselled and consent given.

Operator: DR. ANKITA VIJAYVARGIYA, FMF Id: 204664

Condition	Background risk	Adjusted risk
Trisomy 21	1: 532	1: 8883
Trisomy 18	1: 1369	1: 7075
Trisomy 13	1: 4275	<1: 20000

First Trimester Screening Report

Preeclampsia before 34 weeks

1: 5891

Fetal growth restriction before 37 weeks

1: 294

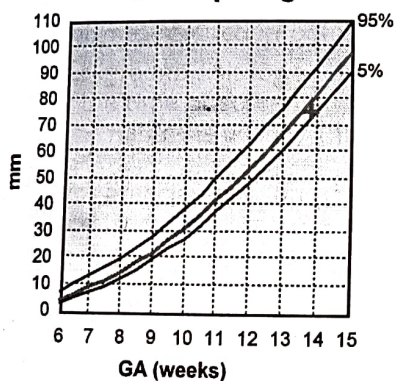
The background risk for aneuploidies is based on maternal age (31 years). The adjusted risk is the risk at the time of screening, calculated on the basis of the background risk and ultrasound factors (fetal nuchal translucency thickness, nasal bone, tricuspid Doppler, fetal heart rate).

Risks for preeclampsia and fetal growth restriction are based on maternal demographic characteristics, medical and obstetric history, uterine artery Doppler and mean arterial pressure (MAP).

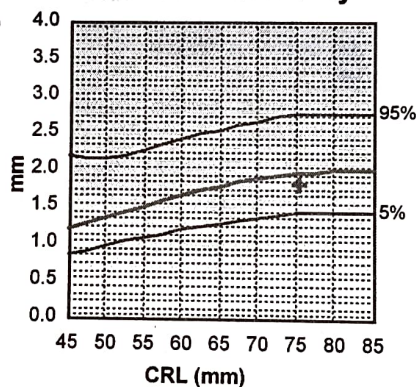
All biophysical markers are corrected as necessary according to several maternal characteristics including racial origin, weight, height, smoking, method of conception and parity.

The estimated risk is calculated by the FMF-2012 software (version 2.81) and is based on findings from extensive research coordinated by the Fetal Medicine Foundation (UK Registered charity 1037116). The risk is only valid if the ultrasound scan was performed by a sonographer who has been accredited by the Fetal Medicine Foundation and has submitted results for regular audit (see www.fetalmedicine.com).

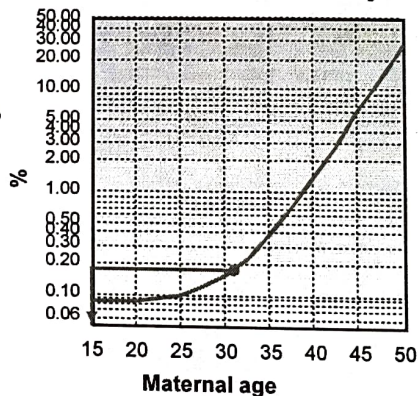
Crown-rump length



Nuchal translucency



1st trimester risk of Trisomy 21



(14)

mas - ~~Aend~~ wway
Aenfi

32/P

Double marking

weight - 58.0 kg -

Height - 4.9 inch.

DOB - 04-september-1992

