

DECLARATION OF PREGNANT WOMAN

I, Mrs. ☒ NIKITA RATNAKAR DHOND

असे घोषित करते की अल्ट्रा-सोनोग्राफी/प्रतिमा स्कॅनिंग करून मी माझ्या गर्भाचे लिंग जाणून घेऊ इच्छित नाही. /declare that by undergoing ultrasonography/image scanning etc. I do not want to know the sex of my foetus.

Nikita

गरोदर स्त्रीची सही/अंगठ्याचा ठसा./Signature/Thump impression of pregnant woman

DECLARATION OF DOCTOR

I, Dr. APEKSHA UTTAMRAO CHAVAN

undergoing ultrasonography/image scanning on patient

☒ declare that while

Mrs. ☒ NIKITA RATNAKAR DHOND

I have neither detected nor disclosed the sex of her foetus to anybody in any manner.

Signature of the person conducting Ultrasonography/Image scanning/Director or owner of genetic clinic/ultrasound clinic/imaging centre.

DR. APEKSHA U. CHAVAN
MBBS, MD, DNB (RADIOLOGY)
Reg. No. 2011/09/3126

... .. Thickness - 0.10 cm.

- B. Other markers : 1. Nasal bones seen.
2. Limb buds normal.

- C. Doppler : Ductus venosus flow normal.
D. No e/o tricuspid regurgitation.

PTO



Dr. Apeksha Rathod
MD DNB Radiology

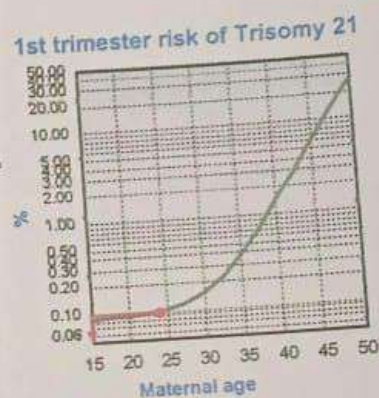
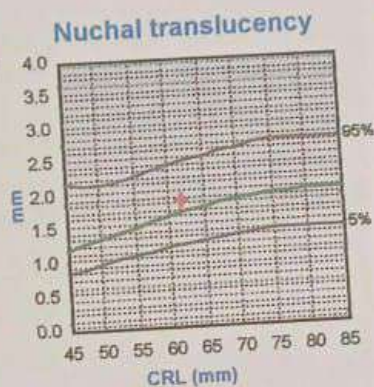
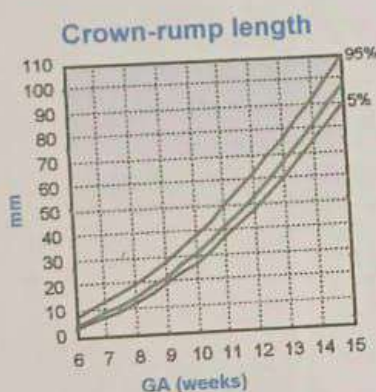
First Trimester Screening Report

The background risk for aneuploidies is based on maternal age (24 years). The adjusted risk is the risk at the time of screening, calculated on the basis of the background risk and ultrasound factors (fetal nuchal translucency thickness, fetal heart rate).

Risks for preeclampsia and fetal growth restriction are based on maternal demographic characteristics, medical and obstetric history, uterine artery Doppler and mean arterial pressure (MAP).

All biophysical markers are corrected as necessary according to several maternal characteristics including racial origin, weight, height, smoking, method of conception and parity.

The estimated risk is calculated by the FMF-2012 software (version 2.81) and is based on findings from extensive research coordinated by the Fetal Medicine Foundation (UK Registered charity 1037116). The risk is only valid if the ultrasound scan was performed by a sonographer who has been accredited by the Fetal Medicine Foundation and has submitted results for regular audit (see www.fetalmedicine.com).



DR. APARNA U. SHIVAN
MBBS, MD, DNB (RADIOLOGY)
Reg. No. 2011/09/2139

[Signature]

First Trimester Screening Report

DHOND NIKITA RATNAKAR

Date of birth : 26 June 1999, Examination date: 06 April 2024

Maternal / Pregnancy Characteristics:

Racial origin: South Asian (Indian, Pakistani, Bangladeshi).

Parity: 1; Spontaneous deliveries between 16-30 weeks: 0; 31-36 weeks: 0; Deliveries at or after 37 weeks: 1.

Maternal weight: 43.0 kg; Height: 149.0 cm.

Smoking in this pregnancy: no; Diabetes Mellitus: no; Chronic hypertension: no; Systemic lupus erythematosus: no; Antiphospholipid syndrome: no; Preeclampsia in previous pregnancy: no;

Previous small baby: no; Patient's mother had preeclampsia: no.

Method of conception: Spontaneous;

Last period: 04 January 2024

EDD by dates: 10 October 2024

First Trimester Ultrasound:

US machine: VINNO G 65. Visualisation: good.

Findings	Alive fetus
Fetal heart activity	visualised
Fetal heart rate	149 bpm
Crown-rump length (CRL)	62.0 mm
Nuchal translucency (NT)	1.9 mm
Biparietal diameter (BPD)	21.6 mm
Ductus Venosus PI	0.870
Placenta	posterior high
Amniotic fluid	normal
Cord	3 vessels

Chromosomal markers:

Nasal bone: present; Tricuspid Doppler: normal.

Fetal anatomy:

Skull/brain: appears normal; Spine: appears normal; Abdominal wall: appears normal; Stomach: visible; Bladder / Kidneys: visible; Hands: both visible; Feet: both visible.

Uterine artery PI:	1.31	equivalent to 0.770 MoM
Mean Arterial Pressure:	70.8 mmHg	equivalent to 0.900 MoM
Endocervical length:	44.0 mm	

Risks / Counselling:

Patient counselled and consent given.

Operator: apeksha chavan, FMF Id: 250746

Condition	Background risk	Adjusted risk
Trisomy 21	1: 974	1: 3692
Trisomy 18	1: 2358	1: 7147
Trisomy 13	1: 7405	<1: 20000
Preeclampsia before 34 weeks		1: 16147
Fetal growth restriction before 37 weeks		1: 251
Spontaneous delivery before 34 weeks		1: 1942



KALPATARU DIAGNOSTIC CENTRE

Dr. Apeksha Rathod

MBBS (MUHS Gold Medal)
MD Radiology (MUHS Silver Medal), DNB Radiology
FMP UK Certified for First Trimester Screening
(FMP Id-250746)

**Sonography, Colour Doppler
& Digital X-Ray**

Name of Pt : Mrs. Nikita Ratnakar Dhond

Ref BY : Dr Chandaliya madam

Dated : April 6, 2024

SONOGRAPHY OF GRAVID UTERUS

LMP:04/01/2024

GA(LMP): 13 wks 2 days

EDD by LMP: 10/10/2024

Single viable intrauterine fetus is seen with **changing presentation** at the time of examination.

Fetal movements and cardiac pulsation are well appreciated. **FHR: 147 bpm.**

Placenta is posterior. Grade I maturity.

Liquor is adequate for gestational age.

Cervical length: 4.4 cm

FOETAL BIOMETRY:-

CRL : 6.20 cm corresponding to 12 wks 4 days

BPD : 2.16 cm corresponding to 13 wks 4 days

HC : 8.55 cm corresponding to 13 wks 5 days

AC : 6.31 cm corresponding to 13 wks 0 days

FML : 0.81 cm corresponding to 12 wks 3 days

These parameters correspond with sonic maturity of around 13 wks 0 day.

EFW is 64 gms .

A. NT : well demonstrated. Thickness - 0.18 cm.

B. Other markers : 1. Nasal bones seen.

2. Limb buds normal.

C. Doppler : Ductus venosus flow normal.

D. No e/o tricuspid regurgitation.

PTO



Dr. Apeksha Rathod
MD DNB Radiology



KALPATARU DIAGNOSTIC CENTRE

Dr. Apeksha Rathod

MBBS (MUHS Gold Medal)
MD Radiology (MUHS Silver Medal), DNB Radiology
FMF UK Certified for First Trimester Screening
(FMF 16-250746)

**Sonography, Colour Doppler
& Digital X-Ray**

Fetal survey:

Head: cranial vault – normal. Midline Falx seen.

Choroid plexuses seen filling the ventricular cavity (butterfly sign)

Intracranial translucency – normal.

Facial profile : PMT seen.

Spine : intact overlying skin.

Chest: Symmetrical lung fields noted . No e/o effusion or masses.

Heart :cardiac activity regular. Four symmetrical chambers seen.

On color flow : two ventricular inflow s and two outflows tracts seen.

Abdomen : normal cord insertion. Stomach in left upper quadrant , bladder seen.

Extremities : four limbs each with three segments seen.

Uterine arteries:

Right : PI: 1.47

Left : PI: 1.15

Mean PI : 1.3— (24th percentile) normal for gestational age.

Both uterine arteries show normal color flow and spectral waveform

No early diastolic notch seen.

OPINION : Single live intrauterine gestation with average sonic maturity of around

13 wks 0 day. EDD by USG: 12/10/2024

GA assigned as per biometry.

CRL measures 6.20 cm. NT measures 0.18 cm (60th percentile for this CRL) .

Suggested follow up anomaly scan at 20-22 weeks

Thanks for referral

All measurements including estimated fetal weight, are subject to statistical variations.
Not all anomalies can be detected on sonography.

First trimester screening and preeclampsia report attached -----PTO



Dr. Apeksha Rathod
MD DNB Radiology