

डॉ. अंकिता विजयवर्गीय

एम. बी. बी. एस., डी. एम. आर. डी
एम. आर. आई. फेलोशिप :
नानावटी हॉस्पिटल, मुंबई
हिंदुजा हॉस्पिटल, मुंबई
पूर्व रेडियोलॉजिस्ट :
फोर्टिस हॉस्पिटल, नोएडा
जी. टी. बी. हॉस्पिटल, दिल्ली
रीजेंसी हॉस्पिटल लिमिटेड, कानपुर
जवाहर लाल नेहरू कैंसर हॉस्पिटल, भोपाल

DR. ANKITA VIJAYVARGIYA MBBS, DMRD

MRI FELLOWSHIPS :

- NANAVATI HOSPITAL, MUMBAI
- HINDUJA HOSPITAL, MUMBAI

FORMER RADIOLOGIST AT:

- FORTIS HOSPITAL, NOIDA
- G.T.B HOSPITAL, DELHI
- REGENCY HOSPITAL LTD, KANPUR
- JAWAHAR LAL NEHRU CANCER HOSPITAL, BHOPAL

FMF Certified from

Fetal Medicine Foundation

Reg. No. MP-8932

PATIENT'S NAME : MRS.SUSHMA

AGE/SEX : 25Y/F

REF. BY : DR. MINOO SHUKLA (MBBS, MS)

DATE : 20.05.2024

OBSTETRIC USG (EARLY ANOMALY SCAN)

LMP: 19.02.2024

GA(LMP):13wk 0d

EDD : 25.11.2024

- Single live fetus seen in the intrauterine cavity in **variable** presentation.
- Spontaneous fetal movements are seen. Fetal cardiac activity is regular and normal & is 160 beats /min.
- PLACENTA: is **grade I, posterior & not low lying**.
- LIQUOR: is **adequate** for the period of gestation.

Fetal morphology for gestation appears normal.

- Cranial ossification appears normal. Midline falx is seen. Choroid plexuses are seen filling the lateral ventricles. No posterior fossa mass seen. Spine is seen as two lines. Overlying skin appears intact.
- No intrathoracic mass seen. No TR .
- Stomach bubble is seen. Bilateral renal shadows is seen. Anterior abdominal wall appears intact.
- Urinary bladder is seen, appears normal. 3 vessel cord is seen.
- All four limbs with movement are seen. Nasal bone well seen & appears normal. Nuchal translucency measures 1.8 mm (WNL).
- Ductus venosus shows normal flow & spectrum with positive "a" wave (PI ~ 0.72)

FETAL GROWTH PARAMETERS

- | | | | |
|---------------|---|--------|----------------------|
| ▪ CRL 64.8 mm | ~ | 12 wks | 6 days of gestation. |
|---------------|---|--------|----------------------|

- Estimated gestational age is **12 weeks 6 days (+/- 1 week)**. EDD by USG : 26.11.2024
- Internal os closed. Cervical length is WNL (32.2 mm).
- Baseline screening of both uterine arteries was done with mean PI ~ 0.66 (Low for gestation).

MPRESSION:

- ✚ Single, live, intrauterine fetus of 12 weeks 6 days +/- 1 week.
- ✚ Gross fetal morphology is within normal limits.

Follow up at 19-22 weeks for target scan for detailed fetal anomaly screening.

Declaration : I have neither detected nor disclosed the sex of the fetus to pregnant woman or to anybody. (It must be noted that detailed fetal anatomy may not always be visible due to technical difficulties related to fetal position, amniotic fluid volume, fetal movements, maternal abdominal wall thickness & tissue ecogenicity. Therefore all fetal anomalies may not be detected at every examination. Patient has been counselled about the capabilities & limitations of this examination.)

(DR. ANKITA VIJAYVARGIYA)

First Trimester Screening Report

Meena Sushma

Date of birth : 20 June 1999, Examination date: 20 May 2024

Address: hno. 29, guradi ghat kolar road
Bhopal
INDIA

Referring doctor: Dr. Shukla Minoo

Maternal / Pregnancy Characteristics:

Racial origin: South Asian (Indian, Pakistani, Bangladeshi).

Parity: 0.

Maternal weight: 49.0 kg; Height: 165.1 cm.

Smoking in this pregnancy: no; Diabetes Mellitus: no; Chronic hypertension: no; Systemic lupus erythematosus: dont know; Antiphospholipid syndrome: dont know; Patient's mother had preeclampsia: no.

Method of conception: Spontaneous;

Last period: 19 February 2024


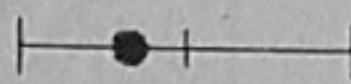

EDD by dates: 25 November 2024

First Trimester Ultrasound:

US machine: logiq f6. Visualisation: good.

Gestational age: 13 weeks + 0 days from dates

EDD by scan: 25 November 2024

Findings	Alive fetus	
Fetal heart activity	visualised	
Fetal heart rate	160 bpm	
Crown-rump length (CRL)	64.8 mm	
Nuchal translucency (NT)	1.8 mm	
Ductus Venosus PI	0.720	
Placenta	posterior high	
Amniotic fluid	normal	
Cord	3 vessels	

Chromosomal markers:

Nasal bone: present; Tricuspid Doppler: normal.

Fetal anatomy:

Skull/brain: appears normal; Spine: appears normal; Heart: No TR.; Abdominal wall: appears normal; Stomach: visible; Bladder / Kidneys: visible; Hands: both visible; Feet: both visible.

Uterine artery PI:	0.66	equivalent to 0.400 MoM
Mean Arterial Pressure:	70.1 mmHg	equivalent to 0.870 MoM
Endocervical length:	32.2 mm	

Risks / Counselling:

Patient counselled and consent given.

Operator: DR. ANKITA VIJAYVARGIYA, FMF Id: 204664

Condition	Background risk	Adjusted risk
Trisomy 21	1: 976	1: 19512
Trisomy 18	1: 2393	1: 14705
Trisomy 13	1: 7505	<1: 20000
Preeclampsia before 34 weeks		<1: 20000