

UUSPN 

OPD No: 595901

Name: MRS. BHARTI SHARMA

Sex/Age: F/26Y 2M

DOB: 04-02-1998

Vill & Post & Tah- Thankhamhariya Dist-Bemetara CHHATTISGARH, INDIA

Mobile: 8770951925

Date: 24-04-2024 13:03 PM

Report Date: 24-04-2024 14:20 PM

ULTRASOUND PREGNANCY NUCHAL
TRANSLUCENCY EVALUATION(RPID2230)

Referred By: Dr. Yogita Chandravanshi

ULTRASOUND PREGNANCY NUCHAL TRANSLUCENCY EVALUATION

FINDINGS

LMP - Last menstrual period : 26/01/2024 (GA by LMP- 12 weeks 05 days)

A single intrauterine gestational sac is seen. Fetal pole is visualized.

CRL - Crown rump length : 56 mms. compatible with 12 Wks 02 dys

FETAL CARDIAC ACTIVITY

HR : 160 bpm

Cardiac activity is present.

CERVIX

Cervical. Internal OS is closed.

PLACENTA

Placenta is Anterior.

Parameters

Nuchal thickness is 2 mm.

Nasal bone is visualized and measures 2 mm.

Ductus venosus shows normal flow pattern. No reversal of 'a' wave is seen.

IMPRESSION


- Single live intrauterine gestation with CRL corresponding to 12 week's 02 day.
- USG EDD- 04/11/2024.

Advice- Anomaly scan between 18-22 weeks

Please correlate clinically.

I Dr. Vineet maheshwari declare that while conducting USG scanning of Mrs. Bharti Sharma ,I have neither detected nor discussed the sex of her foetus to anybody in any manner.

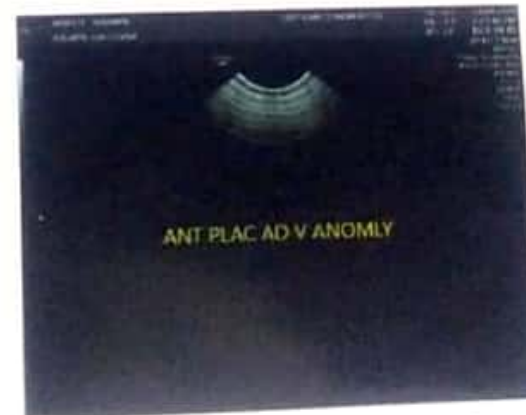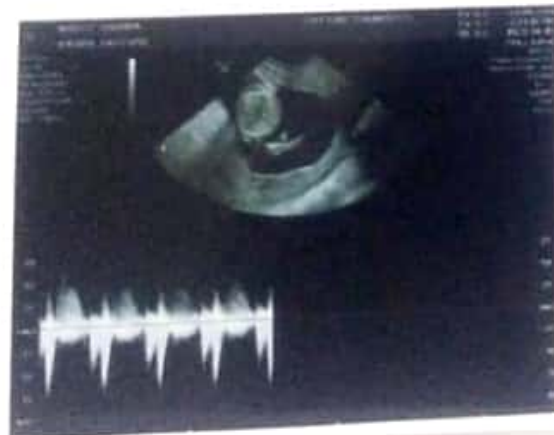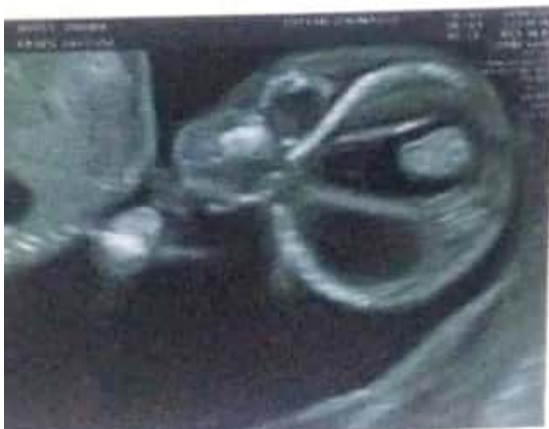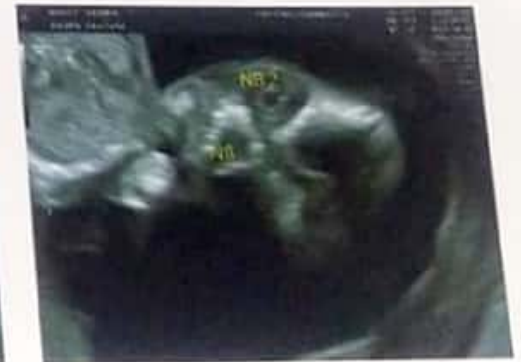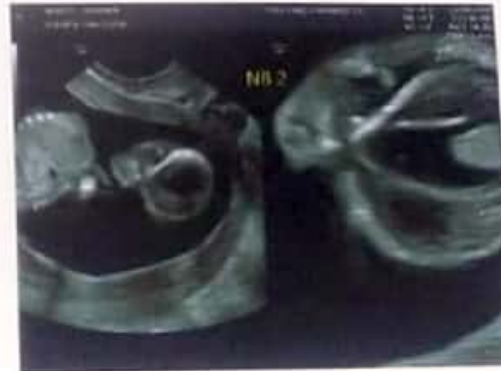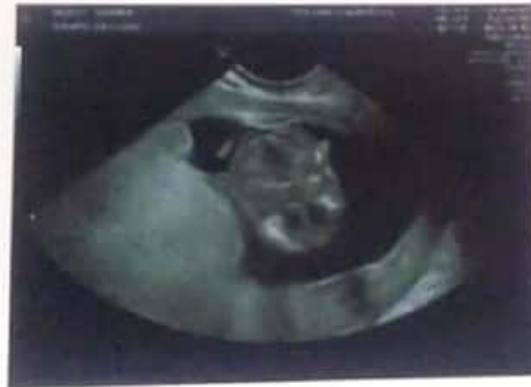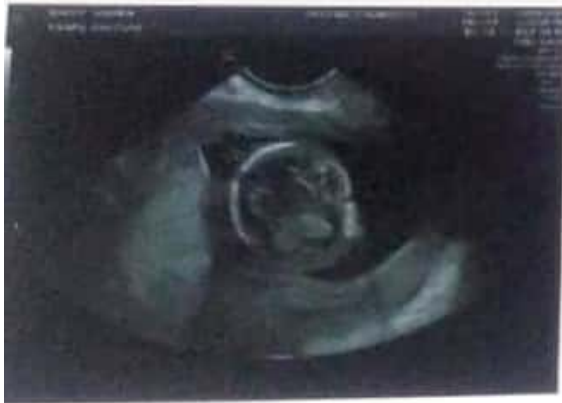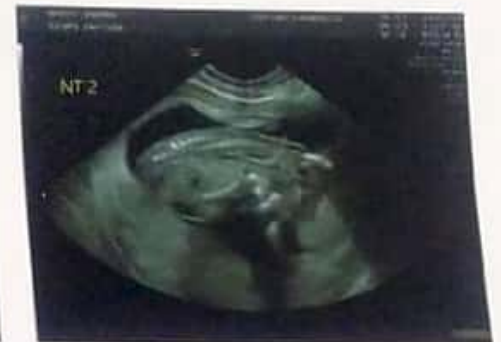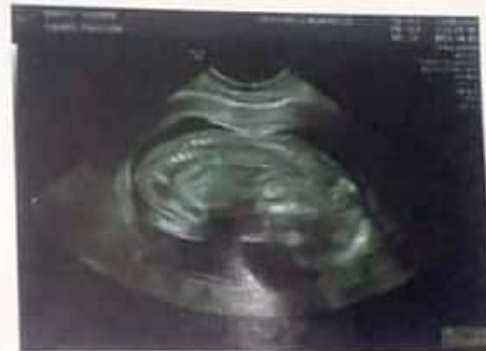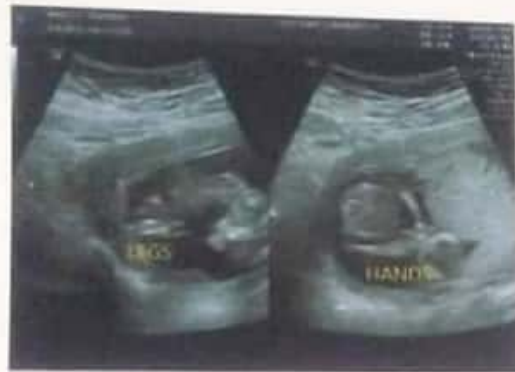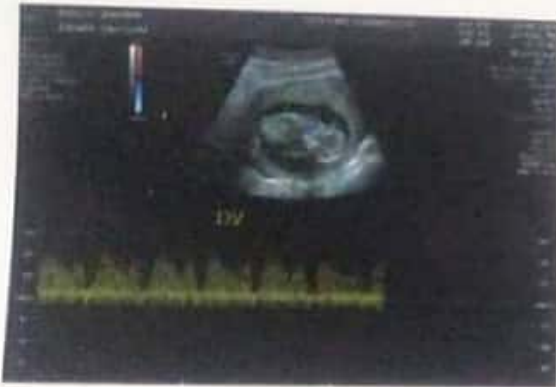Dr. Ravindra Deshmukh
DNB Radiodiagnosis


Dr. Vineet Maheshwari
DNB, DMRD, (FRCR)

ID: 1UU6PN

BHARTI SHARMA

Exam Date: 24.04.2024 2:13:25 PM



Bharti Sharma

Height - 5.3

Weight - 80kg

DOB - 04/02/1998