

| | | | |
|-----------|----------------|----------|------------|
| PT. NAME: | MRS. LIPIKA | AGE/SEX: | 22/F |
| REF. BY: | DR.SAPNA BAJAJ | DATE: | 24/05/2024 |

OBSTETRIC ULTRASOUND (NT/NB scan)/early anomaly scan

| | |
|--------------|---------------|
| LMP | 17.02.2024 |
| DGA (BY LMP) | 13WEEKS 6DAYS |

- Gravid uterus reveals single intrauterine gestation sac.
- Single fetus seen.
- ***CRL IS 7.34cm corresponding to 13week 3day of estimated gestational age.***
- ***Cardiac activity is observed. FHR= 164 beats/min.***
- ***Fetal head,choroid plexuses,spine,limbs appear normal for GA.***
- **Trisomy marker :**
 - ✓ **NT- 1.12mm, nasal bones are seen.**
 - ✓ **Normal ductus venosus flow .**
 - ✓ **No e/o tricuspid regurgitation noted .**
- **Placenta is developing in ANTERIOR wall.** Chorionic lining is smooth & regular.
- No evidence of extra chorionic sac separation is seen.
- Internal OS of cervix is closed and endocervical canal appears normal.
- **UTERINE ARTERY PI VALUES**-RT UT ARTERY PI=0.67 LT UT ARTERY PI=1.1

IMPRESSION: Sonography obstetric reveals single live intrauterine early gestation corresponding to 13weeks 3days of estimated gestational age.

EDD:-26.11.2024

Advice: Target scan at 18 -20 week.

I DR. KANCHAN CHOUBEY, DMRD,DNB DECLARE THAT WHILE CONDUCTING USG I HAVE NEITHER DECLARED NOR DISCLOSED THE SEX OF HER FETUS TO ANYBODY IN ANY MANNER

DR KANCHAN CHOUBEY DMRD, DNB

Note: This report is an opinion not final diagnosis. It Should be correlated clinically with history and examination of patient.
In case of any discrepancy a review can be asked. Not valid for medicolegal purpose.

SonoView II

Name LIPIKA

ID 41216-24-05-24-2

Age

Sex

F

1 / 2

Open

Current Exam

View Mode

Exam



Layouts



Exam Navigator

41216-24-05-24-31

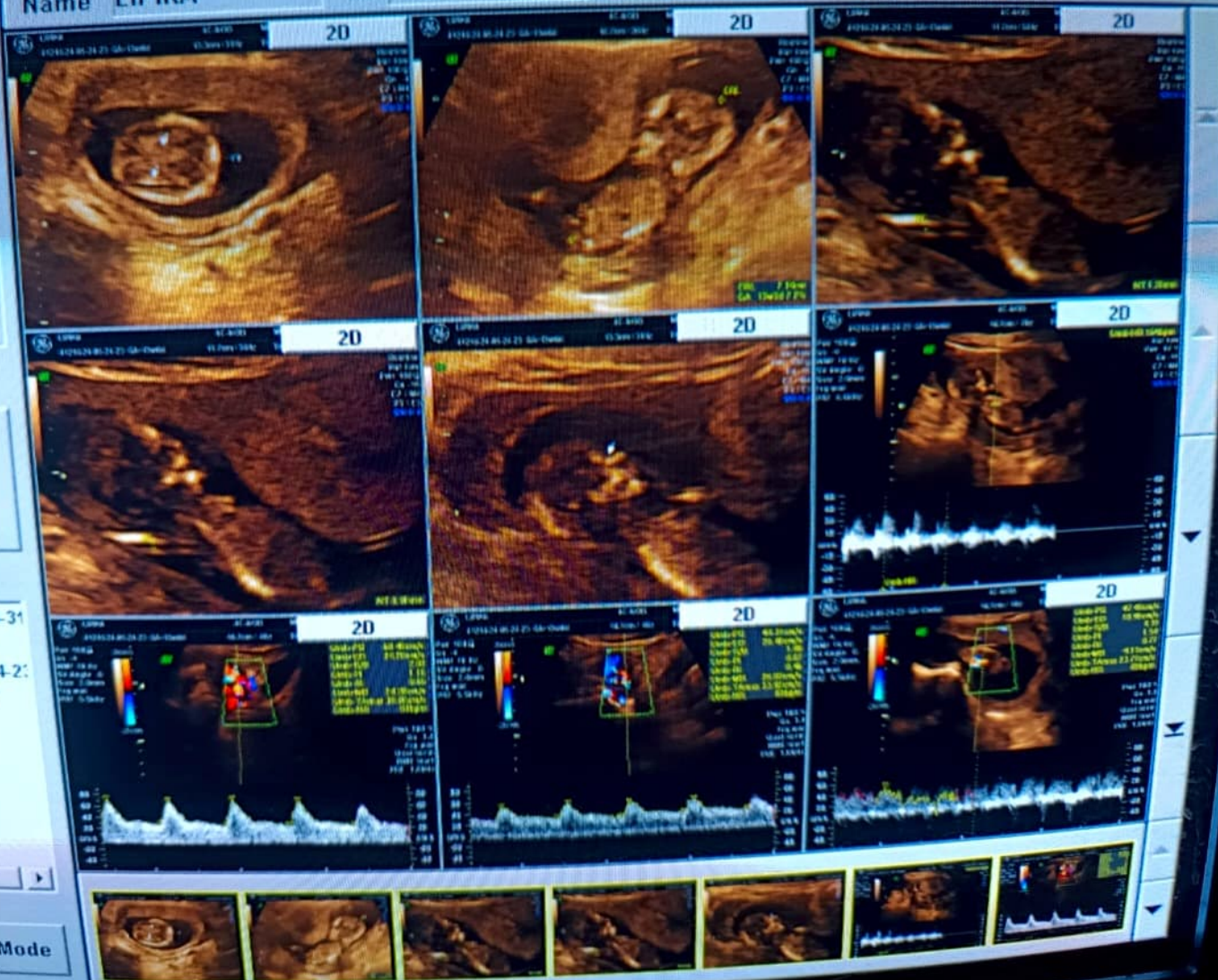
24/05/2024

41216-24-05-24-2

24/05/2024



Scan Mode



Open

Current Exam

Exam



Layouts



41216-24-05-24-31
24/05/2024

41216-24-05-24-21
24/05/2024



Scan Mode

