

Name = Amisha Dixit

Date of Birth = 06/01/93

Weight = 80 kg.

Hight = 5'3

P. Mobile No. = 6264666117

Dr. Mo. No. = 7504567800, 7752412594

Dr. Name = Shehal pendalwar.

"Shri Gopal"

SAHU DIAGNOSTIC CENTER

DR. MAMTA SAHU
MBBS, DMRD
Consulting Radiologist
Reg. No. CGMC379/2005

In front of CIMS Main Gate, Bilaspur (C.G.) 495 001 Mo.: 9755230012 (Clinic)

Pt. Name : Mrs. AMISHA DIXIT
Ref. By : Dr. Mrs. S. PENDALWAR (DGO)

Age/Sex : 31 Yrs/F
Date : 10/06/2024

OBSTETRIC SONOGRAPHY REPORT (N.T. SCAN)

Indication No:- 10

(Detection of chromosomal abnormalities, fetal structural defects and other abnormalities and their follow up).

LMP : 08/03/2024

GA : 13 WKS 3 DAYS

EDD : 13/12/2024

There is a single, live, intrauterine foetus is seen with **variable presentation** at the time of examination.

Cardiac pulsations are visualized normal. **FHR: 141 b/min**

Foetal Movements : (++) Visualized normal.

The CRL = 67.0 mm = 13 wks 0 day. (20 % ILE)

The BPD = 22.4 mm = 13 wks 5 days. (45 % ILE)

The usg guided E.D.D. is 16/12/2024 (+/- 1 wks).

Placenta is located **anterior** in upper uterine segment & shows **grade 1 Maturity**.

Amniotic fluid is **adequate** for gestational age.

Cervix appears normal. Cervical length is 3.9 cm. Internal os is closed.

EVALUATION FOR FETAL ANATOMY

Nuchal translucency measures 0.9 mm.

Nasal bone visualized.

Ductus venous show normal flow, no pulsatile flow seen.

Intracranial structures appears normal.

Spine appears normal. No e/o significant open neural tube defect.

Fetal face appears normal.

Abdominal situs appears normal.

Bladder appears normal.

All four limbs are visualized.

Page 1/2

P.T.O.

**PRE-NATAL SEX
DETERMINATION
IS NOT DONE HERE**

ULTRASOUND DIAGNOSIS IS BASIS ON APPEARANCE OF GRAY SCALE SHADES, AND IT IS ALSO AFFECTED BY TECHNICAL PITFALLS. HENCE IT SUGGESTED TO CO-RELATE ULTRASOUND OBSERVATION WITH CLINICAL AND OTHER INVESTIGATIVE FINDING TO REACH THE FINAL DIAGNOSIS. NO LEGAL LIABILITY IS ACCEPTED. NOT FOR MEDICO-LEGAL PURPOSE

"Shri Gopal"
SAHU DIAGNOSTIC CENTER

In front of CIMS Main Gate, Bilaspur (C.G.) 495 001 Mo.: 9755230012 (Clinic)

DR. MAMTA SAHU
MBBS, DMRD
Consulting Radiologist
Reg. No. CGMC379/2005

UTERINE ARTERY

- Rt Uterine artery- S/D ratio is 2.4 & PI is 1.0 (normal)
- Lt Uterine artery- S/D ratio is 4.8 & PI is 2.0 (increased)
(Mean PI is 1.5 increased)
- No dichotic notch seen in each uterine artery

IMPRESSION:- SINGLE, LIVE, INTRAUTERINE FETUS SEEN WITH VARIABLE PRESENTATION
AT THE TIME OF EXAMINATION WITH SONIC MATURITY OF 13-14 WKS.
➤ MEAN UTERINE PI IS INCREASED. (SCREEN POSITIVE FOR PIH)

Suboptimal scan due to maternal fat.

Suggested follow up at 18-20 wks for detailed evaluation of fetus.

Thanks for reference.

All measurements including estimated fetal weight are subjected to statical variation.
Not all anomalies can be detected on sonography.

Declaration :- I Dr. Mamta Sahu declare that while conducting usg of Mrs. Amisha Dixit, W/o Mr. Deepak
Dixit, I have neither detected nor disclosed the sex of her foetus to anybody in any manner.
Please intimate us if any typing mistakes and send the report for correction within 5 days.

Page 2/2

Dr. Mrs. Mamta Sahu
DMRD

**PRE-NATAL SEX
DETERMINATION
IS NOT DONE HERE**

ULTRASOUND DIAGNOSIS IS BASIS ON APPEARANCE OF GRAY SCALE SHADES, AND IT IS ALSO AFFECTED BY TECHNICAL
PITFALLS. HENCE IT SUGGESTED TO CO-RELATE ULTRASOUND OBSERVATION WITH CLINICAL AND OTHER INVESTIGATIVE
FINDING TO REACH THE FINAL DIAGNOSIS. NO LEGAL LIABILITY IS ACCEPTED. NOT FOR MEDICO-LEGAL PURPOSE

पेन्डलवार नर्सिंग होम प्रसूति गृह

Dr. Vijaya Pandalwar
डॉ. विजया पेन्डलवार
एम.बी.बी.एस.
स्त्री रोग चिकित्सक
Reg. No.: CGMC/914/2007



Dr. Snehal Pandalwar Arora
डॉ. स्नेहल पेन्डलवार अरोरा
एम.बी.बी.एस., डी.जी.ओ.
स्त्री रोग विशेषज्ञ
Reg. No.: CGMC/1371/2008
CGMC/184/2019, MCI Cer. 11-10841

24 घंटे भर्ती (एडमिशन) की सुविधा

फोन : 07752-412594, मो. : 7504567800



ओपीडी - सोमवार से शनिवार - सुबह 10.00 से 02.00 बजे एवं शाम 06.00 से 08.00 बजे तक, रविवार : अवकाश

नर्सिंग होम एवं निवास : मेन रोड, तोरवा, बिलासपुर (छ.ग.)

Amisha Dixit

Date 8/1/24

Rx

1-120/72 (MF 8/3/14

END 16/12/14

AB time

114 gms.

1 CT 2-39

BD
CT 12

AB 1-104

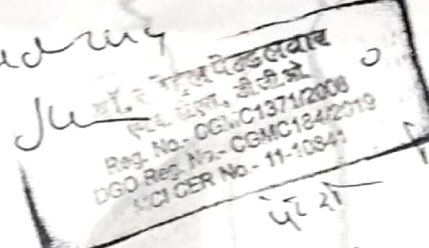
PM
check 72

Ca-ferrugus

Ca-ferrugus

Ca 311

admission



R. 2 बजे वालीफे

R bit 10-30

Sayedok 10-30

Ca-ferrugus 10-30

Ca-ferrugus 10-30

Ca-ferrugus 10-30

Ca-ferrugus 10-30

Ca-ferrugus 10-30

Ca-ferrugus 10-30

Ca-ferrugus 10-30

Ca-ferrugus 10-30

Ca-ferrugus 10-30

Ca-ferrugus 10-30

Ca-ferrugus 10-30

Ca-ferrugus 10-30

Ca-ferrugus 10-30

Ca-ferrugus

Ca-ferrugus

Ca-ferrugus

Ca-ferrugus

Ca-ferrugus

प्रसूता हेतु एम्बुलेंस द्वारा अस्पताल पहुंच सेना गुप्त, मो. : 9302909023

सिंग मेडिकल स्टोर्स

डॉ. पेन्डलवार नर्सिंग होम परिसर, मेन रोड, तोरवा, बिलासपुर (छ.ग.)

दवा मिलने का एकमात्र स्थान :