

150

~~150~~

MR PRINCE SIMON 29/11

Double  
number

UTS 24.0K9.

Height → 5.5

P.O.B → 1210911993

1.5. 014. 15/11/93  
106/1

201 #4.06  
BP 111/66  
Pulse 96/min  
Temp 98.6°F

22 JUN 2024


Notes  
DOKINTE 200  
SOPAS 100

Notes Natunogen 200 mg

Notes  
Kulit Uthi 100

Notes  
Dysentri 25 mg

Notes  
Trapezoid 180 x 2



Prescription  
Lipid  
D

11/11/24

Notes  
Dysentri  
Kulit Uthi

Notes

# डॉ. अंकिता विजयवर्गीय

एम. बी. बी. एस., डी. एम. आर. डी

एम. आर. आई. फेलोशिप :

नानावटी हॉस्पिटल, मुंबई

हिंदुजा हॉस्पिटल, मुंबई

पूर्व रेडियोलॉजिस्ट :

फोर्टिस हॉस्पिटल, नोएडा

बी. टी. बी. हॉस्पिटल, दिल्ली

जिर्जी हॉस्पिटल लिमिटेड, कानपुर

जवाहर लाल नेहरू कैंसर हॉस्पिटल, भोपाल

# DR. ANKITA VIJAYVARGIYA

MBBS, DMRD

FMF Certified from

Fetal Medicine Foundation

Reg. No. MP-5932

## MRI FELLOWSHIPS :

- NANAVATI HOSPITAL, MUMBAI

- HINDUJA HOSPITAL, MUMBAI

## FORMER RADIOLOGIST AT:

- FORTIS HOSPITAL, NOIDA

- G.T.B HOSPITAL, DELHI

- REGENCY HOSPITAL LTD, KANPUR

- JAWAHAR LAL NEHRU CANCER HOSPITAL, BHOPAL

PATIENT'S NAME : MRS. PRINSHU

REF. BY : DR. POOJA SHRIVASTAVA ( MBBS, MS )

AGE/SEX : 29Y/F

DATE : 21.06.2024

## OBSTETRIC USG ( EARLY ANOMALY SCAN )

LMP: 20.03.2024

GA(LMP):13wk 2d

EDD : 25.12.2024

- Single live fetus seen in the intrauterine cavity in variable presentation.
- Spontaneous fetal movements are seen. Fetal cardiac activity is regular and normal & is 164 beats /min.
- PLACENTA: is grade I, left postero-lateral with lower edge just reaching upto internal os. Mild retroplacental hemorrhage is seen .
- LIQUOR: is adequate for the period of gestation.

### Fetal morphology for gestation appears normal.

- Cranial ossification appears normal. Midline falx is seen. Choroid plexuses are seen filling the lateral ventricles. No posterior fossa mass seen. Spine is seen as two lines. Overlying skin appears intact.
- Both orbits & lens seen. No intrathoracic mass seen. 4 chamber heart seen . No TR . .
- Stomach bubble is seen. Bilateral renal shadows is seen. Anterior abdominal wall appears intact.
- Urinary bladder is seen, appears normal. 3 vessel cord is seen.
- All four limbs with movement are seen. Nasal bone well seen & appears normal. Nuchal translucency measures 2.0 mm ( WNL ).
- Ductus venosus shows normal flow & spectrum with positive "a" wave ( PI ~ 1.28 )

### FETAL GROWTH PARAMETERS

▪ CRL 66.4 mm ~ 13 wks 0 days of gestation.

- Estimated gestational age is 13 weeks 0 days (+/- 1 week). EDD by USG : 27.12.2024
- Internal os closed. Cervical length is WNL (36.6 mm ).
- Baseline screening of both uterine arteries was done with mean PI ~ 1.34 ( WNL for gestation ).

### IMPRESSION:

- ↓ Single, live, intrauterine fetus of 13 weeks 0 days +/- 1 week.
- ↓ Gross fetal morphology is within normal limits.
- ↓ Low lying placenta with lower edge just reaching upto internal os .Mild retroplacental hemorrhage.

Follow up at 19-22 weeks for target scan for detailed fetal anomaly screening.

Declaration : I have neither detected nor disclosed the sex of the fetus to pregnant woman or to anybody. (It must be noted that detailed fetal anatomy may not always be visible due to technical difficulties related to fetal position, amniotic fluid volume, fetal movements, maternal abdominal wall thickness & tissue ecogenicity. Therefore all fetal anomalies may not be detected at every examination. Patient has been counselled about the capabilities & limitations of this examination. )

( DR. ANKITA VIJAYVARGIYA )

Singh Prinshu

Date of birth : 12 September 1993, Examination date: 21 June 2024

Address:

hno. 41, view hills kolar road  
Bhopal  
INDIA

Referring doctor: DR. (MS) POOJA SHRIVASTAVA

**Maternal / Pregnancy Characteristics:**

Previous chromosomally abnormal child or fetus: first trimester miscarriage .  
Racial origin: South Asian (Indian, Pakistani, Bangladeshi).

Parity: 0.  
Maternal weight: 74.0 kg; Height: 162.6 cm.

Smoking in this pregnancy: no; Diabetes Mellitus: no; Chronic hypertension: no; Systemic lupus erythematosus: dont know; Antiphospholipid syndrome: dont know; Patient's mother had preeclampsia: no.

Method of conception: Spontaneous;  
Last period: 20 March 2024

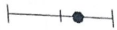


EDD by dates: 25 December 2024

**First Trimester Ultrasound:**

US machine: logiq f6. Visualisation: good.

Gestational age: **13 weeks + 2 days** from dates

EDD by scan: 25 December 2024

Findings	Alive fetus
Fetal heart activity	visualised
Fetal heart rate	164 bpm 
Crown-rump length (CRL)	66.4 mm 
Nuchal translucency (NT)	2.0 mm
Ductus Venosus PI	1.280 
Placenta	left postero lateral ,low
Amniotic fluid	normal
Cord	3 vessels

**Chromosomal markers:**

Nasal bone: present; Tricuspid Doppler: normal.

**Fetal anatomy:**

Skull/brain: appears normal; Spine: appears normal; Heart: 4 chamber & 3vessel trachea view grossly unremarkable; Abdominal wall: appears normal; Stomach: visible; Bladder / Kidneys: visible; Hands: both visible; Feet: both visible.

Uterine artery PI:	1.34	equivalent to 0.860 MoM
Mean Arterial Pressure:	75.2 mmHg	equivalent to 0.870 MoM
Endocervical length:	36.6 mm	

**Risks / Counselling:**

Patient counselled and consent given.

Operator: DR. ANKITA VIJAYVARGIYA, FMF Id: 204664

Condition  
Trisomy 21  
Trisomy 18

Background risk  
1: 593  
1: 1466

Adjusted risk  
1: 11459  
1: 8572