

# डॉ. अंकिता विजयवर्गीय

एम. बी. बी. एस., डी. एम. आर डी  
एम. आर आई. फेलोशिप :  
नानावती हॉस्पिटल, मुंबई  
हिंदुजा हॉस्पिटल, मुंबई  
सर्व रेडियोलॉजिस्ट :  
फोर्टिस हॉस्पिटल, नोएडा  
ग्रे. टी. बी. हॉस्पिटल, दिल्ली  
जेसी हॉस्पिटल लिमिटेड, कानपुर  
जावाहर लाल नेहरू कैंसर हॉस्पिटल, भोपाल

## DR. ANKITA VIJAYVARGIYA

MBBS, DMRD  
FMF Certified from  
Fetal Medicine Foundation  
Reg. No. MP-8932

MRI FELLOWSHIPS :  
• NANA VATI HOSPITAL, MUMBAI  
• HINDUJA HOSPITAL, MUMBAI  
FORMER RADIOLOGIST AT:  
• FORTIS HOSPITAL, NOIDA  
• G.T.B HOSPITAL, DELHI  
• REGENCY HOSPITAL LTD, KANPUR  
• JAWAHAR LAL NEHRU CANCER HOSPITAL, BHOPAL

PATIENT'S NAME: MRS. SHWETA

AGE/SEX : 33Y/F

REF. BY : DR. PUJA SINGH ( MBBS, DGO)

DATE : 24.07.2024

### OBSTETRIC USG ( EARLY ANOMALY SCAN )

LMP: 24.04.2024

GA(LMP):13wk 0d

EDD : 29.01.2025

- Single live fetus seen in the intrauterine cavity in variable presentation.
- Spontaneous fetal movements are seen. Fetal cardiac activity is regular and normal & is 161 beats /min.
- PLACENTA: is grade I, anterior & not low lying.
- LIQUOR: is adequate for the period of gestation.

#### Fetal morphology for gestation appears normal.

- Cranial ossification appears normal. Midline falx is seen. Choroid plexuses are seen filling the lateral ventricles. No posterior fossa mass seen. Spine is seen as two lines. Overlying skin appears intact.
- No intrathoracic mass seen. No TR .
- Stomach bubble is seen. Bilateral renal shadows is seen. Anterior abdominal wall appears intact.
- Urinary bladder is seen, appears normal. 3 vessel cord is seen.
- All four limbs with movement are seen. Nasal bone well seen & appears normal. Nuchal translucency measures 1.2 mm ( WNL ).
- Ductus venosus shows normal flow & spectrum with positive "a" wave ( PI ~ 1.08 )

#### FETAL GROWTH PARAMETERS

▪ CRL 70.9 mm ~ 13 wks 2 days of gestation.

- Estimated gestational age is 13 weeks 2 days (+/- 1 week). EDD by USG : 27.01.2025
- Internal os closed. Cervical length is WNL ( 31.8 mm ).
- Baseline screening of both uterine arteries was done with mean PI ~ 2.28 ( WNL for gestation ).
- Date of last delivery 02.12.2019 .
- Gestation at delivery of last pregnancy 40 weeks 4 days.

#### IMPRESSION:

- ↓ Single, live, intrauterine fetus of 13 weeks, 2 days +/- 1 week.
- ↓ Gross fetal morphology is within normal limits.

Follow up at 19-22 weeks for target scan for detailed fetal anomaly screening.

Declaration : I have neither detected nor disclosed the sex of the fetus to pregnant woman or to anybody. (It must be noted that detailed fetal anatomy may not always be visible due to technical difficulties related to fetal position, amniotic fluid volume, fetal movements, maternal abdominal wall thickness & tissue ecogenicity. Therefore all fetal anomalies may not be detected at every examination. Patient has been counselled about the capabilities & limitations of this examination. )

( DR. ANKITA VIJAYVARGIYA )



# First Trimester Screening Report

Mishra Shweta

Date of birth : 16 October 1991, Examination date: 24 July 2024

Address: hno. f-4 / 169, madan  
apartment a sector  
sarvdharm colony kolar road  
Bhopal  
INDIA

Referring doctor: Dr. PUJA SINGH (MBBS , DGO)

## Maternal / Pregnancy Characteristics:

Previous chromosomally abnormal child or fetus: first trimester miscarriage .

Racial origin: South Asian (Indian, Pakistani, Bangladeshi).

Parity: 1; Deliveries at or after 37 weeks: 1.

Maternal weight: 55.0 kg; Height: 165.1 cm.

Smoking in this pregnancy: no; Diabetes Mellitus: no; Chronic hypertension: no; Systemic lupus erythematosus: dont know; Antiphospholipid syndrome: dont know; Preeclampsia in previous pregnancy: no; Previous small baby: no; Patient's mother had preeclampsia: no.

Method of conception: Spontaneous;

Last period: 24 April 2024

EDD by dates: 29 January 2025

## First Trimester Ultrasound:

US machine: logiq f6. Visualisation: good.

Gestational age: 13 weeks + 0 days from dates

EDD by scan: 29 January 2025

Findings	Alive fetus
Fetal heart activity	visualised
Fetal heart rate	161 bpm
Crown-rump length (CRL)	70.9 mm
Nuchal translucency (NT)	1.2 mm
Ductus Venosus PI	1.080
Placenta	anterior high
Amniotic fluid	normal
Cord	3 vessels

## Chromosomal markers:

Nasal bone: present; Tricuspid Doppler: normal.

## Fetal anatomy:

Skull/brain: appears normal; Spine: appears normal; Heart: No TR.; Abdominal wall: appears normal; Stomach: visible; Bladder / Kidneys: visible; Hands: both visible; Feet: both visible.

Uterine artery PI:	2.28	equivalent to 1.450 MoM
Mean Arterial Pressure:	82.0 mmHg	equivalent to 1.000 MoM
Endocervical length:	31.8 mm	

## Risks / Counselling:

Patient counselled and consent given.

Operator: DR. ANKITA VIJAYVARGIYA, FMF Id: 204664

Condition	Background risk	Adjusted risk
Trisomy 21	1: 436	1: 8727
Trisomy 18	1: 1101	1: 6061





# First Trimester Screening Report

Trisomy 13

1: 3443

<1: 20000

Preeclampsia before 34 weeks

1: 1088

Fetal growth restriction before 37 weeks

1: 154

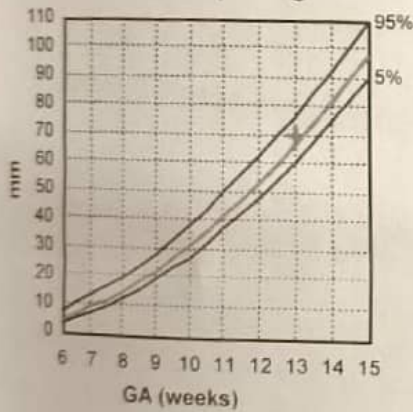
The background risk for aneuploidies is based on maternal age (32 years). The adjusted risk is the risk at the time of screening, calculated on the basis of the background risk and ultrasound factors (fetal nuchal translucency thickness, nasal bone, tricuspid Doppler, fetal heart rate).

Risks for preeclampsia and fetal growth restriction are based on maternal demographic characteristics, medical and obstetric history, uterine artery Doppler and mean arterial pressure (MAP).

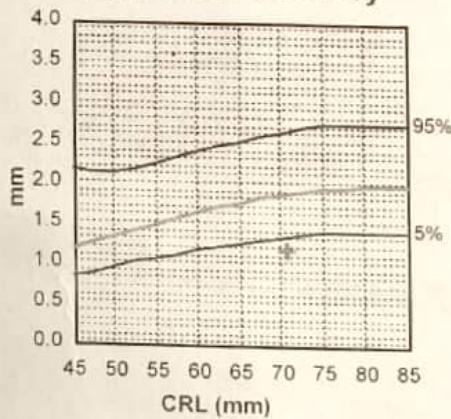
All biophysical markers are corrected as necessary according to several maternal characteristics including racial origin, weight, height, smoking, method of conception and parity.

The estimated risk is calculated by the FMF-2012 software (version 2.81) and is based on findings from extensive research coordinated by the Fetal Medicine Foundation (UK Registered charity 1037116). The risk is only valid if the ultrasound scan was performed by a sonographer who has been accredited by the Fetal Medicine Foundation and has submitted results for regular audit (see [www.fetalmedicine.com](http://www.fetalmedicine.com)).

**Crown-rump length**



**Nuchal translucency**



**1st trimester risk of Trisomy 21**

