

ASHAVI CLINIC



Dr. Prerna Thapa
MBBS, CGO, DMCH
Fellowship in OBS/Gynae
Medical Officer
Indian Red Cross Society
Bhopal

Clinic :
Shop No. 5, Fortune Estate
Kolar Road, Bhopal (M.P.)
Mob.: 9425012122
Timing : 7 pm - 9:30 pm
(Sunday Closed)

R

Mrs Sindhu
37 yr
Grimmi

Date 10/8/24

24/12/15

Am
2nd 28
D/Aet
12-14w/14
Ballot

24
cut 604
Bif 10472

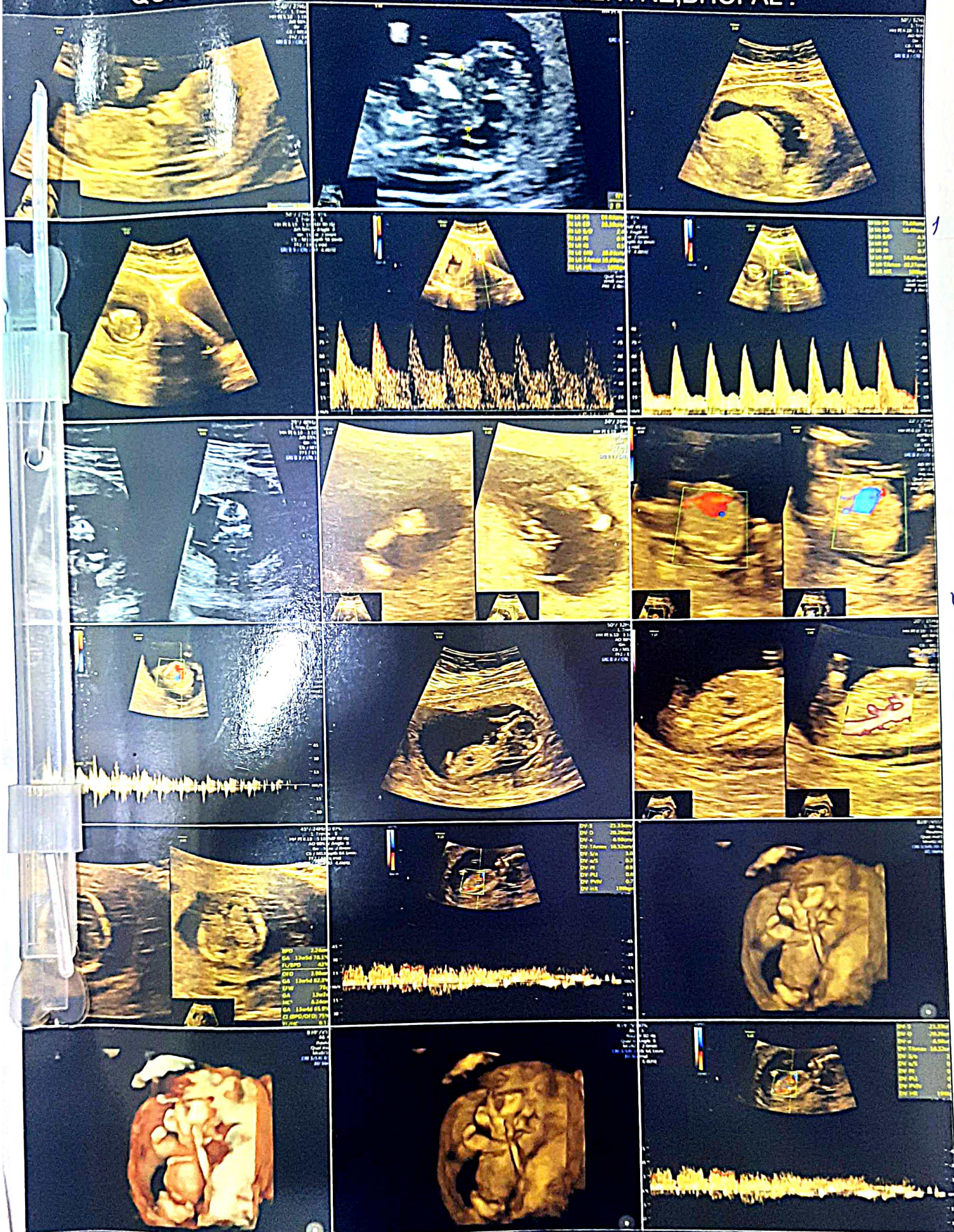
2ab Alisfer 87 410dy

2ab Q Calcium 410dy

2ab

Asl
Doubly
Marker

QURA DIAGNOSTICS & RESEARCH CENTRE, BHOPAL.



SINDHU NAIL/24004292/09-Aug-2024



RA DIAGNOSTICS
D RESEARCH CENTRE

✉ info@quradiagnostics.com
🌐 quradiagnostics.com
☎ 0755-4927222, +91 7477228888

📍 Plot No-4,
Chuna Bhatti Kolar Road,
Bhopal - 462016

Patient name	Mrs. SINDHU NAIL	Age/Sex	37 Years / Female
Patient ID	24004292	Visit no	1
Referred by	Dr. PRERNA THAPPA	Visit date	09/08/2024
LMP date	12/05/2024	LMP EDD	16/02/2025

OB - First Trimester Scan Report

Indication(s)

FOR NT/NB SCAN

Real time B-mode ultrasonography of gravid uterus done.

Route: Transabdominal

Single intrauterine gestation

Maternal

Cervix measured 4.20 cm in length.

Right Uterine	0.99	●— — (4%)
Left Uterine	1.7	—●— (55%)
Mean PI	1.345	—●— (28%)

Fetus

Survey

Placenta - Posterior and circumvallate

Liquor - Normal

Fetal activity present

Cardiac activity present

Fetal heart rate - 163 bpm

Biometry(Hadlock)

BPD 22 mm 13W 2D (69%ile)	HC 82 mm 13W (61%ile)	AC 52 mm 12W 3D (43%ile)	FL 10 mm 12W 5D (51%ile)
5% 50% 95%	5% 50% 95%	5% 50% 95%	5% 50% 95%

CRL - 69 mm(13W)

BSOB ratio - 0.25 mm

aneuploidy Markers

Nasal Bone : 3.3 mm - Ossified

Nuchal translucency : 3.4 mm Increased nuchal translucency, above 99th centile.

Ductus venosus : No "a" wave reversal.

Tricuspid regurgitation : No tricuspid regurgitation noted.

Fetal Anatomy

Midline falx seen.

Both lateral ventricles appeared normal.

Posterior fossa appeared normal.

No identifiable intracranial lesion seen.

Aqueduct of sylvius is visualised and appears normal.

AOS-to-occiput distance is 2.9mm and within normal limits.

Fetal neck appeared normal.

Spine appeared normal. No evidence of significant open neural tube defect



Page #1 - 09/08/24 02:35 PM

EMERGING DIAGNOSTIC CENTRE OF MADHYA PRADESH
FMPCCI - 5th OUTSTANDING ACHIEVEMENT AWARD 2017-18

BEST DIAGNOSTIC & IMAGING CENTRE IN MADHYA PRADESH
WORLDWIDE ACHIEVERS INTERNATIONAL HEALTHCARE SUMMIT & AWARDS, 2017



QURA DIAGNOSTICS
AND RESEARCH CENTRE

✉ info@quradiagnostics.com
🌐 quradiagnostics.com
☎ 0755-4927222, +91 7477228888

📍 Plot No-4,
Chuna Bhatti Kolar Road,
Bhopal - 462016

Patient name	Mrs. SINDHU NAIL	Age/Sex	37 Years / Female
Patient ID	24004292	Visit no	1
Referred by	Dr. PRERNA THAPPA	Visit date	09/08/2024
LMP date	12/05/2024	LMP EDD	16/02/2025

Fetal face seen in the coronal and profile views.
Both orbits, nose and mouth appeared normal
Premaxillary triangle is visualised and appears normal.
Both lungs seen.
No evidence of pleural or pericardial effusion.
No evidence of SOL in the thorax.
Heart appears normal.
Outflow tracts appeared normal.
Abdominal situs appeared normal.
Stomach, small bowel are visualised and appears normal.
Both kidneys and bladder appeared normal.
All long bones appeared normal for the period of gestation
Fetal doppler

Ductus Venosus PI 0.67  (21%)

Impression

Intrauterine gestation corresponding to a gestational age of **12 Weeks 5 Days**
Gestational age assigned as per LMP
Placenta - Posterior and circumvallate
Liquor - Normal

Advise:

- doublemarker /CVS** in view of more than 99th centile NT
- Invasive testing** should be recommended with QFPCR AND RASO panel in view of NT above 3mm
- Genetic counselling should be recommended



DR. SOMYA DWIVEDI

MBBS, M.D. RADIODIAGNOSIS

Fellow in Fetal Imaging

I.O.T.A Certified for Women Imaging

FMF-UK Certified for NT scan, Pre-Eclampsia screening, Fetal abnormalities & Fetal Echo

Advanced course I.S.U.O.G. for obstetric imaging

Reg. No.: MP-14794

First trimester screening for Downs

Maternal age risk 1 in 210

Fetus	Risk estimate - NT	Risk estimate - NT + NB	Markers name
A	1 in 25	1 in 83	Nasal Bone Present

Disclaimer

DR SOMYA DWIVEDI, DECLARE THAT WHILE CONDUCTING USG ON MRS. SINDHU NAIL, I HAVE NEITHER DETECTED NOR DISCLOSED THE SEX OF HER FETUS TO ANYONE IN ANY MANNER. This is not anomaly /Fetal Echo and is only a professional opinion and not final diagnosis. It should be clinically interpreted by clinician. The report is not valid for medicolegal purposes. In case of typing error inform signing authority.
I AM A GIRL CHILD.

EMERGING DIAGNOSTIC CENTRE OF MADHYA PRADESH
FMPCCI - 5th OUTSTANDING ACHIEVEMENT AWARD 2017-18

Page #2 - 09/08/24 02:35 PM

BEST DIAGNOSTIC & IMAGING CENTRE IN MADHYA PRADESH
WORLDWIDE ACHIEVERS INTERNATIONAL HEALTHCARE SUMMIT & AWARDS, 2017

Double Markon

LMP- 12-5-27

Date 24-9-1987

High - 4.3

Weight - 60 kg.