



DR. RAHUL KATARIYA
MBBS DMRE
Consultant Radiologist
Foetal Medicine Foundation UK Certified



SONOGRAPHY | DIGITAL X-RAY | COLOUR DOPPLER

Patient Name : MRS. BHAGYASHRI SHRIKRUSHNA JADHAV Date : 10 Sep 2024
Referred By : DR. TANUJA JOSHI
Age : 30 YEARS Sex : F

USG OBSTETRICS: ANOMALY SCAN

A single live foetus is seen in variable lie.
Heart activity and foetal movements are normal. FHR-157/Min.
Placenta is anterior. There is no placenta praevia.
There is no evidence of any obvious congenital anomaly noted on present examination in present foetal position.
Liquor is adequate.
Internal os is closed. Cervix measures 35.22 mm.

HEAD

Lateral ventricles normal atrium 6 mm.
Cerebellum normal.
Cisterna magna normal.
No identifiable intra-cranial lesion.

NECK:

No cystic structure seen around neck.

SPINE:

Entire spine visualized in long and transverse axis.
Vertebrae and spinal canal appears normal.
No evidence of neural tube defect or protrusion.

FACE:

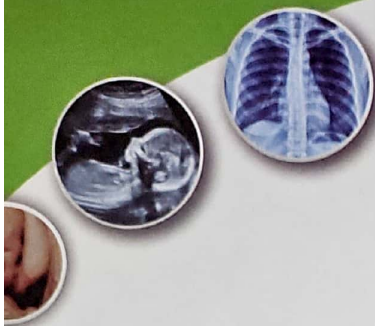Face seen in coronal and profile view.
Both orbits, nose and mouth appears normal.
No evidence of facial cleft.

THORAX:

Heart appears in the mid position with apex to left.
Normal cardiac situs.
Four chambers view normal.
Outflow tracts normal.
Both lungs seen.
No evidence of pleural or peri-cardial effusion.
No evidence of SOL in thorax.

Plot No. 1218/1, Talawade Road, Near ATM Corner, Triveni nagar, Pune - 412114
7249343400 Monday - Saturday 9 am - 2 pm & 5 pm to 8 pm | Sunday 9 am - 11 am
(Sunday by Appointment)





DR. RAHUL KATARIYA
MBBS DMRE
Consultant Radiologist
Foetal Medicine Foundation UK Certified



SONOGRAPHY | DIGITAL X-RAY | COLOUR DOPPLER

ABDOMEN:

Abdomen situs appears normal.

Stomach and bowel normal.

Normal bowel pattern appearance for gestational age.

No evidence of ascites. Abdominal wall intact. Diaphragm normal. No CDH.

KUB:

Both the kidneys and bladder normal.

A three vessel umbilical cord is seen-two arteries and one vein noted.

LIMBS:

All foetal long bones visualized and appear normal for period of gestation.

Both hands and feet normal.

Vessel	P.I.	Percentile
Rt Uterine artery	0.42	<1
Lt uterine artery	0.68	

GROWTH PARAMETERS:

Parameter	Measurement	Gestational age	Percentile
Biparietal diameter	38.99 mm	17w6d	61.1 Percent
Head circumference	146.92 mm	17w6d	25.6 Percent
Abdominal circumference	128.26 mm	18w3d	42 Percent
Femur length	24.78 mm	17w3d	44 Percent
Humerus length	26.92 mm	18w4d	33.7 Percent
Average maturity	18w0d		
Estimated foetal weight	217 g		

IMPRESSION.

Single live foetus in variable lie, of average maturity of 18w0d


A follow-up is advised after 6 wks.

EDD assigned as per dating scan: 11/02/2025

Last menstrual period: 07/05/2024

Expected gestational age: 18w0d

This is to certify that I have neither detected nor disclosed the sex of the foetus to anybody.


DR. RAHUL KATARIYA
(Consultant Radiologist)

Plot No. 1218/1, Talawade Road, Near ATM Corner, Triveni nagar, Pune - 412114

☎ 7249343400 Monday - Saturday 9 am - 2 pm & 5 pm to 8 pm | Sunday 9 am - 11 am
(Sunday by Appointment)



Scanned with OKEN Scanner